

VOL.12 NO.6 JUNE 2007

# 香港醫訊

THE HONG KONG

# MEDICAL DIARY



OFFICIAL PUBLICATION FOR THE FEDERATION OF MEDICAL SOCIETIES OF HONG KONG

[www.fmshk.org](http://www.fmshk.org)

## Editorial

- Robotic Surgery System - Is it a "White Elephant" ?

*Dr. Angus CW Chan  
Dr. Samuel PY Kwok*

## Medical Bulletin

- The Use of Robotic in Gynaecology
- A Brief Update on Laparoscopic Assisted Colectomy
- The Use of Robot in Urology **CME**
- Local Experience of Laparoscopic Pancreatectomy
- The Use of Robotic in GI Surgery
- Pearls and Pitfalls in Laparoscopic Hysterectomy

*Dr. Pong-mo Yuen*

*Dr. C C Chung*

*Dr. Wai-sang Wong*

*Dr. Chung-ngai Tang*

*Dr. Wing-tai Siu*

*Dr. Choi-man Yan*

## Lifestyle

- Lifestyle

*Dr. Antonio AT Chuh*

## Dermatological Quiz

- Dermatological Quiz

*Dr. Lai-yin Chong*

- Society News

- Medical Diary of June

- Calendar of Events

ISSN 1812 - 1691

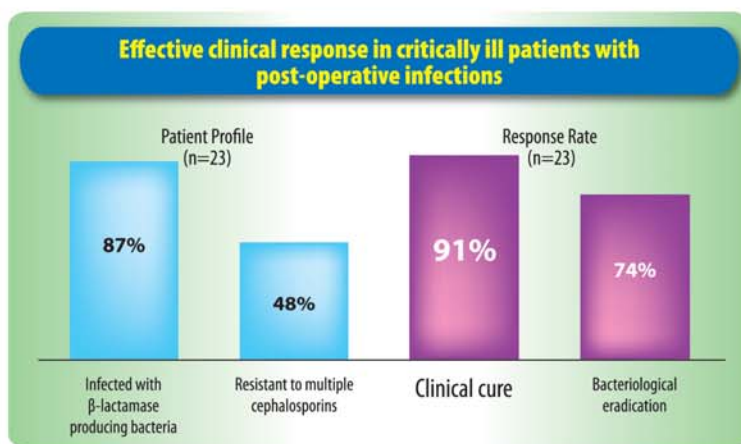
醫聯成員一家親 · 市民健康齊關心

# Sulperazon\*

sublactam/cefoperazone IM/IV

**Your Smart Choice for Post-operative Infection**

- Smart!** 3<sup>rd</sup> Generation Cephalosporin with a Beta-Lactamase Inhibitor
- Smart!** Broad Spectrum of activity against infections involving aerobes and anaerobes<sup>1</sup>
- Smart!** Good for first-line empirical IV treatment<sup>1</sup>



## Dosage of Sulperazon

| Usual Adult Daily Dosage  |   |
|---|---|
| <b>1g-2g Q12h IM or IV</b>  | Maximum dosage: up to 4g Q12h   |
| Dosage in Renal Impairment  |   |
| Creatinine clearance<br>15-30mL/min<br>(maximum recommended dosage is 2g Q12h)                    | <15mL/min<br>(maximum recommended dosage is 1g Q12h)  |
| Dosage for Most Pediatric Patients*   |   |
| Usual dosage of Sulperazon* is 40-80mg/kg/day, administered every 6-12h in equally divided doses. | In serious or refractory infections, dosage may be increased up to 160mg/kg/day, administered every 6-12h in equally divided doses. |

† The recommended maximum daily dosage of sublactam is 4g.

\* See prescribing information for important additional information on dosage in neonates.

Detailed prescribing information is available upon request.

### References:

- Lee N et al. Clinical Role of  $\beta$ -Lactam/ $\beta$ -Lactamase Inhibitor Combinations. *Drugs* 2003; 63 (14): 1511-1524.
- Engin A et al. Clinical experience with sublactam/cefoperazone in critical surgical infections. *Curr Ther Res. Clin Exp* 1991; 49:989 - 997.



Pfizer Corporation Hong Kong Limited

16/F., Stanhope House, 738 King's Road, North Point, Hong Kong  
Tel: (852) 2811 9711 Fax: (852) 2579 0599  
Website: www.pfizer.com.hk



### The Federation of Medical Societies of Hong Kong

4/F Duke of Windsor Social Service Building,  
15 Hennessy Road, Wanchai, Hong Kong  
Tel: 2527 8898 Fax: 2865 0345

|                                    |                              |       |
|------------------------------------|------------------------------|-------|
| <b>President</b>                   | Dr. FONG To-sang, Dawson     | 方道生醫生 |
| <b>1st Vice- President</b>         | Dr. CHAN Chi-kuen            | 陳志權醫生 |
| <b>2nd Vice- President</b>         | Dr. LO Sze-ching, Susanna    | 盧時楨醫生 |
| <b>Hon. Secretary</b>              | Dr. LO See-kit, Raymond      | 勞思傑醫生 |
| <b>Deputy Hon. Secretary</b>       | Dr. CHAN Sai-kwing           | 陳世炯醫生 |
| <b>Hon. Treasurer</b>              | Mr. LAM Lop-chi, Nelson      | 林立志先生 |
| <b>Deputy Hon. Treasurer</b>       | Mr. LEE Cheung-mei, Benjamin | 李祥美先生 |
| <b>Executive Committee Members</b> |                              |       |
|                                    | Dr. CHAN Chi-fung, Godfrey   | 陳志峰醫生 |
|                                    | Dr. CHIM Chor-sang, James    | 詹楚生醫生 |
|                                    | Dr. HO Chung-ping            | 何仲平醫生 |
|                                    | Dr. HUNG Kwan-ngai           | 洪君毅醫生 |
|                                    | Dr. KING Wing-keung, Walter  | 金永強醫生 |
|                                    | Dr. LEE Man-piu, Albert      | 李文彪醫生 |
|                                    | Dr. LI Fuk-him, Dominic      | 李福謙醫生 |
|                                    | Ms. MAN Bo-lin, Manbo        | 文保蓮女士 |
|                                    | Dr. MAN Chi-wai              | 文志衛醫生 |
|                                    | Dr. MOK Chun-on              | 莫鎮安醫生 |
|                                    | Mr. TO Yuen-yuk, Peter       | 杜元郁先生 |
| <b>Executive Manager</b>           | Ms. CHENG Shu-yue, Sue       | 鄭淑儀小姐 |

### FOUNDER MEMBERS

#### The Hong Kong Medical Association 香港醫學會

|                         |   |        |
|-------------------------|---|--------|
| <b>President</b>        | Dr. CHOI Kin  | 蔡 堅醫生  |
| <b>Vice- Presidents</b> | Dr. CHU Kin-wah   | 朱建華醫生  |
|                         | Dr. SHIH Tai-cho  | 史泰祖醫生  |
| <b>Hon. Secretary</b>   | Dr. LEUNG Chi-chiu                                      | 梁子超醫生  |
| <b>Hon. Treasurer</b>   | Dr. CHOW Pak-Chin                                       | 周伯展醫生  |
| <b>Council Rep.</b>     | Dr. CHAN Yee-shing                                      | 陳以誠醫生  |
|                         | Dr. HO Chung-ping                                       | 何仲平醫生  |
| <b>Chief Executive</b>  | Mrs. Yvonne LEUNG                                       | 梁周月美女士 |
|                         | Tel: 2527 8285 (General Office)                         |        |
|                         | 2527 8324 / 2536 9388 (Club House in Wanchai / Central) |        |
|                         | Fax: 2865 0943 (Wanchai), 2536 9398 (Central)           |        |
|                         | Email: hkma@hkma.org                                    |        |
|                         | Website: http://www.hkma.org                            |        |

#### British Medical Association (Hong Kong Branch) 英國醫學會 (香港分會)

|                       |                               |       |
|-----------------------|-------------------------------|-------|
| <b>President</b>      | Dr. Jason BROCKWELL           |       |
| <b>Vice-President</b> | Prof. David ANDERSON          |       |
| <b>Hon. Secretary</b> | Dr. LO See-kit, Raymond       | 勞思傑醫生 |
| <b>Hon. Treasurer</b> | Dr. Alex YIP                  |       |
| <b>Council Rep.</b>   | Dr. Jason BROCKWELL           |       |
|                       | Dr. CHEUNG Tse-ming           | 張子明醫生 |
|                       | Tel: 2527 8898 Fax: 2865 0345 |       |

#### The HKFMS Foundation Limited 香港醫學組織聯會基金

|                            |                             |       |
|----------------------------|-----------------------------|-------|
| <b>Board of Directors</b>  |                             |       |
| <b>President</b>           | Dr. FONG To-sang, Dawson    | 方道生醫生 |
| <b>1st Vice- President</b> | Dr. CHAN Chi-kuen           | 陳志權醫生 |
| <b>2nd Vice- President</b> | Dr. LO Sze-ching, Susanna   | 盧時楨醫生 |
| <b>Hon. Secretary</b>      | Dr. LO See-kit, Raymond     | 勞思傑醫生 |
| <b>Hon. Treasurer</b>      | Mr. LAM Lop-chi, Nelson     | 林立志先生 |
| <b>Directors</b>           |                             |       |
|                            | Dr. CHIM Chor-sang, James   | 詹楚生醫生 |
|                            | Dr. KING Wing-keung, Walter | 金永強醫生 |
|                            | Dr. LI Fuk-him, Dominic     | 李福謙醫生 |
|                            | Mr. CHAN Yan-chi, Samuel    | 陳恩賜先生 |
|                            | Ms. MAN Bo-lin, Manbo       | 文保蓮女士 |

## Contents

### Editorial

- **Robotic Surgery System - Is it a "White Elephant" ?** 2  
*Dr. Angus CW Chan*  
*Dr. Samuel PY Kwok*

### Medical Bulletin

- **The Use of Robotic in Gynaecology** 3  
*Dr. Pong-mo Yuen*
- **A Brief Update on Laparoscopic Assisted Colectomy** 7  
*Dr. C C Chung*
- **The Use of Robot in Urology** **CME** 10  
*Dr. Wai-sang Wong*
- **MCHK CME Programme Self-assessment Questions** 12
- **Local Experience of Laparoscopic Pancreatotomy** 15  
*Dr. Chung-ngai Tang*
- **The Use of Robotic in GI Surgery** 23  
*Dr. Wing-tai Siu*
- **Pearls and Pitfalls in Laparoscopic Hysterectomy** 26  
*Dr. Choi-man Yan*

### Lifestyle

- **Lifestyle** 29  
*Dr. Antonio AT Chuh*

### Dermatological Quiz

- **Dermatological Quiz** 30  
*Dr. Lai-yin Chong*

### Society News

- **News from Member Societies** 31

### Medical Diary of June

### Calendar of Events

- **Meetings** 34
- **Courses** 34



Published by  
The Federation of Medical Societies of Hong Kong

**EDITOR-IN-CHIEF**

Dr. KING Wing-keung, Walter 金永強醫生

**EDITORS**

Dr. CHAN Chi-fung, Godfrey  
陳志峰 醫生 (Paediatrics)

Dr. CHAN Chun-hon, Edmond  
陳振漢 醫生 (General Practice)

Dr. MOK Chun-on  
莫鎮安 醫生 (Plastic Surgery)

**EDITORIAL BOARD**

Dr. AU-YEUNG Cheuk-lun, Henry  
區陽卓倫 醫生 (Paediatrics)

Dr. CHAN Chi-wai, Angus  
陳志偉 醫生 (General Surgery)

Dr. Norman CHAN  
陳諾 醫生 (Diabetes, Endocrinology & Metabolism)

Dr. CHIANG Chung-seung  
蔣忠想 醫生 (Cardiology)

Dr. CHONG Lai-yin  
莊禮賢 醫生 (Dermatology & Venereology)

Dr. CHUH An-tung, Antonio  
許晏冬 醫生 (Family Medicine)

Dr. FAN Yiu-wah  
范耀華 醫生 (Neurosurgery)

Dr. FONG Ka-yeung  
方嘉揚 醫生 (Neurology)

Dr. FUNG Ho-chuen, Alec  
馮浩泉 醫生 (Dermatology & Venereology)

Dr. FUNG Yee-pong, Adrian  
馮貽邦 醫生 (Dermatology & Venereology)

Dr. HO Pak-leung  
何栢良 醫生 (Clinical Microbiology and Infections)

Dr. KWOK Kwan-ho, Alvin  
郭坤豪 醫生 (Ophthalmology)

Dr. KWOK Po-yin, Samuel  
郭寶賢 醫生 (General Surgery)

Dr. LAI Cheuk Seen, Edward  
黎卓先 醫生 (General Surgery)

Dr. LAI Kei-wai, Christopher  
賴奇偉 醫生 (Respiratory Medicine)

Dr. LAI Sik-to, Thomas  
黎錫滔 醫生 (Gastroenterology & Hepatology)

Dr. LAM Tat-chung, Paul  
林達聰 醫生 (Psychiatry)

Dr. LAM Wai-man, Wendy  
林慧文 醫生 (Radiology)

Dr. LAO Tzu-his, Terence  
勞子偉 醫生 (Obstetrics & Gynaecology)

Dr. LEE Man-piu, Albert  
李文彪 醫生 (Dentistry)

Dr. LEUNG Wai-tong, Thomas  
梁惠棠 醫生 (Clinical Oncology)

Dr. LO See-kit, Raymond  
勞思傑 醫生 (Geriatrics)

Dr. MAN Chi-wai  
文志衛 醫生 (Urology)

Dr. MOK Mo-yin  
莫慕賢 醫生 (Rheumatology)

Dr. MONG Hoi-Keung  
蒙海強 醫生 (Forensic Pathology)

Dr. TEO Man-lung, Peter  
張文龍 醫生 (Clinical Oncology)

Dr. TSANG Wai-kay  
曾偉基 醫生 (Nephrology)

Dr. TSE Tak-fu  
謝德富 醫生 (Cardiology)

Prof. William I WEI  
韋霖 教授 (Otorhinolaryngology)

Dr. WONG Bun-lap, Bernard  
黃品立 醫生 (Cardiology)

Dr. WU Wing-cheung, Stephen  
胡永祥 醫生 (Orthopaedics & Traumatology)

**EXECUTIVE MANAGER**

Ms. CHENG Shu-yue, Sue 鄭淑儀 小姐

## Robotic Surgery System - Is it a "White Elephant" ?

### Dr. Angus CW Chan

MBChB, MD, FCSHK,  
FHKAM (Surgery), FRCS (Edin)

### Dr. Samuel PY Kwok

MBBS, FCSHK, FHKAM (Surgery),  
FRCS (Edin), FRACS

Co-Editors



Dr. Angus CW Chan



Dr. Samuel PY Kwok

When the first laparoscopic cholecystectomy was successfully performed in 1987, a new era of surgery began and the surgical world was challenged with a new concept of modern surgery i.e. minimally invasive surgery. Twenty years down the road, laparoscopic surgery has almost replaced some of the traditional operations such as cholecystectomy, colectomy, adrenalectomy and hysterectomy. Laparoscopic surgery is now part of the standard practice in all fields of surgical subspecialties. Apart from our surgical endeavour, we must also compliment our industrial partners who act as the catalyst in accelerating the development of laparoscopic surgery. They produce new generations of equipment which allow keyhole surgeries to be performed in a much easier, safer and convenient way. As frontline users, we would say these new laparoscopic instruments are now essential tools in performing complex laparoscopic surgeries.

Nevertheless, the basic design of laparoscopic surgery is still confined to 2 - dimensional vision and 4 degrees of freedom that make complex laparoscopic procedures difficult even by experienced surgeons. Novice surgeons need large number of cases to surpass the learning curve. Robotic surgery is an emerging technology that has a high potential to change the surgical world. The newly designed robot system (da Vinci S Surgical System) was built to overcome some of the obstacles faced in 2-dimensional laparoscopic surgery and to facilitate fine dissection as in open surgery. It gives you 3-dimensional images and the instrument arms can articulate in 7 degrees of freedom as our human wrists. Intracorporeal suturing can be performed smoothly as our hands inside the abdomen. In this issue, the editorial board has invited different surgical experts to share with you the applications of this new Surgical Robot System in their own fields. However, this cutting edge technology is no longer a piece of instrument. It costs you 2.5 million US dollars and yet the proven applications are still evolving in various surgical fields. As driven by the marketing strategy and the media, the robot system is essential equipment for institution to be named on paper as the most advanced minimally invasive surgery centre. In practice, further research studies must be taken to evaluate and to uncover the potentials of robotic surgery.



## The Use of Robotic in Gynaecology

**Dr. Pong-mo Yuen**

MBChB (CUHK), FHKAM(O&G), FHKCOG (HK), FRCOG (UK)

*Director of Minimally Invasive Gynaecology, Hong Kong Sanatorium & Hospital*

*Honorary Clinical Associate Professor, Department of Obstetrics & Gynaecology, The Chinese University of Hong Kong*



Dr. Pong-mo Yuen

Gynaecologists were the first surgeons to use laparoscopy. Diagnostic laparoscopy and laparoscopic tubal ligation were commonly performed by gynaecologists since 1970s. In the last decade, operative laparoscopy has gained widespread acceptance. Almost all gynaecological procedures can now be performed by laparoscopy which has gradually become the standard of care. Today, most gynaecological centres are capable of performing basic laparoscopic procedures. However, relatively few gynaecologists possess the skills to perform more advanced laparoscopic procedures such as hysterectomy and myomectomy.

Laparoscopic surgery is performed using long instruments inserted into the abdomen through trocars and the image is viewed on the monitor. It avoids the morbidity of a large abdominal incision and shortens both the hospital stay and recovery period. However, there are inherent problems with this technique. Firstly, the two-dimensional image on the monitor results in the loss of depth perception and surgical precision. Secondly, the use of long instruments operating at a greater distance from the tissue magnifies hand tremor and further reduces operative precision. Thirdly, the limited degree of freedom of the instrument tips restricts the surgical angles in accessing the pathology and tissues planes. Fourthly, the inability to feel the organs directly reduces tactile feedback and increases the risk of inadvertent tissue trauma during manipulation. Lastly, the inferior ergonomic position adopted by the surgeon during surgery increases fatigue and discomfort, compromising performance and dexterity. These limitations make suturing and knot tying, the basic techniques in open surgery, very difficult and contribute to the steep learning curve often associated with complex laparoscopic procedures especially those requiring intra-abdominal suturing such as myomectomy and tubal re-anastomosis.

Robotic technology was introduced into surgical practice in an attempt to attenuate some of these limitations. Robotic instruments clearly provide superiority in some aspects of the surgery. The increased degrees of freedom ("wrist action") allow the surgeon to easily reach behind structures and negotiate difficult surgical angles. By adjusting movement scaling, hand tremor is significantly reduced, thereby increasing operative precision. The ergonomics of the operating surgeon is significantly improved by operating in the sitting position and facing directly forward toward the 3-D operative image. By using the robotic system, surgeons can now operate in an ergonomic position with restoration of proper hand-eye

coordination, improved quality of vision, enhanced dexterity with increased degrees of freedom. Surgical robot has the potential to enable a laparoscopic approach to procedures that are presently performed by laparotomy due to the technical difficulties intrinsic to laparoscopy.

The first commercial application of robotics in laparoscopic procedures was as a surgical assistant and functioned as a laparoscope holder. The device was called Automated Endoscopic System for Optimal Positioning or AESOP<sup>1</sup> (Computer Motion Inc., Goleta, CA). It provides a steady, hands-free image and the endoscope was moved using a foot pedal and later voice activation. Although the voice interface is appealing, it is still cumbersome. Robotic control of the laparoscope can allow both the surgeon and assistant to use both hands for a surgical procedure<sup>2</sup>. This is critical for complex gynaecological procedures.

The world's first robot assisted gynaecological surgical procedure reported was a case of tubal reanastomosis with the ZEUS Robotic System (Computer Motion, Goleta, CA, USA) in 1999<sup>3</sup>. The system has three remotely controlled robotic arms, allowing a single surgeon to manipulate the laparoscope and two laparoscopic surgical instruments simultaneously. The robotic arms are separated units also attached to the sides of the operating table. The arm that holds the laparoscope is AESOP which is directed by voice commands. The arms that hold the surgical instruments are controlled by two handles housed in a mobile console that can be positioned anywhere in the operating room or in a different location. A computer controller translates the surgeon's movements from the handles to the robotic arms.

The first robotic surgical system that integrates the control of both the laparoscope and surgical instruments into a single unit is the da Vinci Robotic Surgical System (Intuitive Surgical, Inc., Mountain View, CA, USA). In gynaecology, it was first reported to be used in laparoscopic tubal reanastomosis<sup>4</sup> and later laparoscopic hysterectomy<sup>5</sup>. The system is a computer-driven surgical tool with two major components: a mobile console and a surgical arm unit. The mobile console, which is operated by the surgeon with two handles and three foot pedals, controls the three, and in the latest model four, mobile arms of the robot, intra-abdominal manipulations, camera movements, and unipolar coagulation (Figure 1). The console can be positioned anywhere inside or outside the operating theatre. However, the Food and Drug administration



regulations require that the console be placed in the same room as the operative table except in telesurgery. The image is provided by the Insite Vision System through a 12 mm endoscope, with either zero- or 30-degree lenses, comprising of two laparoscopes fused together. The surgeon operates in a sitting position and looks through a binocular three-dimensional (3-D) viewing monitor (Figure 2). The image is displayed above the hands of the surgeon so that it gives the surgeon the illusion that the tips of the instruments are an extension of the control grips, thus giving the impression of being at the surgical site. The movements of the surgeon are digitalised, scaled at 1/1, 1/3, or 1/5, and transmitted by computer to the intraabdominal instruments without noticeable delay. The extraabdominal movements of the instruments controlled by the robotic arms have four degrees of freedom. The intraabdominal articulations of the micro-instruments at 2 cm from the tip are comparable to those of the human hand and wrist, with the same degrees of freedom.

Robotic surgery using the da Vinci Robotic Surgical System has been applied successfully in cardiac<sup>6</sup>, urologic<sup>7</sup>, paediatric<sup>8</sup>, foregut<sup>9</sup> and colo-rectal surgery<sup>10</sup>. In the literature to date, robotics has been reported to be used to perform different procedures: tubal reanastomosis<sup>4</sup>; hysterectomy<sup>5,11</sup>; ovarian transposition<sup>12</sup>; repair of vesicovaginal fistula<sup>13</sup>; sacrocolpopexy<sup>14,15</sup>. Currently, there are no published reports or series on robot-assisted myomectomy and radical hysterectomy with pelvic lymphadenectomy. However, several abstracts on these procedures have been presented at scientific meetings.

In Hong Kong, the first robot-assisted gynaecological surgery was performed by the author at the Prince of Wales Hospital in July 2006 (Figure 3). It was a total laparoscopic hysterectomy using the da Vinci Robotic Surgical System. Robot-assisted procedure is generally performed with the patient under general anaesthesia and in the dorsal lithotomy position, using four trocars. A 12-mm trocar is required for the laparoscope. It is placed either in the umbilicus or supraumbilical position depending on the size of the uterus. Two specially designed 8-mm trocars are placed in the right and left lower abdomen, 2-3 cm below and about 8 cm away from the primary trocar. These trocars are attached to the operating arms of the robot which is placed in between the patient's legs. A fourth trocar of 5 or 10 mm is placed somewhat midway between the primary port and one of the 8-mm ports, depending on the configuration of the operating theatre. This serves as an accessory port for suction and irrigation and suture to be brought into the pelvis.

Laparoscopic surgery has revolutionised the concept of minimally invasive surgery for the last 3 decades. Robotic-assisted surgery is one of the latest innovations in the field of minimally invasive surgery. However, robotic surgery is still in its infancy and its uses and efficacy have not yet been well established. The extremely high cost of the system and its instruments almost prohibits its widespread and routine use. The system is large in size and the robotic arms are relatively cumbersome. A large operating room is required to house both the surgical team and the robot.

There is no tactile or haptic feedback from the system and the surgeon has to rely on visual cues to assess the tensile strength of tissue and sutures. Despite these, robotic surgery has a shorter learning curve than conventional laparoscopy. It is envisaged that the surgical robots will make minimally invasive surgery easier and more efficient, and allow procedures that are performed by laparotomy to be accomplished by laparoscopy. Currently, the use of the robots may not be cost-effective for gynecologic procedures that are already performed by laparoscopy. Other potential problems such as malpractice liability, credentialing, and training requirements need to be addressed to ensure the safe introduction of robotic systems in surgery.



Figure 1. Surgeon operating the two handles in the main console which control the robotic arms of the da Vinci Surgical System

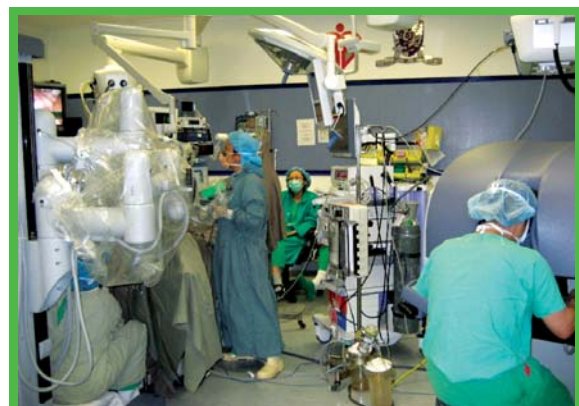

Figure 2. Surgeon operating remotely from the patient in an ergonomic and sitting position

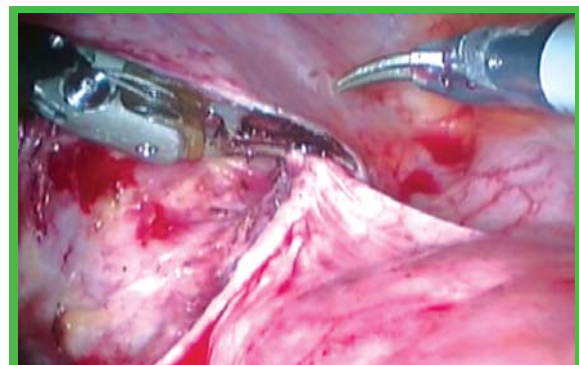


Figure 3. Robot-assisted laparoscopic hysterectomy



## References

- Unger SW, Unger HM, Bass RT. AESOP robotic arm. *Surg Endosc*. 1994; 8(9): 1131.
- Mettler L, Ibrahim M, Jonat W. One year of experience working with the aid of a robotic assistant (the voice-controlled optic holder AESOP) in gynaecological endoscopic surgery. *Hum Reprod*. 1998; 13(10): 2748-50.
- Falcone T, Goldberg J, Garcia-Ruiz A, Margossian H, Stevens L. Full robotic assistance for laparoscopic tubal anastomosis: a case report. *J Laparoendosc Adv Surg Tech A* 1999; 9: 107-13.
- Degueldre M, Vandromme J, Huong PT, Cadiere GB. Robotically assisted laparoscopy microsurgical tubal reanastomosis: a feasibility study. *Fertil Steril* 2000; 74: 1020-3.
- Diaz-Arrastia C, Jurnalov C, Gomez G, Townsend C. Laparoscopic hysterectomy using a computer-enhanced surgical robot. *Surg Endosc* 2002; 16: 1271-3.
- Boehm DH, Reichenspurner H, Detter C, Arnold M, Gulbins H, Meiser B, Reichart B. Clinical use of a computer-enhanced surgical robotic system for endoscopic coronary artery bypass grafting on the beating heart. *Thorac Cardiovasc Surg* 2000; 48: 198-202.
- Binder J, Brautigam R, Jonas D, Bentas W. Robotic surgery in urology: fact or fantasy? *BJU Int*. 2004; 94(8): 1183-7.
- Woo R, Le D, Krummel TM, Albanese C. Robot-assisted pediatric surgery. *Am J Surg* 2004; 188(4A Suppl): 27S-37S.
- Melvin WS, Needleman BJ, Krause KR, Schneider C, Wolf RK, Michler RE, Ellison EC. Computer-enhanced robotic telesurgery: initial experience in foregut surgery. *Surg Endosc* 2002; 16: 1790-2.
- Delaney CP, Lynch AC, Senagore AJ, Fazio VW. Comparison of robotically performed and traditional laparoscopic colorectal surgery. *Dis Colon Rectum*. 2003; 46(12): 1633-9.
- Beste TM, Nelson KH, Daucher JA. Total laparoscopic hysterectomy utilizing a robotic surgical system. *J Soc Laparoendosc Surg* 2005; 9(1): 13-5.
- Molpus KL, Wedergren JS, Carlson MA. Robotically assisted endoscopic ovarian transposition. *JLS*. 2003; 7(1): 59-62.
- Sundaram BM, Kalidasan G, Hemal AK. Robotic repair of vesicovaginal fistula: a case-series of 5 patients. *Urology* 2006; 67(5): 970-3.
- Di Marco DS, Chow GK, Gettman MT, Elliott DS. Robotic-assisted laparoscopic sacrocolpopexy for treatment of vaginal vault prolapse. *Urology* 2004; 63(2): 373-6.
- Elliott DS, Frank I, DiMarco DS, Chow GK. Gynecological use of robotically assisted laparoscopy: sacrocolpopexy for the treatment of high-grade vaginal vault prolapse. *Am J Surg* 2004; 188(Suppl): 52S-56S.



# MEETING FACILITIES

of The Federation of Medical Societies of Hong Kong

| Venue or Meeting Facilities      | Member Society<br>(Hourly Rate HK\$) | Non-Member Society<br>(Hourly Rate HK\$) |
|----------------------------------|--------------------------------------|--|
| Meeting Room (Max 30 persons)    | 115.00                               | 230.00                                   |
| Council Chamber (Max 20 persons) | 175.00                               | 350.00                                   |
| Lecture Hall (Max 110 persons)   | 230.00                               | 460.00                                   |
|                                  | <b>Per Session</b>                   | <b>Per Session</b>                       |
| Slide/Overhead Projector         | 50.00                                | 50.00                                    |
| TV (with video)                  | 100.00                               | 100.00                                   |
| LCD Projector (per session)      | 500.00                               | 500.00                                   |

查詢及租用

### Enquiry & Booking:

請於辦公時間內致電 2527 8898 與本會秘書處聯絡。  
Please contact the Secretariat at 2527 8898 during office hours.

地址：香港灣仔軒尼詩道十五號溫莎公爵社會服務大廈四樓  
Address : 4/F Duke of Windsor Social Service Building, 15 Hennessy Road, Wanchai, Hong Kong

電話 Tel: 2527 8898 傳真 Fax: 2865 0345  
網址 Homepage: www.fmshk.org 電子郵件 E-mail: info@fmshk.org

(Effective from June 2007)

## Special Offers:

Room rental during office hours Monday to Friday from 9:30am - 5:30pm,

**40% discount**

DST SERIES™ EEA™ STAPLERS

**Cutting-Edge  
Technology.**

**All-Around  
Security.**

autosuture<sup>as</sup>  
advancing possibilities in surgery





## A Brief Update on Laparoscopic Assisted Colectomy

**Dr. C C Chung**

FRCS (Edin.), FHKAM

Consultant Surgeon and Chief of Lower GI Surgery, Pamela Youde Nethersole Eastern Hospital  
Honorary Consultant, Hong Kong Sanatorium & Hospital



Dr. C C Chung

### Current status of Laparoscopic Assisted Colectomy

Since the first reported laparoscopic assisted colectomy (LAC) for endometriosis in 1991<sup>1</sup>, the laparoscopic approach has been applied in the treatment of many colorectal conditions. Different techniques were described, and innovative approaches were developed. This development has been at least in part facilitated by advances in medical technology—the advent of mechanical endostaplers, ultrasonic dissectors, hand access devices and laparoscopic ultrasonography etc. all contributed.

Compared to open surgery, there is now a wealth of evidence indicating that LAC results in definite short term clinical benefits in terms of diminished pain, earlier return of bowel function, better preserved pulmonary function, decreased abdominal wound infection rate, reduced incidence of postoperative adhesive obstruction, and shorter hospitalisation<sup>2</sup>. Admittedly the last benefit on reduced length of stay is only marginal, as hospital stay varies widely in different parts of the world and depends as much on health care finance and insurance system as on patients' condition.

For reasons stated above LAC should be recommended without reservation to patients with benign colorectal conditions. Thus LAC is widely applied and practised in patients with diverticular disease and inflammatory bowel disease in Western Countries. However, neither of these conditions are prevalent in Hong Kong, where malignancy constitutes the main volume of work for coloproctologists or general surgeons.

Data from recently published randomised trials have helped to alleviate the sceptism in the applicability of LAC to patients suffering from colorectal cancer<sup>3-10</sup>. Indeed evidence from all these trials fails to demonstrate any detriment in oncological parameters such as disease recurrence and patient's survival subsequent to the laparoscopic approach. Moreover, data from the Barcelona trial showed that, after stratification according to TNM staging, in patients with stage III tumour the laparoscopic group was independently associated with reduced risk of recurrence and cancer-related death, and improved overall survival<sup>4</sup>. In other words, aside from technical feasibility, LAC also appears oncologically feasible. This message is of paramount importance and has a great impact on the management of colorectal cancer worldwide, including Hong Kong. The current consensus

is that, provided expertise is available, the utility of laparoscopy in potentially curable colorectal carcinoma can be judiciously extended<sup>2</sup>.

### Commonly Asked Questions about LAC

Many quoted advantages of LAC like less blood transfusion and analgesic requirement, reduced length of stay, earlier return of GI function etc. are not obvious in the patients' perspective. Are there any real health-related benefits of LAC?

Yes. Various studies have consistently showed that LAC is associated with reduced incidence of chest infection<sup>6,11,12</sup>, decreased wound complications including infection, dehescence and hernia<sup>13,14</sup>, as well as reduced incidence of postoperative adhesive obstruction<sup>13,14</sup>.

#### *Are there any patients who are contraindicated for LAC?*

There are very few absolute contraindications. Of course, caution needs to be exercised in patients with severe pulmonary disease or congestive heart failure; while these patients withstand a prolonged operation with protracted pneumoperitoneum poorly, they are also at increased risk of developing chest complications should open surgery be used. In difficult cases close collaboration with an anaesthetist experienced in laparoscopic surgery is necessary to ensure a safe and smooth procedure.

Though laparoscopic surgery may prove difficult in patients with extensive intra-abdominal adhesions, adhesions can only be considered as a relative contraindication<sup>15</sup>. Likewise, patients with high body mass index are only relatively contraindicated.

#### *What about case selection? Which kind and what stage of tumour are suitable for LAC?*

In the past there was worry that advanced tumour with serosal or extramural spread would result in unacceptably high incidence of trocar site recurrence subsequent to LAC. As experience accumulates, it is now evident that, while the exact mechanism of trocar site recurrence remains unknown (this can occur even in T1 tumours), this phenomenon had been over-reported previously and its true incidence is no more than wound recurrence after open surgery<sup>2</sup>.

On the other hand, lessons learned from conversions did give some lights on case selection. Many published



reports on LAC did not give reason for conversion. For those that did so, instrumental or equipment failure, adhesions, iatrogenic injury, and bulky or fixed (locally advanced) tumour appeared to be common reasons. While conversion rate depends on surgeon's expertise, conversion due to the last reason is unlikely to be altered by surgeon's experience or improvement in technology. The weight and bulk of some of these locally advanced tumours make mobilisation using long and thin instruments difficult, and render these tumours susceptible to traumatising during mobilisation. Thus locally advanced, sizable tumour (e.g. palpable tumour per abdomen) might not be a good case for LAC, especially for surgeons in the learning phase. In the author's opinion, tumours with contiguous organ involvement are contraindicated for LAC.

**Who should be doing LAC? Colorectal surgeons or laparoscopic surgeons?**

The correct emphasis should be placed on proper training. In the past, surgical training was based on a master-apprentice model in the operating room. But this concept of training has been changed after the introduction of laparoscopic technique in the general surgery field. Laparoscopic surgery requires specialised dexterity different from open surgery due to translation of a 2-dimensional video image into a 3-dimensional working area, decreased tactile feedback, varied hand-eye coordination, and fulcrum effect. For advanced procedure like LAC, more time and effort are needed to overcome the learning curve. Thus the training programme should first involve a credentialing process led by a dedicated credentialing committee. Formal training programme in form of courses, hands on practice or simulators (training box, virtual reality system), live animals or human cadaver should be provided. The candidate can then involve himself in human operation under supervision of the mentor in his own unit, and should go through the role as camera assistant, assistant surgeon and finally chief surgeon. Performance should be monitored periodically by a separate proctor, with audit of operative outcomes.

**Conclusion: The Way Forward**

Laparoscopic surgery has a significant impact on the management of colorectal cancer in the past decade. The magnified view under the laparoscope and the use of alternative energy source other than electrocautery have led to more understanding of surgical anatomy and indeed have even changed the way how open surgery is being performed. Although most of the evidence came from LAC, increasingly rectal cancer resections are being performed laparoscopically as experience and confidence grow—laparoscopic sphincter-preserving, nerve-sparing total mesorectal excision has already been reported at the turn of the century<sup>16-19</sup>. Moreover, there is a recent enthusiasm for hand assisted laparoscopic surgery as well as endoluminal stenting (Fig. 1). It is hoped that these techniques can help to broaden the applicability of the laparoscopic approach so that patients with bleeding or obstructing (Fig 2) tumours could still benefit from this minimally invasive technique. Data are still limited to draw any definite conclusion at the moment, however.

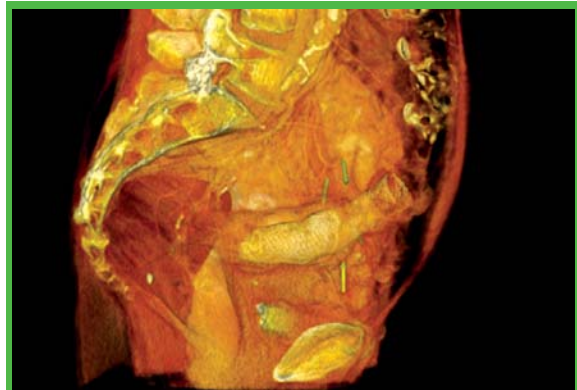


Fig. 1. 3-D CT reconstruction showing endoluminal stenting of an obstructed sigmoid tumour.

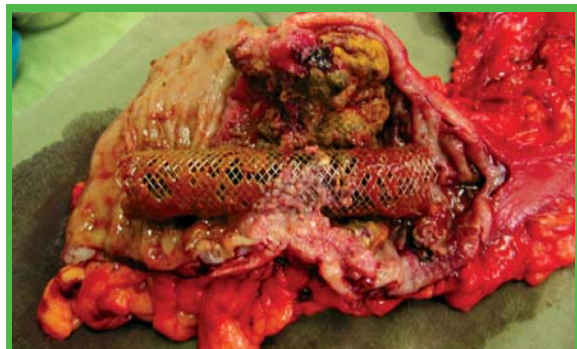


Fig. 2. Laparoscopic resection of an obstructed colon tumour. Note the endoluminal stent in-situ.

**References**

- Redwine DS, Sharpe DR. Laparoscopic Segmental Resection of the Sigmoid Colon for Endometriosis. *J Laparoendosc Surg* 1991; 1: 217-20.
- Chung CC, Tsang WWC, Kwok SY, Li MKW. Laparoscopy and Its Current Role in the Management of Colorectal Disease. *Colorectal Disease* 2003; 5: 528-43.
- Lace AM, Garcia VJ, Pique JM, et al. Short-term Outcome Analysis of a Randomized Study Comparing Laparoscopic vs Open Colectomy for Colon Cancer. *Surg Endosc* 1995; 9: 1101-5.
- Lace AM, Garcia-Valdecasas JC, Delgado S, et al. Laparoscopy-assisted Colectomy versus Open Colectomy for Treatment of Non-metastatic Colon Cancer: A Randomized Trial. *Lancet* 2002; 359: 2224-9.
- Braga M, Vignali A, Gianotti L, et al. Laparoscopic versus Open Colorectal Surgery. A Randomized Trial on Short-term Outcome. *Ann Surg* 2002; 236: 759-67.
- Milsom JW, Bohm B, Hammerhofer KA, Fazio V, Steiger E, Elson P. A Prospective Randomized Trial Comparing Laparoscopic versus Conventional Techniques in Colorectal Cancer Surgery: A Preliminary Report. *J Am Coll Surg* 1998; 187: 46-54.
- Stage JG, Schulze S, Moller P, et al. Prospective Randomized Study of Laparoscopic versus Open Colonic Resection for Adenocarcinoma. *Br J Surg* 1997; 84: 391-6.
- Wexner SD, Johansen OB, Noguera JJ, Jagelman DG. Laparoscopic Total Abdominal Colectomy. A Prospective Trial. *Dis Colon Rectum* 1992; 35: 651-5.
- Writing Committee of the Clinical Outcomes of Surgical Therapy Study Group of the Laparoscopic Colectomy Trial. A Comparison of Laparoscopically Assisted and Open Colectomy for Colon Cancer. *N Engl J Med* 2004; 350: 2050-9.
- Leung KL, Kwok SPY, Lam SCW, et al. Laparoscopic Resection of Rectosigmoid Cancer: Prospective Randomized Trial. *Lancet* 2004; 363: 1187-92.
- Schwenk W, Bohm B, Witt C, Junghans T, Grundel K, Muller JM. Pulmonary Function Following Laparoscopic or Conventional Colorectal Resection: A Randomized Controlled Evaluation. *Arch Surg* 1999; 134: 6-13.
- Wong DCT, Chung CC, Chan ESW, Kwok ASY, Tsang WWC, Li MKW. Laparoscopic Abdominoperineal Resection Revised: Are There Any Health-related Benefits? A Comparative Study. *Tech Coloproctol* 2006; 10(1): 37-42.
- Franklin ME Jr, Rosenthal D, Abrego-Medina D, et al. Prospective Comparison of Open vs Laparoscopic Colon Surgery for Carcinoma: Five Year Results. *Dis Colon Rectum* 1996; 39: 535-46.
- Lacy AM, Garcia VJ, Delgado S, et al. Postoperative Complications of Laparoscopic-assisted Colectomy. *Surg Endosc* 1997; 11: 119-22.
- Kwok SY, Chung CC, Tsang WWC, Chan ESW, Li MKW. Laparoscopic Resection for Colorectal Adenocarcinoma in Patients with Previous Abdominal Surgery: A Comparative Study. *Ann Coll Surg HK* 2004; 8: 115-9.
- Chung CC, Ha JPY, Tsang WWC, Li MKW. Laparoscopic-assisted Total Mesorectal Excision and Colonic J Pouch Reconstruction in the Treatment of Rectal Cancer. *Surg Endosc* 2001; 15: 1098-1101.
- Tsang WWC, Chung CC, Kwok SY, Li MKW. Minimally Invasive Surgery for Rectal Cancer. *Surg Clin N Am* 2005; 85: 61-73.
- Tsang WWC, Chung CC, Li MKW. Prospective Evaluation of Laparoscopic Total Mesorectal Excision with Colonic J-pouch Reconstruction for Mid and Low Rectal Cancers. *British Journal of Surgery* 2003; 90: 867-71.
- Tsang WWC, Chung CC, Kwok SY, Li MKW. Laparoscopic Sphincter-preserving Total Mesorectal Excision with Colonic J-pouch Reconstruction: Five-year Results. *Annals of Surgery* 2006; 243(3): 353-8.

# Hong Kong International Medical & Health Care Fair 2007



- ✓ Over 119,000 visitors attended 2006 fair
- ✓ Over 110 exhibitors from 15 countries & regions at last year's event
- ✓ Take advantage of our Public Forum presented by industry experts
- ✓ Held concurrently with International Conference & Exhibition of the Modernization of Chinese Medicine & Health Products 2007 and Food Expo 2007

## Major Exhibits

- Health Care Services (Consumer Health, Elderly Care, Dental, Hospital Service, Medical Centre, Physiotherapy, Speech and Hearing, Laboratory, Health Insurance)
- Dental Care Products, Equipment and Accessories
- Health Care Products and Medical Equipment
- Laboratory Equipment
- Others (Disposable Medical Products, Medical Database Systems, Health Care Courses and Publications)

16-20 / 8 / 2007

Hong Kong Convention and Exhibition Centre  
<http://hkmed-healthfair.com>

## Register Today!

Don't miss the opportunity to pre-register online – before 25 July for buyers from outside Hong Kong and before 9 August for local buyers – to receive your free admission badge by mail.

 香港貿易發展局  
Hong Kong Trade Development Council

Exhibitions Department, Unit 13, Expo Galleria,  
Hong Kong Convention and Exhibition Centre,  
1 Expo Drive, Wanchai, Hong Kong  
Tel: (852) 2584 4333 Fax: (852) 2824 0026  
E-mail: [exhibitions@tdc.org.hk](mailto:exhibitions@tdc.org.hk) Website: [www.hktdcfairs.com](http://www.hktdcfairs.com)

 CP EXHIBITION  
CHINA PROMOTION LTD. 華進

Room 1703, Tung Wai Commercial Building,  
109 Gloucester Road, Wanchai, Hong Kong  
Tel: (852) 2511 7427 Fax: (852) 2511 9692  
E-mail: [cp@cpexhibition.com](mailto:cp@cpexhibition.com)  
Website: [www.cpexhibition.com](http://www.cpexhibition.com)

 HONG KONG INTERNATIONAL  
**Medical & Health Care Fair**  
香港國際醫療及保健服務展



## The Use of Robot in Urology

**Dr. Wai-sang Wong**

MBBS, FRCS, FRACS, FCSHK, FHKAM, FRACS(Urology)

Director of Urology Center, Hong Kong Sanatorium & Hospital

*This article has been selected by the Editorial Board of the Hong Kong Medical Diary for participants in the CME programme of the Medical Council of Hong Kong (MCHK) to complete the following self-assessment questions in order to be awarded one CME credit under the programme upon returning the completed answer sheet to the Federation Secretariat on or before 30 June 2007.*

Minimally invasive surgery by laparoscopic means expanded tremendously in 1990s. Laparoscopic surgery is performed with similar surgical techniques as in open surgery but through small cut wounds. The obvious advantages of less wound pain, short hospital stay, short convalescent period, small external scars and similar surgical results to open surgery, make many types of laparoscopic surgery the new standard of treatment. Most of the nephrectomies were quickly taken over by laparoscopic means in 1990s. The laparoscopic urological surgery was then extended from destructive surgery to surgery that required some reconstructive procedures like pyeloplasty and partial nephrectomy. Problems arose when laparoscopic surgery was used to perform radical prostatectomy which required fine dissection and complex reconstruction. Schuessler<sup>1</sup> from USA commented in 1997 that laparoscopic radical prostatectomy had no advantages as compared to open surgery because of the difficulties and long hours of operation. On the other side of the Atlantic Ocean, Vallancien<sup>2</sup> in 1999 and Abbou<sup>3</sup> in 2000, both from France, reported that laparoscopic radical prostatectomy was feasible. However, in order to achieve similar results to open surgery, experience in operating 150 laparoscopic radical prostatectomy was required. Even with skilled laparoscopic techniques, experience in operating 40 to 80 laparoscopic radical prostatectomy was required, a number that is difficult to be achieved by most urology centres in Asia because of the low incidence of prostate cancer.

The dexterous human hands have six degrees of freedom and can be fully utilised in open surgery. Long and small instruments are used in laparoscopic surgery. The instruments are confined by small cut wounds and allow only four degrees of freedom. The long and small instruments also have chopstick and fulcrum effects which further decrease the dexterity. The surgeons have to operate with a 2-dimensional image from the monitor. The surgeons have also to perform the laparoscopic radical prostatectomy with twisted postures which bring fatigue and tiredness. All these drawbacks make many of the experienced American urologists with skilled open surgical techniques finding the laparoscopic radical prostatectomy very difficult to learn. The da Vinci Surgical System, a surgical robot, allows the direct transfer of open surgical techniques to

perform radical prostatectomy through small cut wounds. Many of the American urologists have been using robots in performing radical prostatectomy. Comments have been made that in the foreseeable future, all complex laparoscopic surgery will be performed by robots.

The prototype of the da Vinci Surgical System was developed by the Stanford Research Institute in 1980's and was funded by the US Army who planned to develop a robotic system to perform battlefield surgery remotely by surgeons in the safe rear. The da Vinci Surgical System was first used in human surgery in 1997 in Europe. FDA approved the use of the da Vinci Surgical System in 2000. The first robotic radical prostatectomy was performed in Europe in 2000. By the end of 2006, 559 da Vinci Surgical Systems have been installed worldwide, mostly in America. Over 70,000 robotic surgeries have been performed in 2006. Less than 1% of the radical prostatectomy was performed by robots in 2001 in America. In 2006, it rose to over 40% that meant over 30,000 robotic radical prostatectomies. The da Vinci Surgical System was initially designed for coronary arterial bypass surgery through small cut wounds. American Urologists quickly used the robots to perform radical prostatectomy.

The da Vinci Surgical System consists of a surgeon console, a patient cart with three or four robotic arms, and a vision cart. The surgical robot belongs to the master and slave system. The surgeon directly initiates all movements of the robotic instruments in real time. The laparoscope of the da Vinci Surgical System has a two lens system which produces a high definition and 3-dimensional binocular vision. The image can be magnified ten to fifteen times. The endowrist instruments have two joints at the distal 2cm tip and produce two more degrees of freedom. The dexterity of the human hands has returned in operating with endowrist instruments. The robot can filter off hand tremors and scale down the movements five times. The special features translate into improved dexterity, better control and precision in operating movements. The surgeon can also sit comfortably at the console to operate on the patient through the patient cart a few feet away.

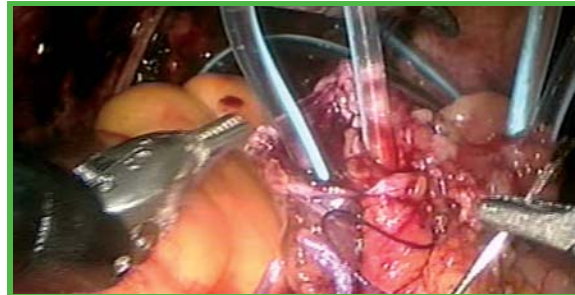
Menon from America claimed himself as untrainable in



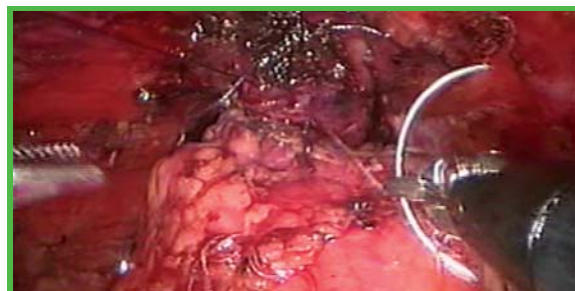laparoscopic radical prostatectomy. He has performed over 3,000 robotic radical prostatectomy and commented that surgeons with minimal laparoscopic experience could directly transfer the open surgical techniques to perform laparoscopic radical prostatectomy with the help of the robot. After operating 20 robotic radical prostatectomy, the surgical results would be similar to those of open radical prostatectomy. Ahlering from America even commented that surgeons with experience in open techniques but no laparoscopic experience, after performing 8 to 12 robotic radical prostatectomy, would achieve surgical results comparable to those of skilled laparoscopists who had performed over 100 laparoscopic radical prostatectomy. Robotic radical prostatectomy requires a short long curve and can be learned by most urologists. As compared to open surgery, robotic radical prostatectomy has the advantages of shorter hospital stay, shorter convalescent period, less blood loss, shorter urethral catheterisation time<sup>4</sup>. Menon and others<sup>5</sup> also claimed that robotic radical prostatectomy had a better cancer control, faster return of urinary continence and erectile function.

The da Vinci Surgical System is an expensive equipment and has costly consumables. It is mainly used for complex laparoscopic surgery on a cost-effectiveness basis. The robot was first installed in a public hospital in Hong Kong in November 2005. In the first year, the urology team used the robot to perform 17 radical prostatectomy, 3 radical cystectomy, 3 partial nephrectomy, 2 ureterocalycostomy, 1 pyeloplasty, and 1 ureteroureterostomy. In performing radical prostatectomy, the robot has advantages in dissecting and preserving the neurovascular bundles from the prostate, in dissecting and dividing the urethra from the apex of the prostate, in joining the bladder to the urethra with a water-tight anastomosis. After performing a radical cystectomy on a female patient, an intracorporeal ileal conduit was done. The operation required anastomosing of the small bowel and anastomosing of the ureters to the small bowel. Without the robot, it would be extremely difficult for me to perform such operation with conventional laparoscopic instruments. The da Vinci S Surgical System, an upgrade model, was installed in a private hospital in Hong Kong in March 2007. In the first month, 11 robotic urological surgeries, 9 radical prostatectomy, 1 pyeloplasty, 1 partial nephrectomy, have been done. The upgrade model has the advantages of faster setup, more rapid exchange of instruments and wider intra-abdominal access.

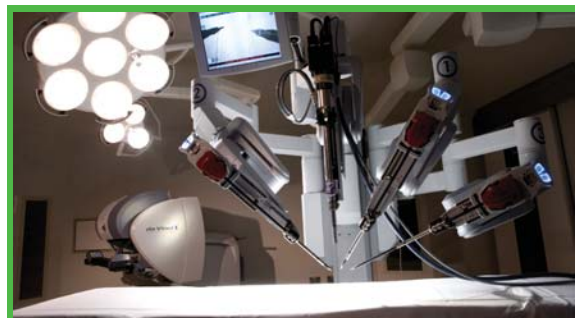Most of the robots have been used in urological surgery. The robots can also be used in many complex laparoscopic surgery in other surgical specialties. The company manufacturing the robots targeted at prostatectomy, hysterectomy, cardiac surgery and gastric surgery. Many Asian centres have installed or are going to install the robots for clinical use, including two centres in Mainland China. A revolution has already been started and robotic surgery will soon become the new standard for complex laparoscopic surgery.



Joining of ureters to small bowel in constructing ileal conduit



Joining of bladder to urethra after radical prostatectomy



da Vinci S Surgical System



surgeon operating at the console

## References

- Schuessler WW, Schulam PG, Clayman RV, Kavoussi LR. Laparoscopic radical prostatectomy: initial short term experience. *Urology*, 50(6): 854-7, 1997.
- Guillonneau B, Vallancien G. Laparoscopic radical prostatectomy: initial experience and preliminary assessment after 65 operations. *Prostate*, 39(1): 71-5, 1999.
- Abbou CC, Salomon L, Hoznek A, Antiphon P, Cicco A, Saint F, Alame W, Bellot J, Chopin DK. Laparoscopic radical prostatectomy; preliminary results. *Urology*, 55(5): 630-4, 2000.
- Menon M, Shrivastava A, Tewari A. Laparoscopic radical prostatectomy: conventional and robotic. *Urology*, 66(Suppl): 101-4, 2005.
- Ahlering TE, Skarecky D, Lee D, Clayman RV. Successful transfer of open surgical skills to a laparoscopic environment using a robotic interface: initial experience with laparoscopic radical prostatectomy. *Journal of Urology*, 170(5): 1738-41, 2003.



**MCHK CME Programme Self-assessment Questions**

Please read the article entitled "The Use of Robot in Urology" by Dr. Wai-sang Wong , and complete the following self-assessment questions. Participants in the MCHK CME Programme will be awarded 1 CME credit under the Programme for returning completed answer sheets via fax (2865 0345) or by mail to the Federation Secretariat on or before 30 June 2007. Answers to questions will be provided in the next issue of The Hong Kong Medical Diary.

Questions 1-10: Please answer T (true) or F (false)

1. The da Vinci Surgical System is a surgical robot using the master and slave system.
2. The da Vinci Surgical System is only used for complex laparoscopic surgery in urology.
3. The endowrist instruments can move with six degrees of freedom. (True)
4. The laparoscope of the surgical robot gives superb vision with a magnified and 3-dimensional image.
5. The most common robotic surgery is surgery for prostate cancer.
6. Robotic surgery on prostate cancer as compared to open surgery has improved results on urinary continence and potency.
7. Laparoscopic experience is required in operating the robot.
8. The learning curve is long in doing complex laparoscopic surgery with the robot as compared to the conventional laparoscopic method.
9. Open surgery has better control and precision as compared to robotic surgery.
10. The da Vinci surgical robots are installed in most of the major medical centres in Asia.

**ANSWER SHEET FOR JUNE 2007**

Please return the completed answer sheet to the Federation Secretariat on or before 30 June 2007 for documentation. 1 CME point will be awarded for answering the MCHK CME programme (for non-specialists) self-assessment questions.

**The Use of Robot in Urology**

**Dr. Wai-sang Wong**

MBBS, FRCS, FRACS, FCSHK, FHKAM, FRACS(Urology)  
Director of Urology Center, Hong Kong Sanatorium & Hospital

1  2  3  4  5  6  7  8  9  10

Name (block letters): \_\_\_\_\_ HKMA No.: \_\_\_\_\_

HKID No.: \_\_\_\_\_ - \_\_\_\_\_ X X (x) Other Membership No. (please indicate): \_\_\_\_\_

Contact TelNo.: \_\_\_\_\_

**Answers to May 2007 issue**

**Management of Common Pubertal Problems**

1. c      2. b      3. a      4. a      5. c      6. c      7. b      8. b      9. d      10. d



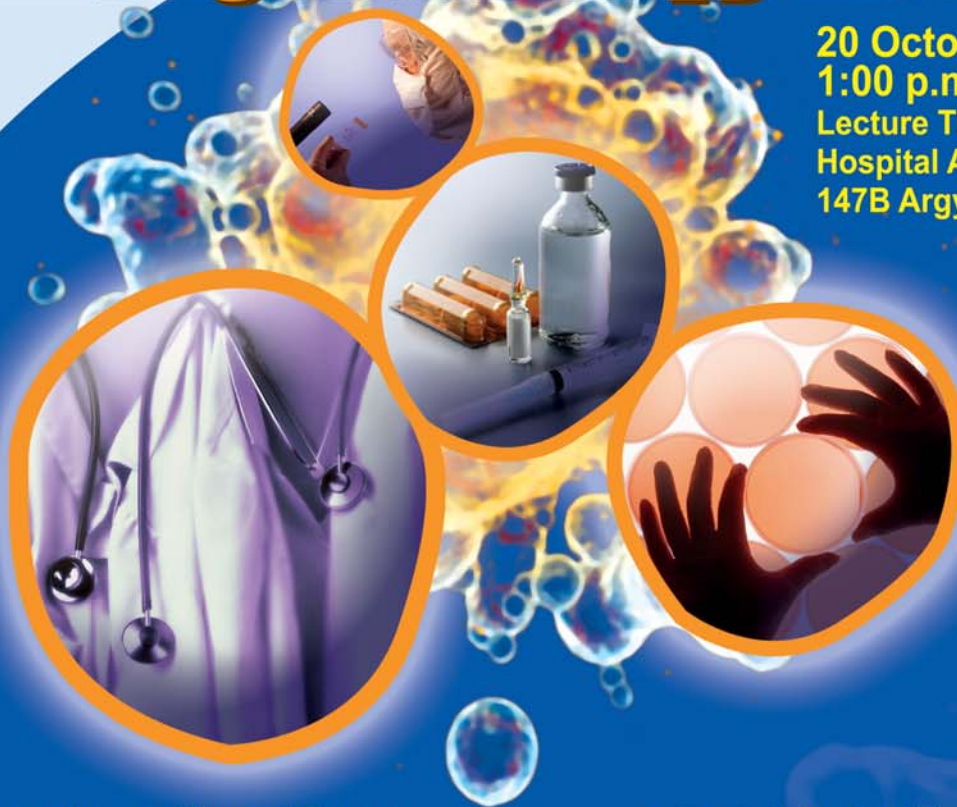THE FEDERATION OF MEDICAL SOCIETIES  
OF HONG KONG

The Federation's Annual Scientific Meeting

2007

# Targeted Therapy in Cancer

20 October, 2007 (SAT)  
1:00 p.m. - 5:30 p.m.  
Lecture Theatre, M/F,  
Hospital Authority Building,  
147B Argyle Street, Kowloon



- **Overview and Breast Cancer**  
Prof. Richard J. Epstein  
Department of Medicine, Queen Mary Hospital, The University of Hong Kong
- **Head and Neck Cancer**  
Dr. Daniel TT Chua  
Department of Clinical Oncology, Queen Mary Hospital, The University of Hong Kong
- **Lung Cancer**  
Dr. James CM Ho  
Department of Medicine, Queen Mary Hospital, The University of Hong Kong
- **Gastrointestinal Tract Cancers**  
Prof. Benjamin CY Wong  
Department of Medicine, Queen Mary Hospital, The University of Hong Kong
- **Haematological Malignancies**  
Dr. James CS Chim  
Department of Medicine, Queen Mary Hospital, The University of Hong Kong
- **Childhood Malignancies**  
Dr. Godfrey CF Chan  
Department of Paediatrics, Queen Mary Hospital, The University of Hong Kong

## Registration Fee

HK\$100 Members of member societies

HK\$200 Non-member

## Registration

Registration forms can be obtained by calling our Secretariat at 2527 8898 or the homepage <http://www.fmskh.org>. Please send registration form and cheque to: The Federation of Medical Societies of Hong Kong, 4/F, Duke of Windsor Social Service Building, 15 Hennessy Road, Wanchai, Hong Kong. Registration will be on first-come-first-serve basis.

**CME/CPE:** Please refer to our homepage <http://www.fmskh.org> for details



THE FEDERATION OF MEDICAL SOCIETIES OF HONG KONG  
香港醫學組織聯合會

# The Federation's Annual Scientific Meeting **2007** **Targeted Therapy in Cancer**

20 October, 2007 (SAT) 1:00 p.m. - 5:30 p.m.

Lecture Theatre, M/F, Hospital Authority Building, 147B Argyle Street, Kowloon

## APPLICATION FORM

Surname: Prof. / Dr. / Mr. / Ms. \_\_\_\_\_ First name: \_\_\_\_\_  
(block letters please) (block letters please)

Position: \_\_\_\_\_

Address: \_\_\_\_\_

\_\_\_\_\_ E-mail: \_\_\_\_\_

Tel. No.: \_\_\_\_\_ Fax No.: \_\_\_\_\_

Please tick as appropriate:

- I will attend the Federation's Annual Scientific Meeting 2007.
- I will have/not have lunch.
- I am a member of \_\_\_\_\_  
(member society of the Federation of Medical Societies of Hong Kong)  
Enclosed please find a cheque in the amount of \_\_\_\_\_. (HK\$100 for medical, dental, nursing and healthcare professionals).
- I am not a member of member society of the Federation of Medical Societies of Hong Kong.  
Enclosed please find a cheque in the amount of \_\_\_\_\_. (HK\$200 for medical, dental, nursing and healthcare professionals).

\_\_\_\_\_  
Signature

\_\_\_\_\_  
Date

Remarks: Please send registration form with cheque made payable to "**The Federation of Medical Societies of Hong Kong**" to 4/F, Duke of Windsor Social Service Building, 15 Hennessy Road, Wanchai, Hong Kong. Registration will be on first-come-first-served basis. No refund will be made if you have to cancel your registration afterwards.

=====  
**For office use:**

Registration confirmed on \_\_\_\_\_ Registration Number \_\_\_\_\_

Cheque Issuing Bank \_\_\_\_\_ Cheque Number \_\_\_\_\_





# Local Experience of Laparoscopic Pancreatectomy

**Dr. Chung-ngai Tang**

Consultant Surgeon  
Chief of Hepatobiliary Surgery  
Co-director of Minimal Access Surgery Training Centre  
Pamela Youde Nethersole Eastern Hospital, HKEC



Dr. Chung-ngai Tang

## Introduction

With the explosive development of laparoscopic surgery, there is increasing number of patients with different pancreatic pathologies who can now be managed by minimal access approach. Laparoscopy has been widely used to stage pancreatic tumours and to palliate obstructive symptoms in advanced malignancy.<sup>1-5</sup> Laparoscopic pancreatectomy is a step further as a result of skill maturation and refinement of instruments. There are basically three main types of laparoscopic pancreatectomy, which include (1) enucleation, (2) distal pancreatectomy and (3) pancreaticoduodenectomy (Whipple).

Laparoscopic enucleation is commonly performed for those small neuroendocrine tumours located away from the main pancreatic duct but the danger of pancreatic fistula cannot be underestimated. In order to guarantee good postoperative outcome, special attention should be given to intraoperative localisation and preservation of the main pancreatic duct.<sup>6-8</sup>

Favourable results have also been obtained in cases of either chronic pancreatitis or benign neoplasms (cystic or small neuroendocrine tumours) undergoing laparoscopic distal pancreatectomy.<sup>9-12</sup> This approach, rather than enucleation, is preferred for patients with multiple neuroendocrine tumours involving body and tail of pancreas. Therefore laparoscopic ultrasound is indispensable not just to accurately locate and delineate the tumour relationship with the main pancreatic duct but also to exclude multifocality.<sup>13</sup> The favourable results of laparoscopic distal pancreatectomy can also be accounted by the relatively simple anatomy at the pancreatic tail and furthermore it does not require complicated reconstruction and extensive lymphatic dissection.<sup>9-12</sup>

Since Gagner et al described the first laparoscopic Whipple in 1994, it has not gained worldwide popularity because of the complexity of procedure, long operating time and higher complication rate.<sup>14-15</sup> Experience of laparoscopic Whipple for malignant tumour at the head of pancreas is still very limited despite the explosive development in other laparoscopic abdominal surgery.<sup>14-18</sup>

In the following paragraphs, the different techniques of laparoscopic distal pancreatectomy and Whipple are described in details followed by sharing of our experience of laparoscopic pancreatectomy in Pamela Youde Nethersole Eastern Hospital (PYNEH).

## Surgical Technique in Laparoscopic Distal Pancreatectomy

Indications for operation include mainly cystic neoplasms and small neuroendocrine tumours located at the body / tail of pancreas. All the patients are initially investigated with abdominal ultrasound (USG) and computed tomography (CT). If splenectomy is planned preoperatively, in addition to routine antibiotics prophylaxis, vaccination against pneumococcus and haemophilus should be given 2-4 weeks prior to surgery.

### 1. Position of patient and ports

The operation is performed under general anaesthesia with endotracheal intubation and the patient is placed in Lloyd-Davis position with legs apart. Since the spleen may have to be resected with the distal pancreas, a foam pad can be placed under the left chest to enhance exposure. Chief surgeon stands between the patient's legs with the first assistant on the surgeon's right side and the cameraman on the other side. The port positions are not fixed and usually 6 ports are used for total laparoscopic resection whereas 4 trocar ports and 1 hand-port for hand-assisted laparoscopic distal pancreatectomy. The layout of ports should be in such a way that both the surgeon and first assistant can work simultaneously during dissection. The length of the hand-port will depend on the hand size of the operating surgeon and it is usually situated on the right side of abdomen. (Figure 1)

### 2. Dissection into the lesser sac and laparoscopic examination

Diagnostic laparoscopy is performed following subumbilical cut-down and creation of pneumoperitoneum, the pressure is maintained at about 12mmHg. The lesser sac is then entered after division of the gastrocolic ligament using Harmonic Scalpel® (Ethicon Endo-Surgery Inc., Cincinnati, USA). Precaution should be taken not to jeopardise the gastro-epiploic arcade at this juncture. The dissection is continued towards the short gastric vessels and also close to the origin of right gastro-epiploic artery. A flexible retractor, inserted via the subxiphoid port, is used to retract up the greater curvature of the stomach for better exposure of the whole pancreas. The lesion is carefully assessed and the planned resection line is marked with cautery following laparoscopic ultrasound examination (UST-5536-7.5 MHz, linear array probe, Aloka, Tokyo, Japan)

### 3. Mobilisation of spleen in splenic-resecting laparoscopic pancreatectomy

The issue of splenic preservation is still controversial. In



general, it is recommended in obviously benign cases in view of the potential risk of fulminating sepsis following splenectomy. There is slight variation of procedure depending on whether there is any intention to preserve the spleen. Adequate exposure of both the spleen and pancreas is important to ensure a smooth operation, and we find the use of a foam pad under the left chest and a surgeon - controlled adjustable table very helpful. From our experience, we realise that it would be very tedious and technically demanding to preserve splenic artery and vein. In addition, the multiple tiny branches to supply the pancreas can only be appreciated after division of the pancreatic neck and therefore it is often approached first in contrary to the splenic-resecting approach in which the spleen is mobilised first and detached from tail of pancreas early on. Another possible approach is to sacrifice the splenic artery and vein but to preserve all the short gastric vessels in order to maintain adequate splenic blood supply. The drawbacks are potential segmental splenic infarction and formation of localised gastric varices. Fortunately this complication is uncommon and may not be associated with any clinical manifestation. Based on current evidence, there is no standard recommendation regarding the best approach of splenic preservation, but we believe the decision should be based on surgeon's experience and the likelihood of malignancy.

In splenic-resecting laparoscopic distal pancreatectomy, all the short gastric vessels are divided and the spleen is mobilised by dividing its attaching ligaments. With the use of the Harmonic Scalpel<sup>®</sup>, clear dissection can be easily accomplished with minimal blood loss. There is an avascular plane posterior to the tail of pancreas close to the splenic hilum. The gland is elevated posteriorly until a window is created at the superior border of pancreas. (Figure 2) Due to the limited space, it is sometimes difficult to elevate the pancreas without separating the pancreatic tail from splenic hilum. In order to eliminate the dangling effect of the spleen, it is detached from the pancreatic tail with endo-GIA (2.5 / 60, Autosuture, United States Surgical Corp., Norwalk, CT, USA) before further dissection is continued towards the splenomesenteric junction.

#### **4. Splenic-preserving laparoscopic pancreatectomy**

Since the spleen receives dual arterial blood supply from the short gastric arteries and splenic artery, it is therefore possible to preserve the spleen by safeguarding either one of these vessels. However, dissection of splenic vessels from the superior border of pancreas can be very tedious due to its extensive tiny branches. A trick to overcome this is firstly to divide the pancreas neck anterior to the superior mesenteric vein using endo-GIA (4.5 / 60, Autosuture, United States Surgical Corp., Norwalk, CT, USA) once a tunnel is created behind the gland. (Figure 3) With the gland retracted towards the left side, those tiny branches can be clearly visualised and controlled individually using either ultrasonic dissector or endoclip up to the splenic hilum.

An alternative is to preserve the short gastric vessels and simply divide the splenic artery and vein. This approach has the theoretical risk of developing gastric

varices and segmental splenic infarction but it does simplify the operation and cut down the risk of massive haemorrhage.

#### **5. Pancreatic resection**

With the pancreatic tail retracted and elevated, the gland is freed posteriorly towards the splenomesenteric vein junction. At this point it is necessary to consider if hand-assistance is required. Although successful total laparoscopic distal pancreatectomy has been previously reported, the additional tactile assistance from the hand can definitely increase the safety margin of the operation particularly if the dissection is very close to the splenomesenteric vein. If hand assistance is decided, we recommend insertion of the hand-port at the right side of abdomen. Usually a left hand is inserted through the hand-port for a right-handed surgeon. Once an adequate resection margin is ascertained, the pancreas is divided using endo-GIA (4.5 / 60, Autosuture, United States Surgical Corp., Norwalk, CT, USA). The final attachments of splenic artery and vein are also divided using vascular endo-GIA. The proximal pancreatic surface is carefully inspected for leakage. The cut end of pancreatic duct is controlled with titanium clip if it can be clearly identified. Haemostasis is secured and the transected surface is sprayed with tissue glue (Tisseel Kit, Tisseel, Immuno AG, Vienna, Austria).

If preservation of the splenic vessels is decided, dissection is then carried out exactly in reverse direction from the neck towards the splenic hilum. Similarly, the tail of pancreas is transected using endo-GIA when adequate margin is ascertained.

#### **6. Drainage, specimen retrieval and postoperative care**

A silicone drain is positioned close to the pancreatic stump. Specimen is delivered via a transverse incision at lower abdomen or via the hand-port using a protective bag depending on the approach. Perioperatively, subcutaneous octreotide (sandostatin, Novartis) injection is administered for a week to suppress pancreatic secretion and decrease the risk of pancreatic fistulation. Patient will resume diet when bowel activity returns and stitches are removed on day 7 after operation.

### **Surgical Technique of Laparoscopic Whipple**

The preoperative work-up is essentially the same as laparoscopic distal pancreatectomy but those patients selected usually have already been extensively investigated with imagings like CT and endoscopic retrograde cholangiopancreatography (ERCP). Perioperative subcutaneous injection of octreotide (sandostatin, Novartis) is also routinely given but preoperative vaccination is not required. The indications of operation are mainly malignant tumours involving periampullary region and sometime chronic pancreatitis mimicking malignancy.

#### **1. Position of patient and ports**

The patient position and lay out of the operating team



is more or less the same as laparoscopic distal pancreatectomy. The chief surgeon is operating at the foot end of the table, between the legs of the patient. The camera operator is on the left side of the table and another assistant surgeon on the opposite side. A Gelport (Applied Gelport® XE, Applied Medical Resources Corp. California, USA) is inserted at the right upper quadrant via a 7 cm horizontal skin incision and the rest of trocar ports are again similar. However it is slightly different from hand-port assisted laparoscopic distal pancreatectomy by having the hand-port incision just below the right costal margin such that some of the anastomoses can be performed via the incision using open instruments if appropriate. (Figure 4)

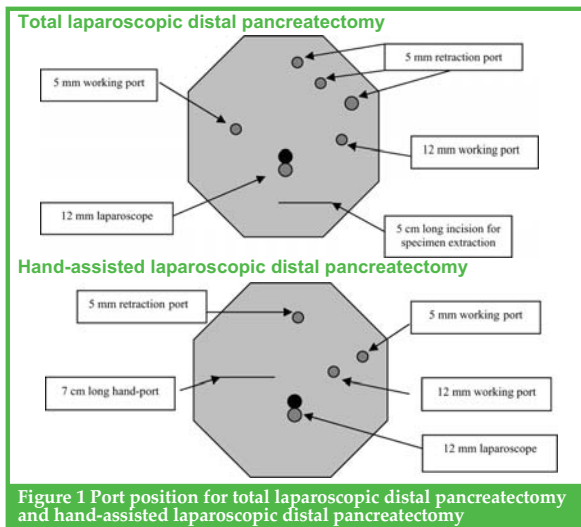


Figure 1 Port position for total laparoscopic distal pancreatectomy and hand-assisted laparoscopic distal pancreatectomy

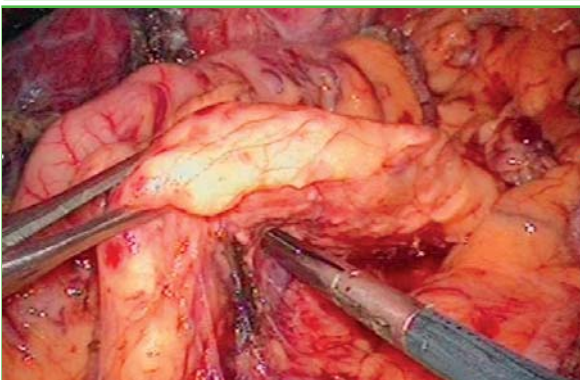


Figure 2. The pancreas is dissected free from the splenic vein posteriorly

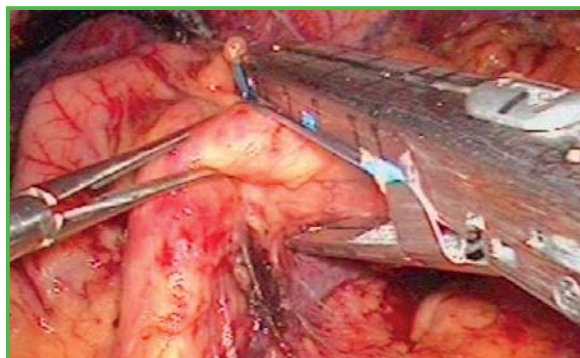


Figure 3. The pancreas is divided with endostapler at neck region

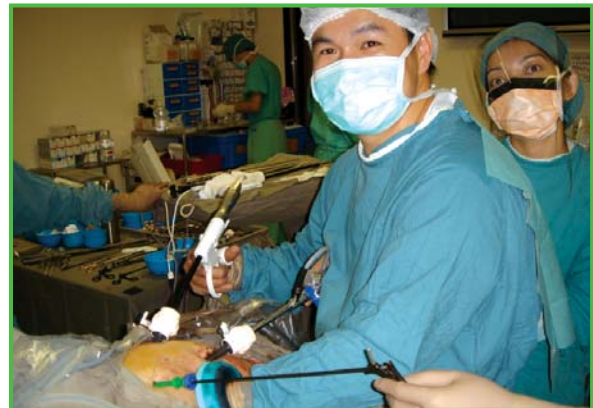

Figure 4. The layout of trocar ports and operating team for laparoscopic Whipple

## 2. Kocherisation of duodenum and dissection into lesser sac

Following diagnostic laparoscopy and laparoscopic ultrasonography in excluding tumour dissemination, duodenum is then extensively kocherised using both sharp and blunt dissection with the medial traction of laparoscopic hand until the anterior surface of inferior vena cava and part of the aorta is exposed. The lesser sac is then entered with the division of gastrocolic ligament using Harmonic Scalpel®. Stomach is mobilised and divided at about the distal one-third using an endostapler (4.5 / 80, Autosuture, United States Surgical Corp., Norwalk, CT, USA) but care should be taken not to jeopardise the blood supply to the gastric remnant. The superior mesenteric vein is identified below the pancreatic lower border when the middle colic vein is joining to it. After gaining a better exposure by dividing the stomach, a tunnel is then created between the neck of pancreas and superior mesenteric vein using cherry swab stick (Cherry Dissector, Ethicon Endo-surgery, Tokyo, Japan). A vascular sling is passed around the neck and prepares it for subsequent transection using ultrasonic dissector.

## 3. Bile duct dissection & mobilisation of ligament of Trietz

The gallbladder is freed from liver bed using retrograde approach and it is then grasped with the laparoscopic hand to facilitate isolation of common bile duct. The bile duct was transected just proximal to the cystic duct insertion with an endostapler which prevents spillage of any contaminated bile. Lymph nodes along the porta hepatis are cleared until both hepatic artery and portal vein are skeletonised.

When the ligament of Trietz is taken down with ultrasonic dissector, exposure can be enhanced by adjusting the table to left side up and head down position. Once the mesentery of duodenojejunal flexure is clearly defined, it is then controlled and transected with endostapler (3.5 / 60, Autosuture, United States Surgical Corp., Norwalk, CT, USA). Using the laparoscopic hand to grasp the duodenal stump, the third and fourth parts of duodenum are freed towards the right side until a tunnel is created behind the pedicle of superior mesenteric artery and vein. Thereafter the duodenum is pushed to the right and ready for the final detachment from superior mesenteric pedicle.



#### 4. Pancreatic transection

With the neck of pancreas elevated using a vascular sling, it is then transected with ultrasonic dissector and care should be taken not to injure the common hepatic artery which is situated just at the superior border of pancreas. Lymph nodes located at the superior border of pancreas and along the common hepatic artery are cleared carefully all the way back to coeliac trunk. The gastroduodenal artery is identified, freed and divided between endoclips at the junction which it branches off from common hepatic artery. The pancreas is further mobilized from the superior mesenteric vein. Extreme care should be exercised to control all the branches from the superior mesenteric vein. Once an adequate resection margin is ascertained and superior mesenteric vein and artery are safeguarded by the laparoscopic hand, the uncinata process of pancreas is divided using endo-GIA (3.5 / 60, Autosuture, United States Surgical Corp., Norwalk, CT, USA). The stump is further plicated if any significant bleeding is noted.

#### 5. Reconstruction of Anastomoses

As the hand-port incision is at the right upper quadrant and protected from soiling, it can be used to allow some of the anastomoses to be performed via open method. Our preference is to have both pancreatico-enterostomy and gastro-jejunostomy performed intracorporeally and the hepatico-jejunostomy performed via the hand-port incision using open instruments. First of all, remnant of pancreas is sutured to either the side of jejunal limb or posterior wall of gastric remnant employing "dunking technique". It is basically a matter of choice to choose either jejunum or stomach and we have attempted both of these approaches and do not see any notable difference between them. It is a 2-layered anastomosis using 3 / 0 prolene with the pancreatic remnant invaginated into either the stomach or jejunum. With appropriate use of self-retaining and upper hand retractor, the hepatico-jejunostomy is undertaken through the hand-port wound using continuous stitches of 3 / 0 monocryl. As the gastro-jejunostomy is on the left side of abdomen and intracorporeal anastomosis is relatively straightforward with the use of endostapler (3.5 / 60, Autosuture, United States Surgical Corp., Norwalk, CT, USA), this is usually lastly performed after the reestablishment of pneumoperitoneum.

Tisseel glue (Tisseel Kit, Tisseel, Immuno AG, Vienna, Austria) is then sprayed to all these anastomoses. Two large bore silicon drains are inserted next to the anastomoses. Intact specimen is retrieved via the hand-port using a sterile specimen bag. All the 5 -12 mm ports and the hand-port incision are then closed.

### PYNEH Experience

A total 17 laparoscopic pancreatectomies were attempted in our institution since 1999. There were 11 laparoscopic distal pancreatectomy (1 enucleation) and 6 laparoscopic Whipple.

Of those 11 laparoscopic distal pancreatectomy, indications were cystic neoplasms (n=5), chronic pancreatitis with intrapancreatic pseudocyst (n=1), adenocarcinoma of pancreas (n=1), pseudotumour of

pancreas secondary to perforated posterior gastric ulcer (n=1), pseudopapillary tumour (n=1) and neuroendocrine tumour (n=2). There were 7 female and 4 male with a median age of 55 (range 18 - 79). Three patients had ASA grade 1, 7 patients had ASA grade 2 and 1 patient had ASA grade 3. Total laparoscopic resection was performed in 8 cases and 3 resections were performed using the hand-assisting technique. Among the patients with total laparoscopic resection for cystic neoplasms, 1 patient had both splenic artery and vein successfully preserved. Median operating time was 180 minutes (range 105 - 250) and median blood loss was 100 cc (range 120 - 250). Open conversion was required in a patient with adenocarcinoma of tail of pancreas. The operation could not be safely performed in view of extensive tumour involvement. In addition to the 6 concomitant splenectomies, there were other additional procedures performed together with the distal pancreatectomy including right adrenalectomy for Conn's syndrome (n=1) and marsupialisation for a huge (>10 cm) and symptomatic liver cyst at left lateral segment (n=1). There was also 1 wedge excision of a small gastrointestinal stromal tumour at anterior gastric surface and 1 patient with closure of perforated gastric ulcer, of which the perforated ulcer was thought to be the cause of a pseudotumour formation at the body of pancreas. (Table 1)

In terms of postoperative complications, pancreatic leak occurred in 2 patients (22.2 %) and 2 patients developed intraabdominal collection (22.2 %), all of which settled upon conservative treatment. No hospital mortality was reported in our series. Pathologically, clear resection margin was obtained for all neoplastic cases. Median hospital stay was 7 days (range 4 - 53). No other complication was noted upon a median follow-up of 37 months (range 7 -91). (Table 2)

The 6 laparoscopic Whipple were performed for carcinoma of Ampulla of Vater (n=4), distal cholangiocarcinoma (n=1) and chronic pancreatitis mimicking malignancy (n=1). (Table 1) There were 3 male and 3 female of median age of 71 (range 51 - 75). Two patients had ASA grade 1, 3 patients had ASA grade 2 and 1 patient had ASA grade 3. All resections were performed using hand-assisting technique. Median operating time was 263 minutes (range 240 - 420) and median blood loss was 185 cc (range 100 - 1500). The only open conversion was due to accidental injury of the superior mesenteric vein and ended up with significant intraoperative blood loss of more than 1 litre. The bleeding was temporarily aborted using the laparoscopic hand and finally controlled by open plication (Table 2)

Postoperative complications occurred in 4 patients (66.6 %) which included bile / pancreatic leak in 3 patients (50 %) and 3 patients developed intraabdominal collection (50 %), all of which settled upon conservative treatment. Two patients developed reactionary haemorrhage and 1 was successfully controlled by tranarterial embolisation and the other one developed significant haematoma and required reoperation via the hand-port incision for clot evacuation. One patient discharged on postoperative day 8 and was readmitted a few days later for gastric



outflow obstruction. The complication settled upon conservative measures. No hospital mortality was reported in our series. Pathologically, clear resection margin was obtained for all neoplastic cases. Median hospital stay was 36.5 days (range 8 - 68). No other complication was noted upon a median follow-up of 8 months (4 - 20). (Table 2)

## Discussion

The initial development of laparoscopy in pancreatic surgery is focused mainly on diagnosis and staging purposes.<sup>1-2</sup> The feasibility of palliation for gastric outflow obstruction by laparoscopy is later explored with promising results.<sup>3-5</sup> This minimal access approach is also used to treat patients with pancreatic pseudocyst with impressive outcomes.<sup>19-20</sup> Laparoscopic pancreatectomy can be considered as another breakthrough of therapeutic laparoscopy as a result of technological and skill refinements.

Reports from literature have already confirmed the feasibility of laparoscopic Whipple. However, it is not commonly performed as a result of technical complexity, long operating time and high incidence of postoperative complications.<sup>14-18</sup> On the contrary, the results of laparoscopic distal pancreatectomy or enucleation seem to be much more favourable as reflected by faster recovery time.<sup>6-12</sup> Majority of these are performed for chronic pancreatitis, cystic neoplasm and neuroendocrine tumour. More importantly, it is a simpler operation as tedious lymphatic dissection is not required unlike those frankly malignant cases. Similar to the reported series, retrospective comparative trial of our centre has also shown that this is a safe operation associated with less intraoperative blood loss and possesses the potential to replace the open approach provided that expertise and ancillary set-up are available.<sup>21</sup>

The early results of laparoscopic Whipple did not draw too much attention probably due to the complexity of the operation even when performed in open approach. Important structures like stomach, duodenum, the inferior vena cava and the mesenteric vessels are all crowded together with the tumour. Subsequent meticulous reconstructions again have to be accomplished in such a small space and therefore the procedure would be particularly difficult when performed laparoscopically, and this would mean prolonged operation time and may sometimes produce major intraoperative complications like injuries to neighbouring structures or bleeding. However, with the improvement of instruments, like the stapling devices and ultrasonic dissectors, together with the maturation of skills, we do think the current apparently difficult laparoscopic Whipple could be accomplished much more easier when the "learning curve" problem is overcome.

Insertion of hand can probably increase the safety margin of the operation, but it demands a certain level of skill to co-ordinate the simultaneous movements of hand and laparoscopic instruments. The notable advantages of hand-assisted laparoscopic surgery over total laparoscopic approach are better exposure of

anatomy and blunt dissection is possible with the assistance of the surgeon's hand. In addition, the "laparoscopic hand" can also provide immediate haemostasis and prevent air embolism even if branches of portal vein are severed. Last but not least, if extension of incision is required anyway for retrieval of intact specimen and it is quite reasonable to have it made earlier so as to facilitate dissection as well. Also the subsequent reconstruction of hepatico-jejunostomy, gastro-jejunostomy, and pancreatico-enterostomy anastomoses would be much more easy with the surgeon's hand inside the abdomen. This Gelpport device also allows surgeon to introduce instruments easily and quickly, like gauze or artery forceps, for better control and manipulation. However the main drawback of it is probably the increased risk of needle pick injury. The experience of the well-trained surgeon and the great awareness of the risk would be the only way to minimise it.

Another important concern would be oncological clearance. It is understandable that one may think complex anatomy, together with limited view through the laparoscope may make it difficult to assure the oncological clearance for frank malignancy. However Ammori, Kimura & Dulucq were able to resect the tumours not just to achieve clear margins but also reasonable harvests of lymph nodes in laparoscopic Whipple.<sup>16-18</sup> Again all the resection margins were clear of tumour in our series and indeed extensive lymphadenectomy has not been shown to improve patient survival but associated with increased postoperative complications in randomised controlled trial.<sup>22</sup> Of course, the exact survival benefits could not be accurately assessed because of the limited number of cases and experience at the moment.

In the past, we might think that laparoscopic surgery of such magnitude is not worthwhile because the "access trauma" is comparatively less important when compared to the actual tumour ablation. We do agree that the benefit from minimal access approach would be more pronounced in simpler procedures, such as bypass operations. However, learning from the experience of laparoscopic gastric and colorectal cancer surgery, we know that even for such major resectional procedures, wound-related complication, such as wound infection could be minimised with a smaller wound. This is also true for the pain-related complications, like atelectasis and subsequent chest infection. Postoperative ileus and deep vein thrombosis would also be less common due to earlier mobilisation. We are convinced that all these benefits can also be seen in laparoscopic Whipple once the learning curve is overcome.

## Conclusion

Our results not only confirm the feasibility of laparoscopic pancreatectomy, but also demonstrated the promising results of this approach in selected patients. It should be considered as a favourable treatment option for cystic neoplasm located in body and tail of pancreas. The key to success would begin with careful case selection, proper staging of the disease and last but not least availability of expertise.



Table 1. Types of pathology in both laparoscopic distal pancreatectomy and Whipple

| Pathology (Based on final histology)                          | Laparoscopic distal pancreatectomy (n = 11)   | Laparoscopic Whipple (n = 6) |
|---|---|------------------------------|
| Cystic tumour   | 5 (1 concomitant splenic artery aneurysm, 1 marsupialization of huge liver cyst & 1 wedge excision of gastric stromal tumour) | 0                            |
| Benign neuroendocrine tumour                                  | 2 (1 simultaneous adrenalectomy and enucleation)  | 0                            |
| Pseudopapillary tumour  | 1   | 0                            |
| Pseudotumour of pancreas secondary to perforated peptic ulcer | 1 (1 closure of perforated gastric ulcer)   | 0                            |
| Carcinoma of Ampulla of Water                                 | 0   | 4                            |
| Distal cholangiocarcinoma                                     | 0   | 1 (open conversion)          |
| Adenocarcinoma at tail of pancreas                            | 1 (open conversion)   | 0                            |
| Chronic pancreatitis  | 1   | 1                            |

Table 2 Summary of Patient Demographics undergoing Laparoscopic pancreatectomy

| Parameters                    | Laparoscopic distal pancreatectomy (n = 11) | Laparoscopic Whipple (n = 6)              |
|-------------------------------|---|---|
| Age                           | 55 (18-79)                                  | 71 (51-75)                                |
| Sex                           | 4 M : 7 F                                   | 3 M : 3 F                                 |
| ASA grading                   | ASA 1 (n=3)<br>ASA 2 (n=7)<br>ASA 3 (n=1)   | ASA 1 (n=2)<br>ASA 2 (n=3)<br>ASA 3 (n=1) |
| Operation time (minutes)      | 180 (105-250)                               | 263 (240-420)                             |
| Blood loss (ml)               | 100 (120-250)                               | 185 (100-1500)                            |
| Open conversion               | 1 (9.0 %)                                   | 1 (16.6 %)                                |
| Complications                 | 3 (33.3 %)                                  | 4 (66.6 %)                                |
| • Bile / pancreatic leak      | 2 (22.2 %)                                  | 3 (50.0 %)                                |
| • Collection                  | 2 (22.2 %)                                  | 3 (50.0 %)                                |
| • Bleeding                    | 0 (0 %)                                     | 2 (33.3 %)                                |
| • Gastric outflow obstruction | 0 (0 %)                                     | 1 (16.6 %)                                |
| Mortality                     | 0 (0 %)                                     | 0 (0 %)                                   |
| Hospital stay (days)          | 7 (4-53)                                    | 36.5 (8-68)                               |
| Follow-up (months)            | 37 (7-91)                                   | 8 (4-20)                                  |

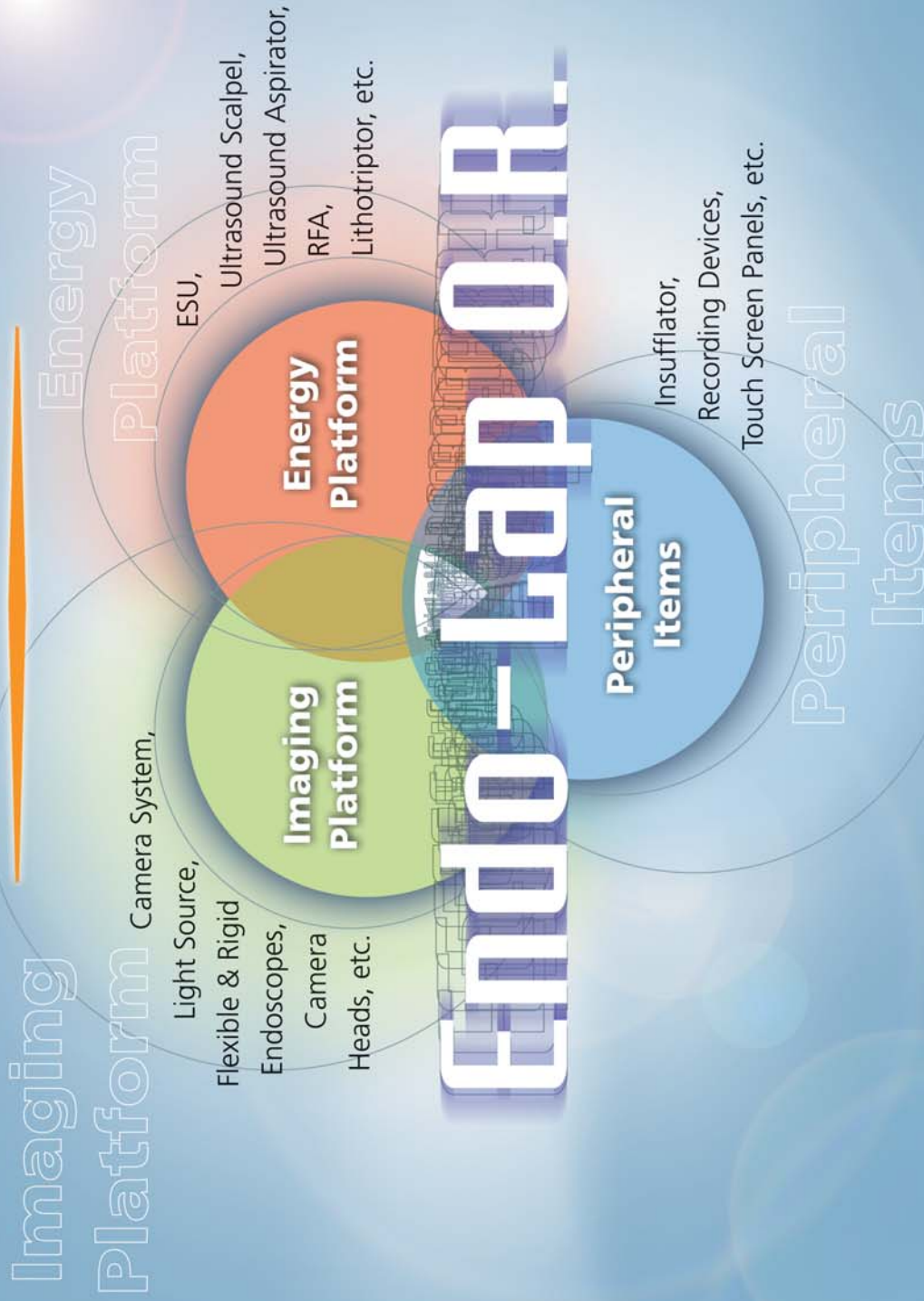
Values are presented as median and range  
Some patients had more than 1 complications

References

- Ishida H  
Peritoneoscopy and pancreas biopsy in the diagnosis of pancreatic disease  
*Gstrointes Endosc* 1983; 29: 211-218.
- Cushieri A  
Laparoscopic surgery of the pancreas  
*J R Coll Surg Edinb* 1994; 39: 178-184.

- Tang CN, Siu WT, Ha JPY, Li MKW  
Endo-laparoscopic approach in the management of obstructive jaundice and malignant gastric outflow obstruction  
*Hepato-Gastroenterology* 2005; 51: 128-124.
- Rhodes M, Nathanson L, Fielding G  
Laparoscopic biliary and gastric bypass: a useful adjunct in the treatment of carcinoma of pancreas  
*Gut* 1995; 36: 778-780.
- Mouiel J, Katkhouda N, White S, Dumas R  
Endo-laparoscopic palliation of pancreatic cancer  
*Surg Laparosc Endosc* 1992; 2: 241-243.
- Gagner M, Pomp A, Herrera MF  
Early experience with laparoscopic resections of islet cell tumours  
*Surgery* 1996; 120: 173-180.
- Dexter SP, Martin IG, Leindler L, Fowler R, McMahon MJ  
Laparoscopic enucleation of a solitary pancreatic insulinoma  
*Surg Endosc* 1999; 13(4): 406-408.
- Lo CY, Chan WF, Lo CM, Fan ST, Tam PK, Fan ST  
Surgical treatment of pancreatic insulinomas in the era of laparoscopy  
*Surg Endosc* 2004; 18(2): 297-302.
- Cuschieri A, Jakimowics JJ, van Spreeuwel J  
Laparoscopic distal 70 % pancreatectomy and splenectomy for chronic pancreatitis  
*Ann Surg* 1996; 223: 280-285.
- Sussman LA, Christie R, Whittle DE  
Laparoscopic excision of distal pancreas including insulinoma  
*Aust N Z J Surg* 1996; 66: 414-416.
- Veizakis A, Davides D, Larvin M, McMahon MJ  
Laparoscopic surgery combined with preservation of the spleen for distal pancreatic tumours  
*Surg Endosc* 1999;13: 26-29.
- Tang CN, Siu WT, Chau CH, Ha JPY, Li MKW  
Laparoscopic pancreatectomy: an initial experience  
*Ann Coll Surg HK* 2001; 5: 158-162.
- Lo CY, Lo CM, Fan ST  
Role of laparoscopic ultrasonography in intraoperative localization of pancreatic insulinoma  
*Surg Endosc* 2000; 14(12): 1131-1135.
- Gagner M, Pomp A  
Laparoscopic pylorus-preserving pancreatoduodenectomy  
*Surg Endosc* 1994; 8: 408-410.
- Jossart GH, Gagner M  
Pancreaticoduodenal resection  
*J Hepatobiliary Pancreat Surg* 2000; 7: 21-27.
- B.J. Ammori  
Laparoscopic hand assisted pancreaticoduodenectomy, Initial UK experience  
*Surg Endosc* 2004; 18: 717-8.
- Yasutoshi Kimura  
Hand-assisted laparoscopic pylorus-preserving pancreaticoduodenectomy for pancreatic head disease.  
*Am J Surg* 2005;189: 734-7.
- Dulucq JL, Wintringer P, mahajna A  
Laparoscopic pancreaticoduodenectomy for benign and malignant diseases  
*Surg Endosc* 2006; 20(7): 1045-50.
- Way LW, Legha P, Mori T  
Laparoscopic pancreatic cystogastrostomy: the first operation in the new field of intraluminal laparoscopic surgery  
*Surg Endosc* 1994; 8: 235-239.
- Trias M, Targaroma EM, Balague C, et al  
Intraluminal stapled laparoscopic cystogastrostomy for the treatment of pancreatic pseudocyst  
*Br J Surg* 1995; 82: 403.
- Tang CN, Tsui KK, Ha JPY, Wong DCT & Li MKW  
Laparoscopic distal pancreatectomy: a comparative study  
*Hepato-Gastroenterology* 2007; 54: 265-271.
- Yeo CJ, Cameron JL, Lillemoe KD, Sohn TA, et al  
Pancreaticoduodenectomy with or without distal gastrectomy and extended retroperitoneal lymphadenectomy for periampullary adenocarcinoma, part2.: randomized controlled trial evaluating survival, morbidity, and mortality.  
*Ann Surg* 2002; 236: 355-368.

# OLYMPUS®



**T r u e l y I n t e g r a t e d S y s t e m**



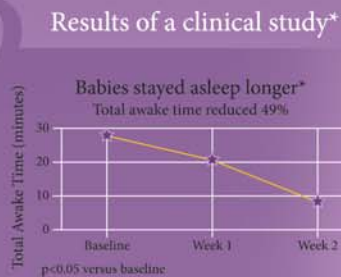
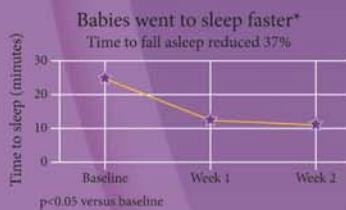*The first and only before-bed routine proven to help baby sleep better*



After mothers used Johnson's baby bath and lotion containing NaturalCalm™ essences in a 3-step nightly routine of a warm bath, gentle massage, and quiet activity:

- Babies went to sleep 37% faster (p<0.05 vs baseline)
- Babies stayed asleep longer, reducing total awake time by 49% (p<0.05 vs baseline)
- Mothers reported a 55% reduction in tension and anxiety, and a 59% reduction in fatigue (p<0.05)

NaturalCalm™ is a unique blend of patent pending essences that have been tested and proven to have relaxing properties.



**Johnson's  
baby**

For detailed clinical reports or samplings, please contact us at 2737 5576.  
For further product information, please visit [www.Johnsonsbaby.com.hk](http://www.Johnsonsbaby.com.hk)

\* Data on file. Johnson & Johnson.





## The Use of Robotic in GI Surgery

**Dr. Wing-tai Siu**

MBChB (CUHK), FRCS Ed (Gen), FCSHK and FHKAM (Surgery)



Dr. Wing-tai Siu

### Background

In the past decade, minimally invasive surgery (MIS) has been proved to be one of the landmark developments in the history of modern surgery. However, its development might be limited by 2-dimensional imaging, unstable camera platform, limited (only 4) instruments' degrees of freedom, and poor ergonomics.<sup>1,2</sup> As the complexity of MIS advances, the demand for better instrumentation and surgical platform has also increased. Advancement in technology and mechanical engineering foster the development of robot-assisted MIS in early 1990s.

The Automated Endoscopic System for Optimum Positioning (AESOP; Computer Motion, Inc., Goleta, CA, USA) was the first voice-activated robotic-arm developed for holding and positioning the laparoscopic camera. Investigators had reported the robotic camera holder could perform with less inadvertent camera motion, less frequent camera removal for cleaning or defogging, and could reduce the operating time and outperformed human camera assistant.<sup>3</sup>

Various integrated master-slave telemanipulative robotic systems were then evolved to fulfil the need for more precise, tremor-free surgical operations.

The Zeus robotic system (computer Motion Inc, Goleta, CA, USA) integrates an AESOP unit for laparoscope positioning and two robotic manipulator arms with a surgeon console equipped with manoeuvring handles and a flat viewing monitor.<sup>4</sup>

The da Vinci<sup>®</sup> Surgical System (Intuitive Surgical, Inc., Sunnyvale, CA) is the most technologically advanced robotic surgical platform available for clinical practice. (Figure 1) The system comprised of three networked components. The surgeon console, which is located remotely from the operating table; the InSite<sup>®</sup> Vision System that provides 3-dimensional imaging, and the patient cart with 3 to 4 robotic arms that control the endoscope and the other 2 to 3 arms carrying interchangeable EndoWrist<sup>®</sup> tools. The surgeon seated at the console controls the robotic arms interchangeable instruments by means of the stereoscopic viewer, hand manipulators and foot pedals. The surgeon's wrist and finger manipulations are transformed, in real-time, to movements of the robotic instruments.

The EndoWrist<sup>®</sup> instruments are unique in possessing a wrist-like mechanism that allows 7-degrees of freedom,

replicating the full range of motion of the surgeon's hand and in turn eliminating the fulcrum effect observed in conventional laparoscopy. (Figure 2)

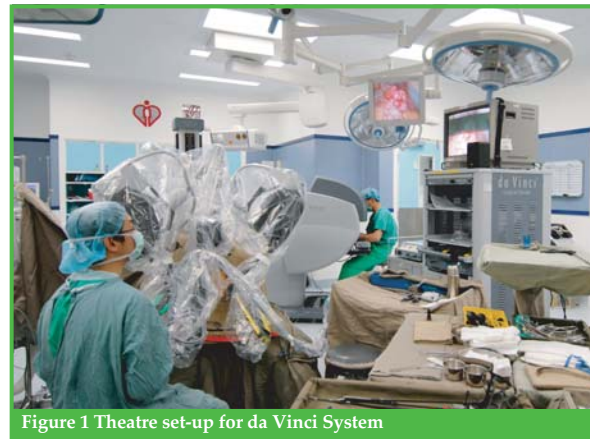

Figure 1 Theatre set-up for da Vinci System




Figure 2 da Vinci EndoWrist<sup>®</sup> instrument with 7 degrees of freedom. These include in-and-out motion, rotation of the shaft, pitch up and down, yaw left and right plus grasp at the tip of the instrument, pitch and yaw at the port site.

### Advantages of Robotic Surgery

An ergonomic user interface, co-axial hand-eye alignment, stereoscopic viewer, instruments with seven degrees of freedom, and elimination of fulcrum effect are features of the da Vinci telemanipulator possess to overcome the limitations of conventional laparoscopy. The surgeon working in the console works in a more ergonomic way than in conventional laparoscopy.<sup>5</sup> Precise fingertip control of the fully articulating EndoWrist<sup>®</sup> instruments allows wrist-like movements that facilitate dissection with



unparalleled dexterity, precision and control.<sup>6</sup> Computer enhancement provides motion scaling and tremour control that further increases accuracy in control.<sup>7</sup> Complex tasks in a confined space, such as suturing and knot tying can be accomplished with great speed and precision, regardless of individual's prior level of experience in laparoscopic surgery.<sup>8</sup> Robotic surgery has also the potential to reduce the learning curve for novice surgeons and improve treatment outcomes for some advanced laparoscopic procedures.<sup>9,10</sup>

### Robotic Gastrointestinal Surgery

Himpens et al reported the first successful robot-assisted laparoscopic cholecystectomy using a prototype of the da Vinci in 1998.<sup>11</sup> The same group also reported the first telerobotic gastric bypass for morbid obesity,<sup>12</sup> and Nissen fundoplication for gastro-oesophageal reflux in 1999.<sup>13</sup>

Over the ensuing years, robotic surgery has been applied to essentially all types of laparoscopic abdominal procedures. Marescaux et al. reported the safety and feasibility of transcontinental robot-assisted remote telesurgery in 2002.<sup>14</sup> Robotic Heller myotomy for achalasia was reported by Melvin et al in 2001.<sup>15</sup> The same group also reported RA distal pancreatectomy and splenectomy for the treatment of pancreatic tail neuroendocrine tumour.<sup>16,17</sup> Ballantyne et al reported their experience of robotic surgery in the management of benign colonic conditions and ventral hernia repair.<sup>18-20</sup> Young et al then demonstrated the feasibility of robotic left adrenalectomy for an incidentaloma.<sup>21</sup> Hashizume et al successfully performed the first gastric devascularisation and splenectomy for portal hypertension.<sup>22</sup> Various investigator had applied robotic surgery in the treatment of a number of oesophageal, gastric and colonic cancers.<sup>23-27</sup>

One study by Cadiere et al evaluated the results of 146 robotic gastrointestinal procedures. There was no robot related morbidity and they found robot to be most suitable for intra-abdominal microsurgery or for manipulations in very small space.<sup>28</sup> Giulianotti et al reported their series of 207 robotic abdominal, thoracic, and vascular procedures in a community hospital.<sup>27</sup> The results suggested robotic surgery is feasible and safe for daily clinical practice.

The Academic Robotics Group reported a series of 211 robotic-assisted operations in 2003.<sup>29</sup> There were 69 antireflux procedures, 36 cholecystomies, 26 Heller myotomies, 17 bowel resections, 15 donor nephrectomies, 7 gastric bypasses, 7 splenectomies, 6 adrenalectomies, 3 exploratory laparoscopies, 4 pyloroplasties, 2 gastrojejunotomies, and one distal pancreatectomy, duodenal polypectomy, oesophagectomy, gastric mass resection, and lysis of adhesion. There were 8 (4%) technical complications that caused only delay in the procedure and 9 (4%) medical or surgical complications, including 1 unrelated death.

Jacobsen et al queried the 11 surgeons across USA currently using the da Vinci system for bariatric surgery. These surgeons reported that robotic-assisted hand-sewn gastrojejunostomy and the jeunojejunostomy was perceived to be technically easier with the robot when compared with standard laparoscopic anastomotic technique.<sup>30</sup>

### Comparative Studies

A retrospective comparison of laparoscopic cholecystectomy (LC) versus robotic cholecystectomy (RC) was performed for 40 patients.<sup>27</sup> The mean operative time of RC (85 minutes) was similar to conventional LC (65 minutes). The conversion rate was higher with LC than RC (3.5% Vs 1.9%). The mean post-operative stay and morbidity rate were comparable in both groups.

Melvin et al prospectively compared 20 robot-assisted procedures with 20 standard laparoscopic antireflux procedures. Outcomes were similar, but operative times were significantly longer in the robotic group.<sup>31</sup>

In a multi-centred study retrospective comparison was studied for robotic-assisted Heller myotomy (59) versus laparoscopic Heller myotomy (62) in the treatment of oesophageal achalasia.<sup>32</sup> Operative time was significantly shorter for the laparoscopic treatment group in the first half of the experience. However, there was no difference in operative time between the groups in the last 30 cases. Oesophageal perforation was more common in the laparoscopic group (16% versus 0%). No oesophageal perforation was found in the robotic group, even in patients who had previous treatment. At short-term follow-up, relief of dysphagia was equally achieved in both groups.

Delaney CP reported a case controlled study of 6 robotic-assisted colorectal procedures (2 right hemicolectomies, 3 sigmoid colectomies, and 1 Wells rectopexy).<sup>33</sup> Safety and feasibility was demonstrated in the robotic group, but operative times were increased in addition to the expenses incurred with the additional instrumentation.

### Limitations of robotic surgery

The extremely high cost required for procurement and maintenance of the system is a distinct disadvantage. The current robotic system is heavy and bulky, and the initial set-up is particularly cumbersome for inexperienced team.

Experiments confirmed force feedback plays a significant role in minimally invasive surgery.<sup>34</sup> The loss of haptic sense in the robotic system remains one of the major limitations of the system.

Da Vinci was originally designed for cardiac operation and later adapted for other surgical procedures. Abdominal operations require extreme operating table positions and wider movement of robotic arms could lead to collisions between the elbows of robotic arms as well as that of assistant.



Procedures like instrument exchange, aspiration and irrigation, clips and endoscopic staplers application cannot be performed by the robot. An experienced assistant is often required to carry out essential procedures on the operating table.

## Discussion

Robotic surgery represents a growing subset of minimally invasive surgery. The da Vinci transcends the limitations of both open surgery and laparoscopy, expanding the surgeon's capabilities and offering a minimally invasive option for many complex procedures. Robotic technology is continually improving, and surgeons using these systems continue to find new applications and improve on conventional laparoscopic techniques.

Various authors had demonstrated the feasibility and safety of various robot-assisted laparoscopic gastrointestinal procedures. Prospective randomised studies are needed to evaluate the cost-effectiveness of robotic surgery versus conventional laparoscopic surgery. It remains to be seen whether robot-assisted laparoscopic surgery can further improve the standard of patient care.<sup>35</sup>

## References

- Sackier JM, Wang Y. Robotically assisted laparoscopic surgery: from concept to development. *Surg Endosc* 1994;8:63-66
- Ballantyne. Robotic surgery, telerobotic surgery, telepresence, and telementoring. Review of early clinical results. *Surg Endosc* 2002;16:1389-1402
- Kavoussi LP, Moore RG, Adams JB, et al. Comparison of robotic versus human laparoscopic camera control. *J Urol* 1994;154:2134-2136
- Sim HG, Yip SK, Cheng CW. Equipment and technology in surgical robotics. *World J Urol* 2006;24(2):128-35
- Hashizume M, Konishi K, Tsutsumi N, Yamaguchi S, Shimabukuro R. A new era of robotic surgery assisted by a computer-enhanced surgical system. *Surgery* 2002;131:S330-333
- Mack MJ. Minimally invasive and robotic surgery. *JAMA* 2001;285(5):568-572
- Cassilly R, Diodato MD, Bottros M, Damiano RJ Jr. Optimizing motion scaling and magnification in robotic surgery. *Surgery* 2004;136:291-294
- Narazaki K, Oleynikov D, Stergiou N. Robotic surgery training and performance: identifying objective variables for quantifying the extent of proficiency. *Surg Endosc* 2006;20(1):96-103
- Narazaki K, Oleynikov D, Stergiou N. Robotic surgery training and performance. Identifying objective variables for quantifying the extent of proficiency. *Surg Endosc* 2006;20:96-103
- Ficarra Vincenzo, Cavalleri S, Novara G, Aragona M, Artibani W. Evidence from robot-assisted laparoscopic radical prostatectomy: a systematic review. *Eur Urol* 2007;51(1):45-55
- Himpens J, Leman G, Cadiere GB. Telesurgical laparoscopic cholecystectomy [letter]. *Surg Endosc* 1998;12:1091
- Cadiere GB, Himpens J, Vertruyen M, Favretti F. The world's first obesity surgery performed by a surgeon at a distance. *Obes Surg* 1999;9:206-9
- Cadiere GB, Himpens J, Vertruyen M, Bruyns J, Fourtanier G. Nissen fundoplication done by remotely controlled robotic technician. *Ann Chir* 1999;53:137-41
- Marescaux J, Leroy J, Rubino F, Smith M, Vix M, Simone M, Mutter D. Transcontinental robot-assisted remote telesurgery: feasibility and potential applications. *Ann Surg* 2002;235(4):487-92
- Melvin WS, Needleman BJ, Krause KR, Wolf RK, Michler RE, Ellison EC. Computer-assisted robotic Heller myotomy: initial case report. *J Laparoendosc Adv Surg Tech* 2001;11:251-3
- Chapman WH III, Albrecht RJ, Kim VB, Young JA, Chitwood WR Jr. Computer-assisted laparoscopic splenectomy with the da Vinci surgical robot. *J Laparoendosc Adv Surg Tech A* 2002;12(3):155-9
- Melvin WS, Needleman BJ, Krause KR, Ellison EC. Robotic resection of pancreatic neuroendocrine tumor. *J Laparoendosc Adv Surg Tech A* 2003;13:33-6
- Ballantyne GH, Merola P, Weber A, Wasielewski A. Robotic solutions to the pitfalls of laparoscopic colectomy. *Osp Ital Chir* 2001;7:405-12.
- Weber PA, Merola S, Wasielewski A, Ballantyne GH. Telerobotic-assisted laparoscopic right and sigmoid colectomies for benign disease. *Dis Colon Rectum* 2002;45:1689-94
- Ballantyne GH, Hourmont K, Wasielewski A. Telerobotic laparoscopic repair of incisional ventral hernias using intraperitoneal prosthetic mesh. *JLS* 2003;7:7-14
- Young JA, Chapman WH III, Kim VB, Albrecht RJ, Ng PC, Nifong LW, et al. Robotic-assisted adrenalectomy for adrenal incidentaloma: case and review of the technique. *Surg Laparosc Endosc Percutan Tech* 2002;12:126-30
- Hashizume M, Konishi K, Tsutsumi N, Yamaguchi S, Shimabukuro R. A new era of robotic surgery assisted by a computer-enhanced surgical system. *Surgery* 2002;131(1 Suppl):S330-3
- Hashizume M, Tsugawa K. Robotic surgery and cancer: the present state, problems, and future vision. *Jpn J Clin Oncol* 2004;34(5):227-237
- Hashizume and co-workers reported the first RA distal gastrectomy for early gastric cancer.
- Hashizume M, Shimada M, Tomikawa M, Ikeda Y, Takahashi I, Abe R, et al. Early experiences of endoscopic procedures in general surgery assisted by a computer-enhanced surgical system. *Surg Endosc* 2002;16:1187-91
- Pigazzi A, Ellenhorn JDI, Ballantyne GH, Paz IB. Robotic-assisted laparoscopic low anterior resection with total mesorectal excision for rectal cancer. *Surg Endosc* 2006;20:1521-1525
- Giulianotti PC, Coratti A, Angelini M, Sbrana F, Cecconi S, Balestracci T, et al. Robotics in general surgery: personal experience in a large community hospital. *Arch Surg* 2003;138:777-84
- Cadiere GB, Himpens J, Gernay O, Izizaw R, Deguelde M, Vandromme J, et al. Feasibility of robotic laparoscopic surgery: 146 cases. *World J Surg* 2001;25:1467-77
- Talamini MA, Chapman S, Horgan S, Melvin WS. A prospective analysis of 211 robotic-assisted surgical procedures. *Surg Endosc* 2003;17:1521-4
- Jacobsen G, Berger, Horgan Santiago. The role of robotic surgery in morbid obesity. *J Laparoendosc Adv Surg Tech A* 2003;13:279-283
- Melvin WS, Needleman BJ, Krause KR, Schneider C, Ellison EC. Computer-enhanced vs. Standard laparoscopic antireflux surgery. *J Gastrointest Surg* 2002;6:11-15
- Horgan S, Galvani C, Gorodner MV, et al. Robotic-assisted Heller myotomy versus laparoscopic Heller myotomy for the treatment of esophageal achalasia: multicenter study. *J Gastrointest Surg* 2005;8:1020-1029
- Delaney CP, Lynch AC, Senagore AJ, et al. Comparison of robotically performed and traditional laparoscopic colorectal surgery. *Dis Colon Rectum* 2003;46:1633-1639
- Tholey G, Desai JP, Castellanos AE. Force feedback plays a significant role in minimally invasive surgery. Results and analysis. *Ann Surg* 2005;241:102-109
- Descazeaud A, Peyromaure M, Zerbib M. Will robotic surgery become the gold standard for radical prostatectomy? *Eur Urol*. 2007 Jan;51(1):9-11



# Pearls and Pitfalls in Laparoscopic Hysterectomy

Dr. Choi-man Yan

MBBS (HK), MRCOG, FHKAM (O&G), FHKCOG  
Resident Consultant in Obstetrics and Gynaecology, Hong Kong Baptist Hospital



Dr. Choi-man Yan

## Introduction

Increasing number of minimally invasive therapies are replacing conventional ones in every field of medical specialties. Laparoscopic hysterectomy (LH) was first performed in 1989<sup>1</sup> and should now be one of the options when the uterus needs to be removed. Demand for LH grows with heightened media publicity and public awareness. In the process of learning to do LH, the gynaecologist should take note of the various pearls and pitfalls.

## Definition of Laparoscopic Hysterectomy (LH)

The following definitions are commonly used:<sup>2</sup>

- (1) Laparoscopically assisted vaginal hysterectomy (LAVH)-a combined laparoscopic and vaginal approach with laparoscopic division of the structures above the uterine artery; the remainder of the procedure is completed vaginally.
- (2) Laparoscopic hysterectomy (LH(a))-a combined laparoscopic and vaginal approach with laparoscopic division of the uterine artery; the remainder of the procedure is completed vaginally.
- (3) Total laparoscopic hysterectomy (TLH)-the operation is preformed entirely laparoscopically.

## Pros and cons of LH

In comparison with the conventional abdominal hysterectomy, LH is associated with small incisions and better cosmetic result, less blood loss, less tissue trauma, less post-operative pain, shorter hospital stay, faster recovery with an earlier return to work and full activity, and fewer post-operative adhesion formation.<sup>3,4</sup> LH also allows better visualisation of the pelvic pathology through magnification and targeted lighting.

However, disadvantages of LH include increase in operating time and cost, longer learning period to develop surgical proficiency and increase in the risk of urinary tract injuries.<sup>3,5</sup>

## Learning to do LH

Training should start with attending post-graduate courses, watching video demonstrations and practising on pelvic simulator, and continue with assisting in LH procedures and operating under supervision. It has

been suggested that 15 to 20 cases of LH performed under supervision are necessary to allow for the encounter of a wide enough variation in pelvic pathologies to capture both the basic surgical technique and other modifications.<sup>6,7</sup> And experience of performing 80 cases of LH is needed to allow the learning process to stabilise and the time curve to reach a plateau.<sup>8,9</sup>

## Set-up in the operating theatre

The laparoscopic team consists of three people. The right-handed surgeon stands at the left side of the patient. The first assistant stands at the right side and holds the camera with his left hand, leaving him another hand for instruments. The second assistant can manipulate the uterus, often this will be the nurse, who is also assisting with the instruments.

Before the operation starts, the bladder should be catheterised. Correct application of the uterine manipulator and vaginal vault delineator is a very important step in LH so as to allow the uterus to be optimally manipulated to facilitate the operative steps, especially, colpotomies.

## Starting the operation

Firstly, the umbilical area should be thoroughly cleaned by everting the whole umbilicus to avoid wound, and worse still, pelvic infection. A cut is made into the depth of the umbilicus. The closed method is usually employed where the Veress needle, which is open to air, is inserted vertically into the intra-umbilical incision and advanced till a double click is felt. The first click is due to the passage through the rectus sheath and the entry of needle tip into the peritoneal cavity produces the second click. Smooth and gradual build-up of CO<sub>2</sub> pneumoperitoneum is an indication of correct positioning of the needle tip. The intra-peritoneal pressure should be built up to 15mmHg before a sharp 10mm trocar is inserted. Alternatively, the umbilical port may be created by the more time consuming open method which reduces the risk of sharp trauma to retroperitoneal vessels and minimises but does not completely obviate the risk of entering the lumen of adherent bowel.<sup>10</sup>

Introduction of the laparoscope is followed by the creation of 5mm side ports in the left paramedian, left lower quadrant and right lower quadrant under direct laparoscopic guidance according to the ultralateral port



siting (Figure 1) advocated by Koh. This allows the upper and forearms to be adducted, the wrists and hand motion to be natural, and the needle-holder to approach tissue in a horizontal plane as in open surgery, totally eliminating the fulcrum effect.<sup>11</sup> Ultra-lateral port placement can also avoid injuries to the inferior and superficial epigastric vessels.

Steepest possible Trendelenburg position is then adopted so that the bowels will fall away from the pelvic organs. A nasogastric tube may be needed to empty the distended stomach.

## Laparoscopic Hysterectomy

The abdomen is explored and, whenever needed, anatomy is restored by adhesiolysis using the ultrasonic scissors. The ureters in the pelvic side wall should always be visualised through the peritoneum by noting the peristalsis before the start of the operation.

Firstly, the lateral attachments of the uterus, the round ligaments, the infundibulopelvic ligaments or the ovarian ligaments and fallopian tubes are desiccated with bipolar forceps at 30W and divided by ultrasonic scissors. Tissue coagulation with ultrasonic instruments occurs with minimal heat at the blades because heat is generated directly in the tissue. The result is minimal tissue damage and no charring or smoke production. However, vessels larger than 3mm cannot be occluded. Bipolar electrocautery is used to desiccate and occlude large vessels and achieve meticulous haemostasis. Sufficient desiccation is indicated by tissue whitening and completion of vapour emission. Though the flow of current is restricted to the volume of tissue between the blades, the potential lateral thermal spread of up to 10mm should be noted so that the adjacent structure like the ureter will not be injured. Brief and intermittent activation of the bipolar electrocautery and constant saline irrigation will reduce the temperature in the tissues and hence decrease the risk of inadvertent thermal injuries. The pedicles should be re-inspected and desiccated further if required before the vessels retract.

The structures to be divided should always be adequately exposed and put under sufficient tension to allow correct entry into the tissue planes. Therefore, the uterus should be manipulated away from the ipsilateral pelvic side-wall. Traction and counter-traction is of utmost importance. Failure to achieve optimal exposure and tension in the structures to be divided is a contra-indication to laparoscopic surgery.

The broad ligaments are then opened by ultrasonic scissors. The loose retroperitoneal areolar tissues should be dissected skillfully by using ultrasonic scissors to expose the uterine vessels. Perfect skeletonisation of the uterine vessels is not required to avoid unnecessary bleeding. Care is taken in opening the posterior leaf of the broad ligament by making sure that the ureter is not involved in the peritoneal layer being cut. Following the opening of the anterior leaf of the broad ligament, the vesical peritoneum is opened with ultrasonic scissors. The bladder is separated from the lower uterine segment and cervix by sharp dissection. The bladder will be more easily dissected by manipulating the uterus more cephalad and posteriorly. Any bleeding should be

quickly controlled with bipolar electrocautery, otherwise it will obscure the operative field. The bladder pillars are desiccated with bipolar forceps first before division.

Before making the anterior and posterior colpotomies, the vaginal occluder is inflated to prevent the loss of pneumoperitoneum. It is of utmost importance that the upper edge of the vaginal delineator is correctly and clearly identified. Monopolar hook at 70W cutting mode is then used to make cuts onto the anterior and posterior vaginal vaults. The cuts should not be oblique or else the bleeding can be profuse and difficult to stop since the raw surface area will be increased and inverted. Bleeding should always be controlled with bipolar electrocautery before proceeding further. Suction is used to keep the operative field clear of fumes. In LH(a) and TLH, the next step is the desiccation and cutting of the uterine vessels at the isthmus level which should be slightly above the level of anterior and posterior colpotomies. Again, the vaginal delineator should be maximally pushed up during this step so that the ureters are at a safe distance away. The uterus will be blanched after both uterine vessels are cut.

## Total Laparoscopic Hysterectomy(TLH)

In TLH, the next step will be lateral colpotomies-desiccation and division of the cardinal-uterosacral complex. This step can sometimes only be achieved without excessive bleeding by proceeding bit by bit. The push-up on the vaginal delineator is particularly helpful when the cardinal-uterosacral complex is thickened and fibrotic. It will be helpful if the lateral colpotomy is first made over the less fibrotic side so that the more thickened and fibrotic side will be put under maximum tension before division. After the uterus is delivered, the vault is closed laparoscopically by intra- or extracorporeal suturing.

## Laparoscopic Hysterectomy (LH(a)) and Laparoscopic Assisted Vaginal Hysterectomy (LAVH)

In LH(a) and LAVH, the vaginal part will start by inserting a right angle retractor into each of the anterior and posterior colpotomies. The circumferential incision around the cervix is completed. The lateral attachments of the uterus, including cardinal and uterosacral ligaments and uterine vessels, are sequentially clamped, cut and ligated. Sometimes, it is easier to leave all the ligation at the end, especially in cases with minimal cervical descent. An alternative method is to ligate the various lateral pedicles with the help of the vaginal suture needle before dividing them.(Figure 2) The use of clamps and needle holder are thus avoided in the narrow vaginal and deep pelvic spaces. After the delivery of the uterus, the full thickness of the vaginal vault is sutured vaginally, taking care to avoid injuring the bladder and rectum.

## Conclusion

In view of the various advantages of LH, it should be on the list of the armaments of the modern-day gynaecologists. However, the pitfalls of doing LH should be remembered so that complications can be avoided.

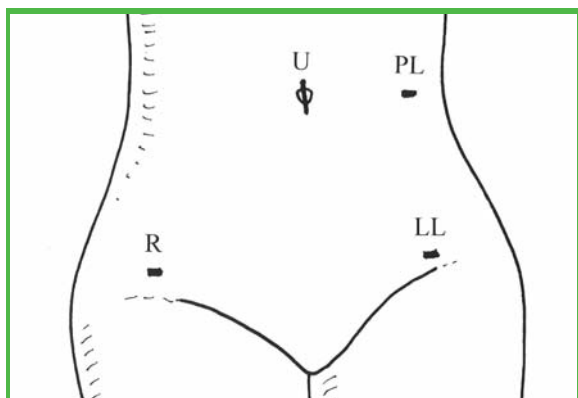


Figure 1. Ultralateral port siting, U-intra-umbilical port; R-right lower port; PL-left paramedian port; LL-left lower port

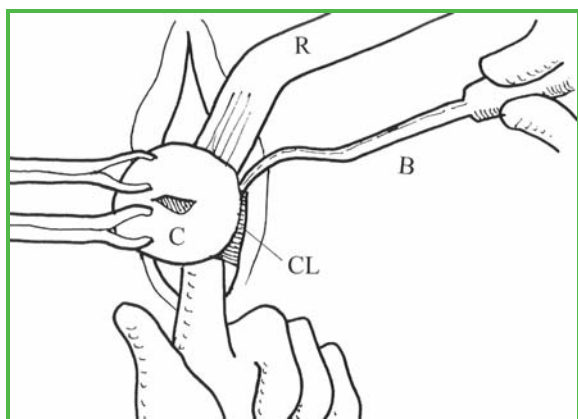


Figure 2. The use of vaginal ligature needle in ligating the left cardinal ligament. R-tissue retractor; B-vaginal ligature needle; C-cervix; CL-cardinal ligament

### References

1. Reich H, DeCaprio J, McGlynn F. Laparoscopic hysterectomy. *JGynecol Surg* 1989;5:213-6.
2. Garry R, Reich H, Liu CY. Laparoscopic hysterectomy-definitions and indications. *Gynaecol Endosc* 1994;3:1-3.
3. Johnson N, Barlow D, Lethabay A, et al. Surgical approach to hysterectomy for benign gynaecological disease. *Cochrane database Syst Rev* 2005 Jan 25;1:CD003677.
4. Wattiez A, Cohen SB, Selvaggi L. Laparoscopic hysterectomy. *Curr Opin Obstet Gynecol* 2002;14:417-22.
5. Meikle SF, Nugent EW, Orleans M. Complications and recovery from laparoscopic assisted vaginal hysterectomy compared with abdominal and vaginal hysterectomy. *Obstet Gynecol* 1997;89:304-11.
6. Shwayder JM. The learning curve for laparoscopically assisted vaginal hysterectomy. *J Am Assoc Gynecol Laparosc* 1994;1(4,Part2):S35.
7. Perino A, Cucinella G, Venezia R, Castelli A, Cittadini E. Total laparoscopic hysterectomy versus total abdominal hysterectomy: an assessment of the learning curve in a prospective randomized study. *Hum Reprod* 1999;14:2996-9.
8. Kreiker GL, Bertoldi A, Larcher JS, et al. Prospective evaluation of the learning curve of laparoscopic assisted vaginal hysterectomy in an University hospital. *J Am Assoc Gynecol Laparosc* 2004;11:229-35.
9. Harkki-Siren P, Sjöberg J. Evaluation of the learning curve of the first one hundred laparoscopic hysterectomies. *Acta Obstet Gynecol Scand* 1995;74:638-41.
10. Bonjer JJ, Hazebroek EJ, Kazemier G, et al. Open versus closed establishment of pneumoperitoneum in laparoscopic surgery. *Br J Surg* 1997;84:599-602.
11. Koh CH. Proficiency in laparoscopic suturing-can it be easily attained? *Newscope* 2005;19:3.

## CALL FOR SUBMISSION OF ARTICLES FOR PUBLICATION IN THE HONG KONG MEDICAL DIARY



The Editorial Board of the Hong Kong Medical Diary invites you to send in your interesting articles for publication in the Hong Kong Medical Diary (500 -1,500 words per article). Abstracts from recent local or international meetings/symposia are also welcome. You can send in your manuscript by facsimile at 2865 0345, through mail or via email at [sue.cheng@fmshk.org](mailto:sue.cheng@fmshk.org). The Editorial Board of the Hong Kong Medical Diary will give you a prompt reply.



## Lifestyle

### Dr. Antonio AT Chuh

MD(HK) FRCP(Edin) FRCP(Irel)

Part-time Associate Professor, Department of Community and Family Medicine, The Chinese University of Hong Kong



Dr. Antonio AT Chuh

### English lyrics for 夜上海

It is no simple task to translate lyrics from Chinese to English. The translator has to synchronise the accents, match the melody, confer meanings in close proximity to the original Chinese lyrics, and rhyme appropriately. In addition, a successful translator delivers the qualitative artistic touches for the piece, radiating passion, scenic beauty, and liveliness. These subjective ingredients render the piece three-dimensional and strike chords in the spirit of the singer as well as the ears and hearts of the audience.

My mother is a retired music mistress. Might I share with music lovers of the Hong Kong Medical Diary her recent translation of the Chinese semi-oldie Shanghai After Dusk. Owing to copyright constraints, we apologise for not being able to publish the original Chinese lyrics in parallel here. The original Chinese lyrics are available at: [www.coolmanmusic.com/male/roman/roman200011.html](http://www.coolmanmusic.com/male/roman/roman200011.html).



### Shanghai After Dusk

English translation by Mrs Chuh Leung Wing Ha  
Teresina 許梁詠霞, mother of Dr. Antonio AT Chuh

1. You and I, love Shanghai. It's a diamond in the sky.  
Lamp lights, brilliant lights, shine through the night.
2. You can see, the street girl, dressing so odd that  
dazzles your eyes.  
She always has, pleasant smile, when she passes by.
3. Wines and dines all the guys, she wastes her youth  
and her life time.  
When dawn comes then, she heaves a sigh. She is so  
tired until the people leave her behind and say to her  
good-bye.
4. It's the time, she must realise. She must change her  
life style.  
Looking for the bright side. Longing for sun-shine.

## Upcoming Certificate Courses of the Federation of Medical Societies of Hong Kong

| Date                      | Course No | Course Name   | Co-organiser                                  | Target Participants              |
|---------------------------|-----------|---|---|----------------------------------|
| 5 Jun 2007 - 17 Jul 2007  | C123      | Certificate Course on Transplantation and Organ Donation                                      | Hong Kong Society of Transplantation          | Non-Medical Health Professionals |
| 3 Oct 2007 - 7 Nov 2007   | C124      | Certificate Course on Infectious Disease  | The Hong Kong Society for Infectious Diseases | Medical & Health Professionals   |
| 8 Oct 2007 - 19 Nov 2007  | C122      | Enhancing Medical Practice: The Role of Psychotherapy in Promoting Physical and Mental Health | Psychotherapy Society of Hong Kong            | Medical & Health Professionals   |
| 20 Oct 2007 - 20 Nov 2007 | C118      | Certificate Course on Ophthalmology   | The Hong Kong Ophthalmological Society        | Medical & Health Professionals   |



# Dermatological Quiz

**Dr. Lai-yin Chong**

MBBS(HK), FRCP(Lond, Edin, Glasg), FHKCP, FHKAM(Med)  
Yaumatei Dermatology Clinic, Social Hygiene Service



Dr. Lai-yin Chong

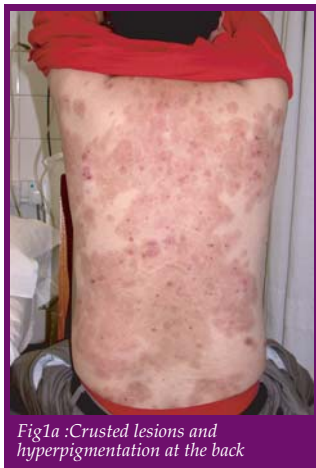

Fig1a :Crusted lesions and hyperpigmentation at the back

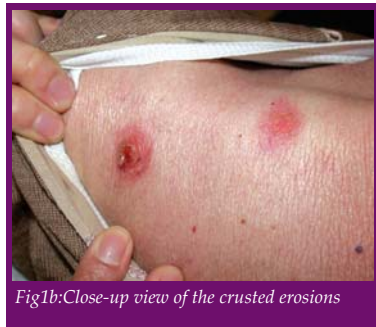

Fig1b:Close-up view of the crusted erosions

A 45-year-old man complained of painful "aphthous ulcer" at gingiva for two months. He was seen by a dentist and diagnosed as having gingivitis. Three months later, he noticed painful weeping skin lesions at his trunk. Past health: he has diabetes mellitus with poor control. On examination, multiple crusted erosions were seen, together with hyperpigmentation at site of some healed areas.

**Questions:**

1. What is your preliminary diagnosis and differential diagnoses?
2. How do you establish the definitive diagnosis?
3. How do you treat this patient, taking account of his past health?

(See P. 31 for answers)



The Federation of Medical Societies of Hong Kong

## Members' Benefits

We are pleased to announce a new benefit for our members. The Federation, in cooperation with Kingsway Concept Limited, will offer a discount on petrol and diesel purchases of HK\$0.9/litre from **Caltex, Shell, Esso and Sinopec** to members and their families of all Ordinary and Associate member societies under the Federation. Please contact our Secretariat at 2527 8898 and [info@fmshk.org](mailto:info@fmshk.org) or Kingsway Concept Limited at 2541 1828 and [kingswayconcept@yahoo.com](mailto:kingswayconcept@yahoo.com) for further details and terms for this offer.





### News from Member Societies:

#### Hong Kong Society of Minimal Access Surgery

New office-bearers for the year 2007-2008 are as follows: President: Dr. SIU Wing-tai, Hon. Secretary: Dr. CHAN C.W. Angus, Council Representative: Dr. SIU Wing-tai.

#### Hong Kong Society of Gastrointestinal Motility Limited

Updated office-bearers for the year 2006-2007 are as follows: President: Dr. YEUNG Yat-wah, Vice President: Dr. LAI Kam-chuen, Hon. Secretary: Dr. CHAN Yiu-kay, Hon. Treasurer: Dr. KWAN C.P. Ambrose.

#### The Obstetrical and Gynaecological Society of Hong Kong

The Obstetrical and Gynaecological Society of Hong Kong held its 24th BGM on 2 May 2007 and the following office bearers were elected: President Dr. LAM Siu Keung, Vice President Dr. LEUNG Kwok Yin, Hon Secretary Dr. AU YEUNG Kam Chuen, Hon Treasurer Dr. K M MOK, Council members: Dr. May CHAN, Dr. Nancy FOK, Dr. TY Leung, Dr. CHAN Kuen Ting, Dr. Wilfred Wong

**The 16<sup>th</sup> Asian Congress of Surgery**, the biennial congress of the Asian Surgical Association (ASA), will be held on 19-22 October 2007 at the Grand Epoch City, Beijing, China, in conjunction with the 3rd Chinese Surgical Week. The Congress is co-organised by the ASA and the Chinese Surgical Society (CSS) of the Chinese Medical Association. Professor Yu-Pei ZHAO, President of the CSS, is the Congress President. For the latest information on the 16th Asian Congress of Surgery, please check out the Association website at [www.AsianSurgAssoc.org](http://www.AsianSurgAssoc.org), which will be updated regularly, or contact the Secretariat by email [info@AsianSurgAssoc.org](mailto:info@AsianSurgAssoc.org) or fax at (852) 2818 1186. We look forward to welcoming you at the Congress!

**The Hong Kong Society of Gastrointestinal Motility** was established by a group of Gastroenterologists in 1998, and was incorporated with limited liability in 2006.

The main objectives of the Society are to promote the study, diagnosis and management of diseases of gastrointestinal motility. Furtherance of the objectives, the Society encourages research, public education, teaching and training of medical practitioners and paramedical personnel on gastrointestinal motility diseases. In addition to annual general meeting and scientific meeting held in the last quarter of each year, scientific symposium and workshop on gastrointestinal motility are organised at different times of the year.

## Answer to Dermatological Quiz

### Answer :

1. The most likely diagnosis judged on clinical ground is pemphigus vulgaris. This autoimmune blistering disease can present with mucosal lesions in the oral cavity, preceding the appearance of skin lesions on the trunk. As the bullae in pemphigus vulgaris are flaccid, often they have already broken before the patient is seen by a doctor. Therefore it usually presents with multiple tender crusted erosions with post-inflammatory hyperpigmentation, rather than the tense, intact and large bullae as seen in bullous pemphigoid. The differential diagnoses include bullous pemphigoid, Stevens-Johnson syndrome, bullous SLE, linear IgA dermatosis, etc.
2. Skin biopsy for histology and direct immunofluorescence test is mandatory for establishment of the definitive diagnosis. Indirect immunofluorescence test to measure the titre of anti-skin antibody is also useful, especially in monitoring the disease activity in pemphigus.
3. Aggressive treatment is necessary for this life-threatening disease. High dose of steroid is usually necessary to control the disease. In view of his poorly controlled diabetes mellitus, a steroid-sparing agent such as azathioprine can be started together with prednisolone right from the beginning, as it usually takes about 3-4 weeks before azathioprine to have effect. In refractory case, pulse therapy with steroid, cyclophosphamide, intravenous immunoglobulin, or plasmapheresis can be used. Treatment for pemphigus is usually life-long.

**Dr. Lai-yin Chong**

MBBS(HK), FRCP(Lond, Edin, Glasg), FHKCP, FHKAM(Med)  
Yaumatei Dermatology Clinic, Social Hygiene Service



| Sunday   | Monday   | Tuesday   | Wednesday   | Thursday   | Friday  | Saturday   |
|--|--|---|---|--|---|--|
| <p>HKMA Structured CME Programme 07/08 (III) - Surgery</p> <p><b>3</b></p> <p>Sports Medicine And Rehabilitation Therapy Convention 2007</p> <p>HKMA Ten-pin Bowling Tournament</p> <p>HKMA Table-Tennis Tournament</p> <p><b>10</b></p> | <p>醫護專業技能提升計劃 1. "醫護護理常用英語初階" (Code No. SUS MH 025 0 (C))</p> <p>"病人安全及急救知識" Code No. SUS MH 004 0 (A)</p> <p><b>4</b></p> <p>醫護專業技能提升計劃 1. "醫護護理常用英語初階" (Code No. SUS MH 025 0 (C))</p> <p>"病人安全及急救知識" Code No. SUS MH 004 0 (A)</p> <p>醫護專業技能提升計劃 1. "醫護護理常用英語初階" (Code No. SUS MH 025 0 (C))</p> <p>"協助病人處理日常生活功能 (ADL)技巧" (Code No. SUS MH 002 0 (A))</p> <p><b>11</b></p> <p>醫護專業技能提升計劃 1. "醫護護理常用英語初階" (Code No. SUS MH 025 0 (C))</p> <p>"協助病人處理日常生活功能 (ADL)技巧" (Code No. SUS MH 002 0 (A))</p> | <p>Certificate Course on Transplantation and Organ Donation</p> <p>EMSHK Officers' Meeting</p> <p><b>5</b></p> <p>Certificate Course on Transplantation and Organ Donation</p> <p>HKMA Newsletter Editorial Meeting</p> <p><b>12</b></p> <p>Tuen Ng Dragon Boat Races</p> | <p>醫護專業技能提升計劃 1. "醫護護理常用英語初階" (Code No. SUS MH 025 0 (C))</p> <p>"病人安全及急救知識" Code No. SUS MH 004 0 (A)</p> <p>健康服務助理員訓練課程 (Code no. TC-HCA-0207)</p> <p><b>6</b></p> <p>健康服務助理員訓練課程 (Code no. TC-HCA-0207)</p> <p>"協助病人處理日常生活功能 (ADL)技巧" (Code No. SUS MH 002 0 (A))</p> <p>醫護專業技能提升計劃 1. "醫護護理常用英語初階" (Code No. SUS MH 025 0 (C))</p> <p>The 21st Congress of International Association of Paediatric Dentistry IAPD</p> <p><b>13</b></p> <p>醫護專業技能提升計劃 1. "醫護護理常用英語初階" (Code No. SUS MH 025 0 (C))</p> <p>"協助病人處理日常生活功能 (ADL)技巧" (Code No. SUS MH 002 0 (A))</p> <p>醫護專業技能提升計劃 1. "醫護護理常用英語初階" (Code No. SUS MH 025 0 (C))</p> <p>"協助病人處理日常生活功能 (ADL)技巧" (Code No. SUS MH 002 0 (A))</p> <p>FMSHK Executive Committee Meeting</p> <p><b>20</b></p> <p>健康服務助理員訓練課程 (Code no. TC-HCA-0207)</p> <p>"協助病人處理日常生活功能 (ADL)技巧" (Code No. SUS MH 002 0 (A))</p> <p>Certificate Course on Quality Management (Code No. TC-CQM-0107)</p> | <p>HKMA Council Meeting</p> <p>Certificate Course in Mentoring in Nursing (Code No. TC-MN-0107)</p> <p>FMSHK Medical &amp; Dental Directory Editorial Board Meeting</p> <p><b>7</b></p> <p>The 21st Congress of International Association of Paediatric Dentistry IAPD</p> <p>HKMA Structured CME Programme with Hong Kong Sanatorium &amp; Hospital Year 2007 (VI) - Persistent Knee Pain: What Else Can We Offer?</p> <p>行政管理興趣小組 "九型人格工作坊" - 病房內外的九型人格 (Code no. SMIG-01-07)</p> <p>Certificate Course in Mentoring in Nursing (Code No. TC-MN-0107)</p> <p><b>14</b></p> | <p>Basic Wound Management (Code No. TC-BWC-0107-CNSG)</p> <p>Basic Wound Management (Code No. TC-BWC-0107-CNSG)</p> <p>健康服務助理員訓練課程 (Code no. TC-HCA-0207)</p> <p><b>8</b></p> <p>Basic Wound Management (Code No. TC-BWC-0107-CNSG)</p> <p>健康服務助理員訓練課程 (Code no. TC-HCA-0207)</p> <p>The 21st Congress of International Association of Paediatric Dentistry IAPD</p> <p>Seventh Refresher Course on Colposcopy</p> <p><b>15</b></p> <p>Basic Wound Management (Code No. TC-BWC-0107-CNSG)</p> <p>健康服務助理員訓練課程 (Code no. TC-HCA-0207)</p> <p>Basic Wound Management (Code No. TC-BWC-0107-CNSG)</p> <p>健康服務助理員訓練課程 (Code no. TC-HCA-0207)</p> <p>Basic Wound Management (Code No. TC-BWC-0107-CNSG)</p> <p>健康服務助理員訓練課程 (Code no. TC-HCA-0207)</p> | <p>"醫院危機處理及職業安全的基本知識" (Code No. SUS MH 003 0 (B))</p> <p>HKMA Refresher Course for Health Care Providers 2006/2007 (X) - Sexually Transmitted Diseases</p> <p>Sports Medicine And Rehabilitation Therapy Convention 2007</p> <p><b>9</b></p> <p>"醫院危機處理及職業安全的基本知識" (Code No. SUS MH 003 0 (B))</p> <p>The 21st Congress of International Association of Paediatric Dentistry IAPD</p> <p>Skin Diseases Conference - Integrating Chinese and Western Medicine</p> <p>臨床專科護理小組 - 專業形象：一切由"新派技巧"開始 (Code no. SCNSG-07-03)</p> <p>Hong Kong International Dragon Boat Races</p> <p><b>23</b></p> |
| <p>Hong Kong International Dragon Boat Races</p> <p>HKMA Structured CME Programme at KWH Year 07/08 (III) - Paediatrics</p> <p>Annual Scientific Meeting 2007</p> <p><b>24</b></p>   | <p>醫護專業技能提升計劃 1. "醫護護理常用英語初階" (Code No. SUS MH 025 0 (C))</p> <p>"協助病人處理日常生活功能 (ADL)技巧" (Code No. SUS MH 002 0 (A))</p> <p>醫護專業技能提升計劃 1. "醫護護理常用英語初階" (Code No. SUS MH 025 0 (C))</p> <p>"協助病人處理日常生活功能 (ADL)技巧" (Code No. SUS MH 002 0 (A))</p> <p>Certificate Course on Quality Management (Code No. TC-CQM-0107)</p> <p>FMSHK Executive Committee Meeting</p> <p><b>21</b></p> <p>健康服務助理員訓練課程 (Code no. TC-HCA-0207)</p> <p>Certificate Course on Mentoring in Nursing (Code No. TC-MN-0107)</p>     | <p>Certificate Course on Transplantation and Organ Donation</p> <p><b>26</b></p>  | <p>健康服務助理員訓練課程 (Code no. TC-HCA-0207)</p> <p>Certificate Course on Quality Management (Code No. TC-CQM-0107)</p> <p><b>27</b></p>   | <p>Certificate Course in Mentoring in Nursing (Code No. TC-MN-0107)</p> <p><b>28</b></p>   | <p>Basic Wound Management (Code No. TC-BWC-0107-CNSG)</p> <p>健康服務助理員訓練課程 (Code no. TC-HCA-0207)</p> <p><b>29</b></p>  | <p>Basic Wound Management (Code No. TC-BWC-0107-CNSG)</p> <p>健康服務助理員訓練課程 (Code no. TC-HCA-0207)</p> <p>Basic Wound Management (Code No. TC-BWC-0107-CNSG)</p> <p>健康服務助理員訓練課程 (Code no. TC-HCA-0207)</p> <p>Basic Wound Management (Code No. TC-BWC-0107-CNSG)</p> <p>健康服務助理員訓練課程 (Code no. TC-HCA-0207)</p> <p>Basic Wound Management (Code No. TC-BWC-0107-CNSG)</p> <p>健康服務助理員訓練課程 (Code no. TC-HCA-0207)</p>  |



| Date / Time  | Function   | Enquiry / Remarks   |
|--|--|---|
| <b>1</b> 6:00 pm - 8:00 pm<br><b>FRI</b> (8,15,22,29)  | <b>Basic Wound Management (Code No. TC-BWC-0107-CNSG)</b><br>Organised by: College of Nursing, Hong Kong   | Secretariat<br>Tel: 2572 9255 Fax: 2838 6280<br>21 CNE Points   |
| <b>3</b> 2:00 pm<br><b>SUN</b>   | <b>HKMA Structured CME Programme 07/08 (III) - Surgery</b><br>Organised by: The Hong Kong Medical Association & Queen Elizabeth Hospital<br>Chairman: Dr. T.C. SHIH Speaker: Various # Lecture Theatre, G/F, Block M, Queen Elizabeth Hospital, Kowloon  | Miss Nina HUNG<br>Tel: 2861 1979<br>(Registration Fee is required)<br>3 CME Points  |
| <b>4</b> 6:30 pm - 9:30 pm<br>(6,11,13,18,20,25)<br><b>MON</b><br>6:00 pm - 10:00 pm<br>(6,11) | <b>"醫療護理常用英語初階" (Code No. SUS MH 025 0 (C))</b><br>Organised by: College of Nursing, Hong Kong   | Secretariat<br>Tel: 2572 9255 Fax: 2838 6280  |
| <b>5</b> 8:00 pm - 10:00pm<br><b>TUE</b> (12,26)   | <b>Certificate Course on Transplantation and Organ Donation</b><br>Organised by: The Federation of Medical Societies of Hong Kong & Hong Kong Society of Transplantation Speaker: Various # 4/F, Duke of Windsor Social Service Building, 15 Hennessy Road, Wanchai, Hong Kong   | Ms. Karen CHU<br>Tel: 2821 3515 Fax: 2865 0345  |
| <b>6</b> 8:30 am - 12:30 pm<br>(8,13,15,20,22,27,29)<br><b>WED</b>                             | <b>健康服務助理員訓練課程 (Code no. TC-HCA-0207)</b><br>Organised by: College of Nursing, Hong Kong   | Secretariat<br>Tel: 2572 9255 Fax: 2838 6280  |
| <b>7</b> 8:00 pm<br><b>THU</b><br>6:30 pm - 9:30 pm<br>(14,21,28)<br>7:00 pm - 8:30pm          | <b>HKMA Council Meeting</b><br>Organised by: The Hong Kong Medical Association # HKMA Head Office, 5/F, Duke of Windsor Social Service Building, 15 Hennessy Road, Wanchai, Hong Kong<br><b>Certificate Course in Mentoring in Nursing (Code No. TC-MN-0107)</b><br>Organised by: College of Nursing, Hong Kong<br><b>FMSHK Medical &amp; Dental Directory Editorial Board Meeting</b><br>Organised by: The Federation of Medical Societies of Hong Kong # Council Chambers, 4/F, Duke of Windsor Social Service Building, 15 Hennessy Road, Wanchai, Hong Kong  | Ms. Christine WONG<br>Tel: 2527 8285<br>Secretariat<br>Tel: 2572 9255 Fax: 2838 6280<br>28.5 CNE Points<br>Ms. Karen Chu<br>Tel: 2821 3515 Fax: 2865 0345   |
| <b>9</b> 9:00 am - 1:00 pm<br>(16)<br><b>SAT</b><br>2:30 pm<br>(14,21,28)<br>(10)              | <b>"醫院危機處理及職業安全的基本知識" (Code No. SUS MH 003 0 (B))</b><br>Organised by: College of Nursing, Hong Kong<br><b>HKMA Refresher Course for Health Care Providers 2006/2007 (X) - Sexually Transmitted Diseases</b><br>Organised by: The Hong Kong Medical Association & Our Lady of Maryknoll Hospital<br>Chairman: Dr. T.C. SHIH Speaker: Various # Training Room II, 1/F, OPD Block, Our Lady of Maryknoll Hospital, 118 Shatin Pass Road, Wong Tai Sin, Kowloon, Hong Kong<br><b>Sports Medicine And Rehabilitation Therapy Convention 2007</b><br>Organised by: CUHK-WHO Collaborating Centre for Sports Medicine and Health Promotion & Asian Federation of Sports Medicine # Postgraduate Education Centre, Prince of Wales Hospital, Shatin | Secretariat<br>Tel: 2572 9255 Fax: 2838 6280<br>Ms. Clara TSANG<br>Tel: 2354 2440<br>2 CME Points<br>Miss Po-ye TONG & Miss Bell CHUNG<br>Tel: 2632 2798, 2646 1477<br>Fax: 2646 3020<br>Email: poyee@ort.cuhk.edu.hk, bellise@ort.cuhk.edu.hk<br>Website: http://www.cuhk.edu.hk/whoctr/smart07/ |
| <b>10</b> 2:00 pm<br><b>SUN</b><br>2:00 pm<br>(17)   | <b>HKMA Ten-pin Bowling Tournament</b><br>Organised by: The Hong Kong Medical Association Chairman: Dr. H YEUNG # South China Athletic Association<br><b>HKMA Table-Tennis Tournament</b><br>Organised by: The Hong Kong Medical Association Chairman: Dr. H YEUNG & Dr. H KOO # Cornwall Street Park  | Ms. Dora HO<br>Tel: 2527 8285<br>Ms. Dora HO<br>Tel: 2527 8285  |
| <b>11</b> 6:00 pm - 10:00 pm<br><b>MON</b>   | <b>"協助病人處理日常生活功能(ADL)技巧" (Code No. SUS MH 002 0 (A))</b><br>Organised by: College of Nursing, Hong Kong  | Secretariat<br>Tel: 2572 9255 Fax: 2838 6280  |
| <b>12</b> 8:00 pm<br><b>TUE</b>  | <b>HKMA Newsletter Editorial Meeting</b><br>Organised by: The Hong Kong Medical Association Chairman: Dr. H.H. TSE # HKMA Head Office, 5/F, Duke of Windsor Social Service Building, 15 Hennessy Road, Wanchai, Hong Kong  | Ms. Tammy TAM<br>Tel: 2527 8941   |
| <b>13</b> (14,15,16,17)<br><b>WED</b>  | <b>The 21<sup>st</sup> Congress of International Association of Paediatric Dentistry IAPD</b><br>Organised by: Hong Kong Society of Paediatric Dentistry # Hong Kong Convention & Exhibition Centre, Wanchai, Hong Kong  | Mr. Daniel CHOK<br>Tel: 2871 8896 Fax: 2871 8898<br>Email: info@iapd2007.com<br>Website: http://www.iapd2007.com  |
| <b>14</b> 2:00 pm<br><b>THU</b><br>6:30 pm - 9:30 pm   | <b>HKMA Structured CME Programme with Hong Kong Sanatorium &amp; Hospital Year 2007 (VI) - Persistent Knee Pain: What Else Can We Offer?</b><br>Organised by: The Hong Kong Medical Association & Hong Kong Sanatorium & Hospital Chairman: Dr. T.C. SHIH Speaker: Dr. WU Wing Cheung Stephen # HKMA Dr. Li Shu Pui Professional Education Centre, 2/F, Chinese Club Building, 21-22 Connaught Road Central, Hong Kong<br><b>行政管理興趣小組"九型人格工作坊"- 病房內外的九型人格 (Code no. SMIG-01-07)</b><br>Organised by: College of Nursing, Hong Kong   | Miss Nina HUNG<br>Tel: 2861 1979<br>(Registration Fee is required)<br>1 CME Point<br>Secretariat<br>Tel: 2572 9255 Fax: 2838 6280<br>3 CNE Points   |
| <b>15</b> 6:30 pm - 8:30 pm<br><b>FRI</b>  | <b>Seventh Refresher Course on Colposcopy</b><br>Organised by: The Hong Kong Society for Colposcopy and Cervical & Pathology Department of O&G UCH and TKOH Chairman: Dr. S.N. HO Speaker: Dr. T.W. LAU & Dr. H.S. CHUNG # Multimedia Conference Room, 2/F, S Block, United Christian Hospital, Kowloon  | Ms. Michelle YEUNG<br>Fax: 3513 5535<br>2 CME Points (HKCOG, HKCPath & HKAM)  |
| <b>16</b> (17)<br><b>SAT</b>   | <b>Skin Diseases Conference - Integrating Chinese and Western Medicine</b><br>Organised by: Hong Kong Association for Integration of Chinese-Western Medicine; Hong Kong Hospital Authority; Guangdong Provincial Association of Traditional Chinese Medicine & Guangdong Provincial Hospital of Traditional Chinese Medicine Speaker: Various # Hong Kong Academy of Medicine, 99 Wong Chuk Hang Road, Aberdeen, Hong Kong  | Conference Secretariat<br>Tel: 2871 8787 / 2871 8841<br>Fax: 2871 8898<br>Email: confdept@hkam.org.hk<br>Website: http://www.hkaim.org.hk/chi/coming.html   |



| Date / Time   | Function  | Enquiry / Remarks  |
|---|---|--|
| <b>16 SAT</b><br>9:30 am - 12:30 pm                             | <b>臨床專科護士小組 - 專業形象：一切由 "演說技巧" 開始 (Code no. SCNSG-07-03)</b><br>Organised by: College of Nursing, Hong Kong  | Secretariat<br>Tel: 2572 9255 Fax: 2838 6280<br>3 CNE Points                       |
| <b>19 TUE</b><br>8:00 am  | <b>Tuen Ng Dragon Boat Races</b><br>Organised by: The Hong Kong Medical Association Chairman: Dr. H YEUNG & Dr. I CHAN # Sai Kung   | Ms. Dora HO<br>Tel: 2527 8285  |
| <b>20 WED</b><br>6:30 pm - 9:30 pm<br>(27)<br>8:00 pm - 10:00pm | <b>Certificate Course on Quality Management (Code No. TC-CQM-0107)</b><br>Organised by: College of Nursing, Hong Kong   | Secretariat<br>Tel: 2572 9255 Fax: 2838 6280<br>35 CNE Points                      |
|   | <b>FMSHK Executive Committee Meeting</b><br>Organised by: The Federation of Medical Societies of Hong Kong # Council Chambers, 4/F, Duke of Windsor Social Service Building, 15 Hennessy Road, Wanchai, Hong Kong   | Ms. Carmen Cheung<br>Tel: 2821 3512 Fax: 2865 0345                                 |
| <b>23 SAT</b><br>(24)   | <b>Hong Kong International Dragon Boat Races</b><br>Organised by: The Hong Kong Medical Association Chairman: Dr. H YEUNG & Dr. I CHAN  | Ms. Dora HO<br>Tel: 2527 8285  |
| <b>24 SUN</b><br>2:00 pm<br>8:15 am - 4:50 pm                   | <b>HKMA Structured CME Programme at KWH Year 07/08 (III) - Paediatrics</b><br>Organised by: The Hong Kong Medical Association & Kwong Wah Hospital Chairman: Dr. T.C. SHIH Speaker: Various # Lecture Theatre, 10/F, Yu Chun Keung Memorial Medical Centre, Kwong Wah Hospital, Kowloon | Miss Nina HUNG<br>Tel: 2861 1979<br>(Registration Fee is required)<br>3 CME Points |
|   | <b>Annual Scientific Meeting 2007</b><br>Organised by: The Hong Kong Society of Dermatology and Venereology Chairman: Dr. HO King Man Speaker: Various # Sheraton Hong Kong Hotel & Towers  | Ms. Candy CHUNG<br>Tel: 2559 5888 Fax: 2559 6910                                   |



Calendar of Events

Meetings

|                                 |   |
|---------------------------------|---|
| 12/7/2007                       | <b>The 1<sup>st</sup> Nursing Forum</b><br>Organised by: Department of Surgery, Li Ka Shing Faculty of Medicine, The University of Hong Kong; American College of Surgeons, Hong Kong Chapter & Department of Nursing Studies, Li Ka Shing Faculty of Medicine, The University of Hong Kong # Underground Lecture Theatre, New Clinical Building, Queen Mary Hospital, Pokfulam, Hong Kong Enquiry: Forum Secretary Tel: 2855 4885 / 2855 4886 Fax: 2819 3416 Email: hksf@hkucc.hku.hk Website: http://www.hku.hk/surgery |
| 12-14/7/2007                    | <b>The 50<sup>th</sup> Hong Kong Surgical Forum</b><br>Organised by: Department of Surgery, Li Ka Shing Faculty of Medicine, The University of Hong Kong & American College of Surgeons, Hong Kong Chapter # Underground Lecture Theatre, New Clinical Building, Queen Mary Hospital, Pokfulam, Hong Kong Enquiry: Forum Secretary Tel: 2855 4885 / 2855 4886 Fax: 2819 3416 Email: hksf@hkucc.hku.hk Website: http://www.hku.hk/surgery  |
| 29/9/2007<br>9:00 am - 6:00 pm  | <b>Health Research Symposium 2007</b><br>Organised by: Health, Welfare and Food Bureau Speaker: Various # Hong Kong Academy of Medicine, 99 Wong Chuk Hang Road, Aberdeen, Hong Kong Enquiry: Ms. Lenora YUNG Tel: 2871 8841 Fax: 2871 8898   |
| 19-22/10/2007                   | <b>16<sup>th</sup> Asian Congress of Surgery &amp; 3rd Chinese Surgical Week</b><br>Organised by: Asian Surgical Association & The Chinese Surgical Society of the Chinese Medical Association # Grand Epoch City, Beijing, China Enquiry: ASA Congress Secretariat Tel: 2855 4235 / 2855 4993 Fax: 2818 1186 Email: info@AsianSurgAssoc.org Website: www.AsianSurgAssoc.org  |
| 20/10/2007<br>1:00 pm - 5:30 pm | <b>The Federation's Annual Scientific Meeting 2007 - Targeted Therapy in Cancer</b><br>Organised by: The Federation of Medical Societies of Hong Kong # M/F, Lecture Theatre, Hospital Authority Building, Kowloon Enquiry: Ms. Karen CHU Tel: 2821 3515 Fax: 2865 0345 Website: www.fmshk.org  |
| 17-18/11/2007                   | <b>Annual Scientific Meeting in Anaesthesiology 2007 - Expanding the Boundaries</b><br>Organised by: The Hong Kong College of Anaesthesiology & The Society of Anaesthetists of Hong Kong # Hong Kong Convention and Exhibition Centre Enquiry: CMPMedica Pacific Limited Tel: 2559 5888 Fax: 2559 6910 Email: meeting.hk@asia.cmpmedica.com Website: www.hkca.edu.hk/asm2007.htm   |

Courses

|   |  |
|---|--|
| 4,11,18,25/7/2007<br>1,8,15,22,29/8/2007<br>5/9/2007  | <b>Certificate Course on Quality Management (Code No. TC-CQM-0107)</b><br>Organised by: College of Nursing, Hong Kong Enquiries: Secretariat Tel: 2572 9255 Fax: 2838 6280   |
| 4,6,11,13,18,20,25,2<br>7/7/2007<br>1,3,8,10,15,17,22,24,<br>29,31/8/2007<br>5,7,12,14,19,21,26,2<br>8/9/2007<br>3,5,10,12,17/10/2007 | <b>健康服務助理員訓練課程 (Code no. TC-HCA-0207)</b><br>Organised by: College of Nursing, Hong Kong Enquiries: Secretariat Tel: 2572 9255 Fax: 2838 6280  |
| 5,12,19,26/7/2007<br>2,9/8/2007<br>6/7/2007   | <b>Certificate Course in Mentoring in Nursing (Code No. TC-MN-0107)</b><br>Organised by: College of Nursing, Hong Kong Enquiries: Secretariat Tel: 2572 9255 Fax: 2838 6280  |
|   | <b>Basic Wound Management (Code No. TC-BWC-0107-CNSG)</b><br>Organised by: College of Nursing, Hong Kong Enquiries: Secretariat Tel: 2572 9255 Fax: 2838 6280  |
| 9,10,11/7/2007  | <b>Definitive Surgical Trauma Care (DSTC) Course</b><br>Organised by: Department of Surgery, Li Ka Shing Faculty of Medicine, University of Hong Kong Medical Centre; Queen Mary Hospital & Hong Kong Chapter of the American College of Surgeons # Skills Development Centre, Department of Surgery, Li Ka Shing Faculty of Medicine, University of Hong Kong Medical Centre, Queen Mary Hospital, Pokfulam, Hong Kong Enquiry: Program Manager Tel: 2855 4885 Fax: 2819 3416 Email: hnsrg@hkucc.hku.hk Website: http://www.hku.hk/surgery      |
| 11,13,18,20,25,27/7<br>/2007<br>1,3,8,10/8/2007   | <b>"醫療護理常用英語進階" (Code No. SUS MH 026 0 (C))</b><br>Organised by: College of Nursing, Hong Kong Enquiries: Secretariat Tel: 2572 9255 Fax: 2838 6280  |
| 24,25,26/8/2007   | <b>Advanced Trauma Life Support (ATLS) Student Course</b><br>Organised by: Department of Surgery, Li Ka Shing Faculty of Medicine, University of Hong Kong Medical Centre; Queen Mary Hospital & Hong Kong Chapter of the American College of Surgeons # Skills Development Centre, Department of Surgery, Li Ka Shing Faculty of Medicine, University of Hong Kong Medical Centre, Queen Mary Hospital, Pokfulam, Hong Kong Enquiry: Program Manager Tel: 2855 4885 Fax: 2819 3416 Email: hnsrg@hkucc.hku.hk Website: http://www.hku.hk/surgery |

CERTIFICATE COURSE FOR NON-MEDICAL HEALTH PROFESSIONALS

## Certificate Course on Transplantation and Organ Donation

器官移植及器官捐贈課程

(Course No. C123)

Jointly organized by



The Federation of Medical Societies of Hong Kong

香港醫學組織聯會

&

Hong Kong Society of Transplantation

香港移植學會

FOR THE FAVOUR OF POSTING

**Objective:** For education of the public on organ transplant and organ donation.

| Date         | Title of Lecture   | Speaker   |
|--------------|--|---|
| Jun 5, 2007  | <b>Renal Transplantation</b><br>腎臟移植   | Dr. Choy Bo Ying, Cindy<br>蔡寶英醫生                                |
| Jun 12, 2007 | <b>Liver Transplantation</b><br>肝臟移植   | Dr. Chan See Ching<br>陳詩正醫生                                     |
| Jun 26, 2007 | <b>Heart Transplantation</b><br>心臟移植<br><b>Lung and Heart-lung Transplantation</b><br>肺移植及心肺移植             | Dr. Chau Mo Chee, Elaine<br>周慕慈醫生<br>Dr. Wong Chi Fong<br>王志方醫生 |
| Jul 3, 2007  | <b>Bone Marrow Transplant for Adults</b><br>骨髓移植漫談<br><b>Bone Marrow Transplant for Children</b><br>兒童骨髓移植 | Dr. Au Wing Yan<br>區永仁醫生<br>Dr. Li Chi Kong<br>李志光醫生            |
| Jul 10, 2007 | <b>Cornea Transplantation</b><br>角膜移植的最新發展   | Dr. Cheng Chak Kwan, Arthur<br>鄭澤鈞醫生                            |
| Jul 17, 2007 | <b>Brain Death and Organ Donation Process</b><br>腦死亡及器官捐贈流程  | Ms. Wong Kar Wai, Angela<br>黃嘉慧女士                               |

Date : June 5, 2007 to July 17, 2007 (Every Tuesday)

Time : 7:00 p.m. – 8:30 p.m.

Venue : Lecture Hall, 4/F, Duke of Windsor Social Service Building, 15 Hennessy Road, Wanchai, Hong Kong

Course Fee: HK\$750 (6 Sessions)

Language : Cantonese (Supplemented with English)

Certificate : Awarded to participants with a minimum attendance of 70%

Enquiry : The Secretariat of the Federation of Medical Societies of Hong Kong

Tel. : 2527 8898 Fax: 2865 0345 Email: [info@fmshk.org](mailto:info@fmshk.org)

CME/CPE Accreditation applied for

For downloading the application form, please refer to our website: <http://www.fmshk.org>



THE FEDERATION OF MEDICAL SOCIETIES OF HONG KONG

香港醫學組織聯合會

Duke of Windsor Social Service Building, 4/F, 15 Hennessy Road, Hong Kong  
Tel: (852) 2527 8898 Fax: (852) 2865 0345 Homepage: www.fmshk.org E-mail: info@fmshk.org

## Application Form for Certificate Course

Name of Applicant:(Prof/Dr./Mr./Ms./Mrs.)\* \_\_\_\_\_ (English) \_\_\_\_\_ (Chinese)

\*Please delete as appropriate

(in block letters)

Correspondence Address: \_\_\_\_\_

Tel. No. : \_\_\_\_\_ Fax No.: \_\_\_\_\_ Age: \_\_\_\_\_ Sex: \_\_\_\_\_

Email Address: \_\_\_\_\_ Occupation: \_\_\_\_\_

Course Title:  Certificate Course on Transplantation and Organ Donation (C123)  
(please tick)

Education :  Secondary  Undergraduate  Postgraduate  Others \_\_\_\_\_  
(please tick)

Fee enclosed (please tick):

Cheque No: \_\_\_\_\_ made payable to **The Federation of Medical Societies of Hong Kong**

Cash HK\$ \_\_\_\_\_

\_\_\_\_\_  
Signature

\_\_\_\_\_  
Date

### Note:

1. The application form together with the appropriate fee should be sent to the Secretariat of the Federation of Medical Societies of Hong Kong, 4/F Duke of Windsor Social Service Building, 15 Hennessy Road, Wanchai, Hong Kong.
2. Fees are not refundable, except in the event of a course being oversubscribed or cancelled.
3. The Federation of Medical Societies of Hong Kong reserves the right to cancel the course should too few participants enroll for the course.
4. No classes will be held when typhoon signal No. 8 or above or black rainstorm warning is still hoisted after 12:00 noon. Please contact the Secretariat at 2527 8898 to enquire matters regarding cancellation of class due to typhoon or black rainstorm.

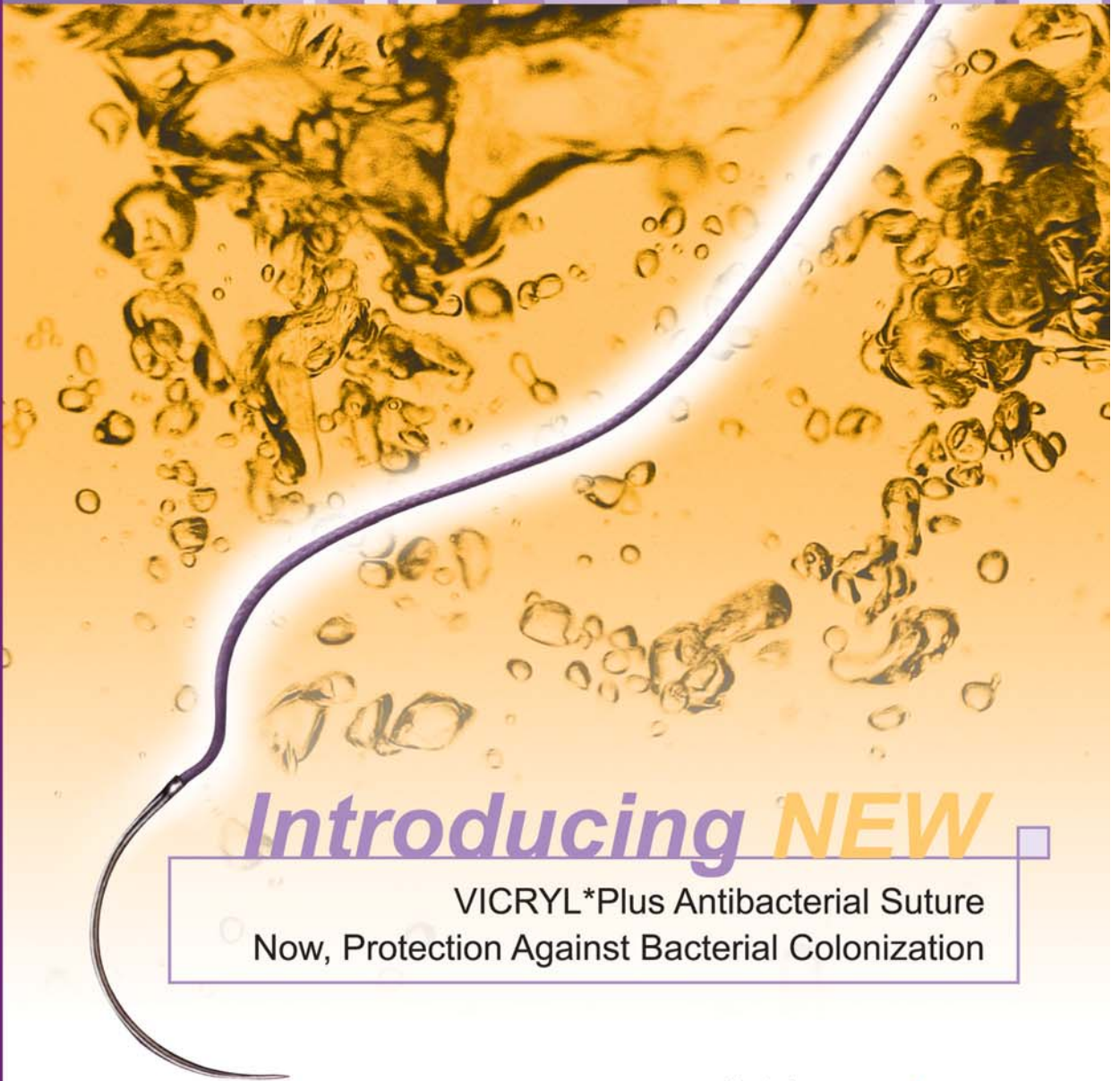### For office use:

Registration confirmed on : \_\_\_\_\_ Registration Number : \_\_\_\_\_

Cheque Issuing Bank : \_\_\_\_\_ Cheque Number: \_\_\_\_\_



# New Revolution of Suture Begins !



*Introducing* **NEW**

VICRYL\*Plus Antibacterial Suture  
Now, Protection Against Bacterial Colonization

**ETHICON**  
a *Johnson & Johnson* company

Coated  
**VICRYL\*Plus**  
**Antibacterial**  
(polyglactin 910) suture  
*Innovation with Every Stitch*  
**Exclusively ETHICON**

# 50<sup>th</sup> Hong Kong Surgical Forum

Thursday to Saturday, 12 - 14 July 2007



## 1<sup>st</sup> Hong Kong Nursing Forum

Thursday, 12 July 2007

### Overseas Speakers:

Jacques Belghiti, *France*  
Kenneth D. Boffard, *South Africa*  
Ara W. Darzi, *United Kingdom*  
Richard J. Finley, *Canada*  
Yuman Fong, *USA*  
Ada S. Hinshaw, *USA*  
John G. Hunter, *USA*  
Jonas T. Johnson, *USA*  
Masaki Kitajima, *Japan*  
Anne Kolbe, *New Zealand*  
Fabrizio Michelassi, *USA*  
Carlos A. Pellegrini, *USA*  
Anne M. Rafferty, *United Kingdom*  
Nathaniel J. Soper, *USA*  
Donald D. Trunkey, *USA*

### Venue :

Underground Lecture Theatre  
Queen Mary Hospital  
Pokfulam, Hong Kong

### Organisers:

Departments of Surgery and Nursing Studies  
Li Ka Shing Faculty of Medicine  
The University of Hong Kong  
*and*  
Hong Kong Chapter  
American College of Surgeons

### Enquiry:

Forum Secretary  
Tel: (852) 2855 4885 / 2855 4886  
Fax: (852) 2819 3416  
E-mail: hksf@hkucc.hku.hk

