




[www.fmshk.org](http://www.fmshk.org)

THE HONG KONG 香港醫訊  
*MEDICAL DIARY*

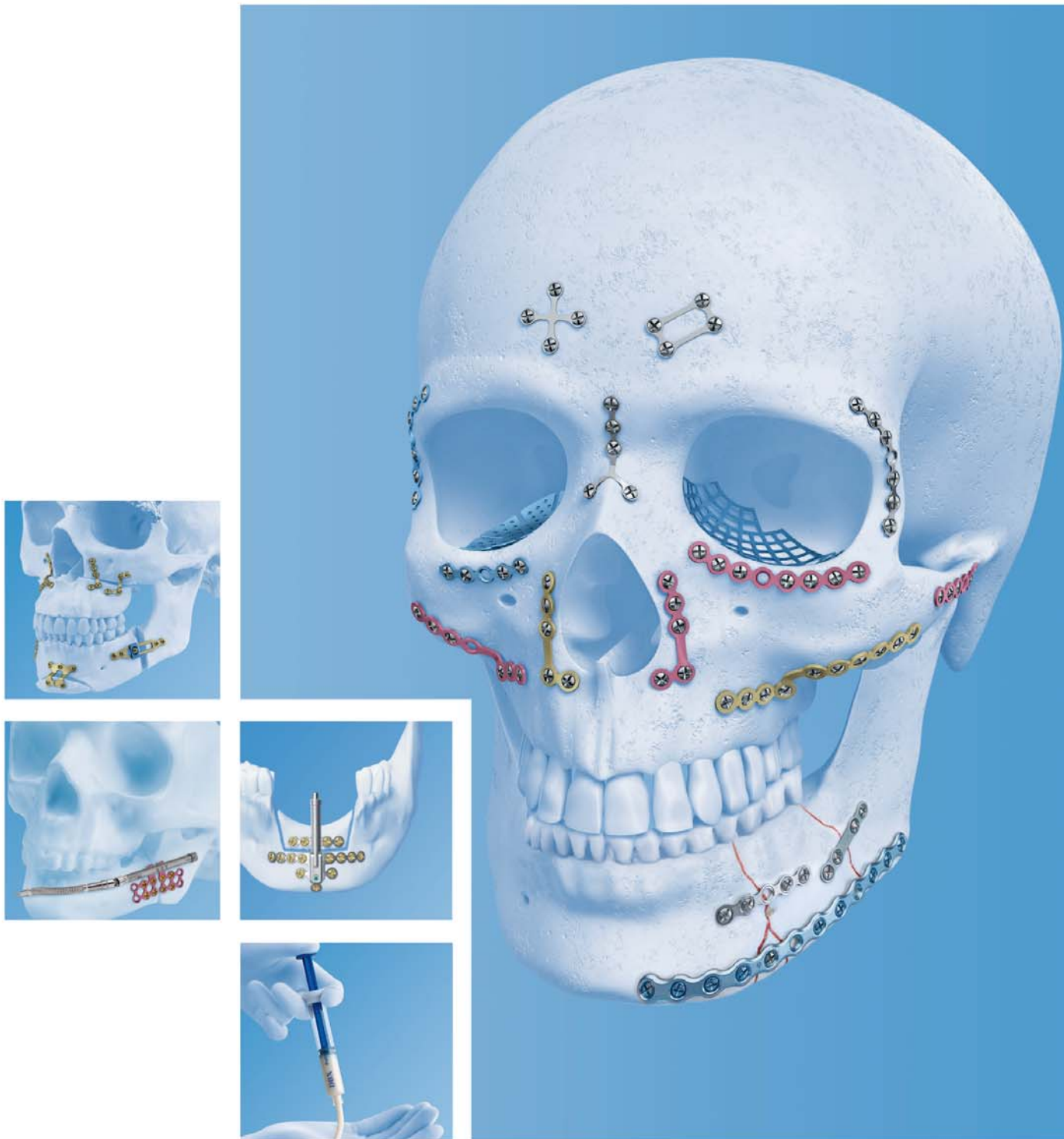VOL.14 NO.6 JUNE 2009



*Oral & Maxillofacial Surgery*

# Synthes Maxillofacial Solutions.

Always a step ahead.



DBX Bone Graft Substitute.



For further information, please contact  
Synthes Hong Kong on 2724 2032 or our  
local representative Ms Carol Kwok on 9880 9279.



## Contents

### Editorial

- Editorial 2  
*Dr. Philip KM LEE*

### Dental Bulletin

- The Modern Specialty of Oral and Maxillofacial Surgery 3  
*Prof. Nabil SAMMAN*
- Overview and Update on Treatment of Common Temporomandibular Joint Disorders 5  
*Dr. Raymond LK CHOW*  
*Dr. Philip KM LEE*
- MCHK CME Programme Self-assessment Questions 8
- The Planning of Orthognathic Surgery - The Digital Era 11  
*Dr. Ben CHOW*  
*Dr. Alfred LAU*
- Manifestations and Management of Oral Complications in Transplant Recipients 17  
*Dr. Antonio TONG*
- Tooth Autotransplantation as a Treatment Option 21  
*Dr. Eddie CK YAU*

### Life Style

- The Mysterious World of Particle Physics 26  
*Dr. Antonio TONG*

### Oral Surgery Quiz

- Oral Surgery Quiz 29  
*Dr. Philip KM LEE*

### Society News

29


### Medical Diary of June

30

### Calendar of Events

- Meetings 32
- Courses 32

## The Cover Shot



### Sound of Silence

I have been deeply immersed in Nature in recent years. To me, seeing and feeling beauty is more vital than any resulting imagery. I am fully aware of the elements of photography - light, composition and emotion.

Some years ago on one of my numerous photography trips in the Mainland, I stayed in a hotel room overlooking a huge lotus pond. Rising very early one morning, I envisioned a dramatic composition of a lotus leaf and a tiny lotus bud in the dark.

I set up my camera and waited patiently. Soft morning light suddenly appeared, which I knew would change subtly and abruptly. There was no time to think and I reacted spontaneously to the scene before me. The light lasted for only one exposure.

The result was the final image of "Sound of Silence", which conveys to me a sense of profound silence and serenity. At the same time, I seem to hear the sound of Nature.



**Dr. Leo K.K. WONG**

MBBS(HK), FCPHK, FRCP,  
Hon.FPSSHK, FPSA, PPSA,  
Hon.FRPS, MFIAP, Hon.EFIAP



**Published by**  
The Federation of Medical Societies of Hong Kong

**EDITOR-IN-CHIEF**

Dr. MOK Chun-on  
莫鎮安醫生

**EDITORS**

Dr. CHAN Chi-fung, Godfrey  
陳志峰醫生 (Paediatrics)  
Dr. CHAN Chun-hon, Edmond  
陳振漢醫生 (General Practice)  
Dr. KING Wing-keung, Walter  
金永強醫生 (Plastic Surgery)  
Dr. YU Kong-san  
俞江山醫生 (Orthopaedics & Traumatology)

**EDITORIAL BOARD**

Dr. CHAN Chi-wai, Angus  
陳志偉醫生 (General Surgery)  
Dr. CHAN, Norman  
陳諾醫生 (Diabetes, Endocrinology & Metabolism)  
Dr. CHIANG Chung-seung  
蔣忠想醫生 (Cardiology)  
Dr. CHIM Chor-sang, James  
詹楚生醫生 (Haematology)  
Dr. CHONG Lai-yin  
莊禮賢醫生 (Dermatology & Venereology)  
Dr. FAN Yiu-wah  
范耀華醫生 (Neurosurgery)  
Dr. FOO Wai-lum, William  
傅惠霖醫生 (Oncology)  
Dr. FONG Ka-yeung  
方嘉揚醫生 (Neurology)  
Prof. HO Pak-leung  
何栢良醫生 (Microbiology)  
Dr. KWOK Po-yin, Samuel  
郭寶賢醫生 (General Surgery)  
Dr. LAI Kei-wai, Christopher  
賴奇偉醫生 (Respiratory Medicine)  
Dr. LAI Sik-to, Thomas  
黎錫滔醫生 (Gastroenterology & Hepatology)  
Dr. LAI Yuk-yau, Timothy  
賴旭佑醫生 (Ophthalmology)  
Dr. LAM Tat-chung, Paul  
林達聰醫生 (Psychiatry)  
Dr. LAM Wai-man, Wendy  
林慧文醫生 (Radiology)  
Dr. LEE Man-piu, Albert  
李文彪醫生 (Dentistry)  
Dr. LO, Richard  
羅光彥醫生 (Urology)  
Dr. LO See-kit, Raymond  
勞思傑醫生 (Geriatric Medicine)  
Dr. MAN Chi-wai  
文志偉醫生 (Urology)  
Dr. MOK, Mo-yin  
莫慕賢醫生 (Rheumatology)  
Dr. TSANG Wai-kay  
曾偉基醫生 (Nephrology)  
Dr. TSE Tak-fu  
謝德富醫生 (Cardiology)  
Prof. WEI I, William  
韋霖醫生 (Otorhinolaryngology)  
Dr. WONG Bun-lap, Bernard  
黃品立醫生 (Cardiology)

**Design and Production**

A-PRO MULTIMEDIA www.apro.com.hk

# Editorial

## Dr. Philip KM LEE

BDS, MDS(OMS), FFDRCSI, FRACDS, FCDShK(OMS), FHKAM(DS)  
Specialist in Oral and Maxillofacial Surgery

**Editor**



Dr. Philip KM LEE

Thank you for the invitation of the editorial board, the Federation of Medical Societies of Hong Kong. I am most honoured to be the editor of this June issue. The theme of this issue of the Medical Diary is Oral and Maxillofacial Surgery.

Special thanks to Dr. Leo K K Wong, our renowned medical colleague for providing the beautiful cover picture. May I also take this opportunity to congratulate Dr. Wong for his recent successful photographic works exhibition with Mr. Chow Yun-fat.

We have a wonderful team of oral and maxillofacial surgeons from both the private and public sectors covering different interesting topics in the field.

The specialty of Oral and Maxillofacial surgery involves surgical management of conditions inside and around the jaw bones and related structures.

Our faces represent our identity as an individual and the anatomy around the oral region forms probably the most sensitive part of our body. Besides organic diseases, psychosomatic disorders occur in this part of the body. Structural derangement of the temporomandibular joints is not common, and very often, psychiatric factors play an important part in the pathophysiology of the disorder. In this global financial crisis, plunging Hang Seng Index, probably we are seeing more and more patients presenting with pain in the temporomandibular joints. Dr. Raymond Chow and I will discuss the various joint disorders and treatments that are available for patients with temporomandibular joint disorders.

Orthognathic surgery aims to correct discrepancy of the facial and jaw skeletons whether developmental or due to other causes. The discrepancy can lead to speech, chewing and airway problems. Besides the esthetic improvement, changing faces with orthognathic surgery benefit patient with dento-facial deformity in all these aspects. The Cone Beam CT with its low radiation dosage and the emergence of powerful computer simulation software revolutionise the process of diagnosis and surgical planning for patients who require orthognathic surgery.

Tooth transplantation has a long history in dentistry. Although nowadays osseointegrated dental implant is becoming more and more popular, tooth transplantation is still a versatile treatment option for our patients, especially those younger ones.

I hope readers will enjoy the articles published in this June issue.



# The Modern Specialty of Oral and Maxillofacial Surgery

## Prof. Nabil SAMMAN

*Professor of Oral and Maxillofacial Surgery, The University of Hong Kong  
President, International Association of Oral and Maxillofacial Surgeons*



Prof. Nabil SAMMAN

Modern day Oral and Maxillofacial Surgery (OMS) is truly a bridge between the medical and dental professions. This is logical since the core remit of the specialty is the comprehensive surgical care of diseases and disorders of the mouth, jaws and associated structures. In the past, maxillofacial surgery was a medical specialty while oral surgery was a dental specialty. However, with the many technological advances and developments, and the ever present ambitious nature of practitioners, the two overlapping specialties emerged to become the currently prevalent specialty of Oral and Maxillofacial Surgery. This occurred mostly through the initial implementation of dual qualifications in medicine and dentistry, followed by specialty training in OMS. This dual training requirement is currently in force in Europe and Australia, but such a requirement is not in place in Asia or Latin America while North America has it as an option for those wishing to pursue sub-specialisation in Head and Neck Oncology and Craniofacial surgery. Training in OMS therefore, depending on where in the world one is, begins after dentistry, after medicine, or after both qualifications. The curriculum which is followed by various countries in their training programmes varies in length, depth and quality leading to significant differences in professional standards worldwide.

The International Association of Oral and Maxillofacial Surgeons (IAOMS) is an umbrella organisation that gathers together over 5000 individual members and 74 national associations (HK being one) in a representation system whereby each affiliated nation nominates one councillor to the governing council of the association. The association functions through an Executive Committee and a Board of Directors, and has an Education Committee, a Research Committee, and an educational Foundation.


Through its education committee, the association has promulgated the International Guidelines on Education and Training in OMS in an effort to assist in harmonising the training standards of OMS around the world. More and more countries are reaching compatibility with the international guidelines. Current efforts are directed at evaluating a possible role for IAOMS in international accreditation or certification. The IAOMS Education Committee sets up educational courses to be given by volunteer teachers free of charge in various parts of the developing world and funded by the IAOMS Foundation. Courses have taken place in Thailand, Indonesia, Peru, Paraguay and Dar el Salaam with the intent of exposing trainees from developing countries to current knowledge and thought and developments in the specialty.

The IAOMS Research Committee is engaged in promoting research within the specialty and has developed various research interest groups (RIG's) to support members across world regions. There are also special interest groups (SIG's) focused on clinical subspecialties with a newly created international training fellowship scheme.


The association further produces a journal which is ranked at the top of the list of journals in the discipline and awards the international conference biennially to a major city in the world. The upcoming 19th International Conference will take place in Shanghai in May 2009 and the Hong Kong Association of OMS is a major player in the organisation of the conference. Every member of the HKAOMS is also a member of the IAOMS thus contributing to the esprit de corps of our specialty worldwide. HKAOMS is rightly proud of its ongoing contribution to the specialty worldwide.

### Nicolet Monitoring System


#### Nicolet Long-Term Epilepsy Monitoring




- Single unit to highly-networked epilepsy lab
- Selective video records user-specified video
- Software-controllable dome camera
- VLink/HL7 compatible



Synchronized Data and Video




Central Monitor provides Four Patient Views



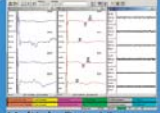
Quickly identify trends in the EEG

---

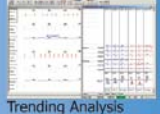
#### Nicolet Endeavor CR Intraoperative Monitoring




- Superior amplifier delivers clean averages in fewer steps
- Trending allows for fast response to clinical changes
- Remote viewing allows experts to see into the OR without entering the OR
- VLink/HL7 compatible




Multiple Data Views



Trending Analysis



Flexible EP Recordings



Distributed by: Neuwake Medical Solutions  
Tel: 2891-2028 Fax: 2891-0119 email: sales@neuwake.com

# TESCO

MAKING YOUR PRACTICE  
PERFECT

**ASTRATECH  
DENTAL**

**OsseoSpeed™ 4.0 S - 6mm**  
Ideal for cases with limited vertical  
bone height

**OsseoSpeed™ 3.0 S**  
A two piece solution for cases with  
limited horizontal space



KaVo. Dental Excellence.

**KaVo ESTETICA® E80**

**An intelligent treatment system of superior  
and attractive ergonomic.**



**Imaging  
Sciences  
International**

**The i-CAT® Cone Beam 3-D Dental Imaging System**

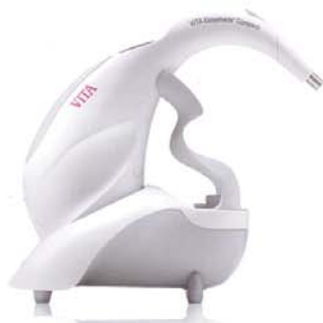**Makes in-office imaging quicker, easier and  
more cost effective with less radiation to  
the patient.**



# VITA

**VITA Easyshade® Compact**

**A new generation of the proven electronic  
measuring system for shade taking in no  
time at all.**





# Overview and Update on Treatment of Common Temporomandibular Joint Disorders

## Dr. Raymond LK CHOW

BDS, MDSHK(OMS), MOS RCS(Edin), FHKAM(DS), FCDSHK(OMS)  
Specialist in Oral and Maxillofacial Surgery

## Dr. Philip KM LEE

BDS, MDS(OMS), FFDRCSI, FRACDS, FCDSHK(OMS), FHKAM(DS)  
Specialist in Oral and Maxillofacial Surgery



Dr. Raymond LK CHOW

Dr. Philip KM LEE

*This article has been selected by the Editorial Board of the Hong Kong Medical Diary for participants in the CME programme of the Medical Council of Hong Kong (MCHK) to complete the following self-assessment questions in order to be awarded one CME credit under the programme upon returning the completed answer sheet to the Federation Secretariat on or before 30 June 2009. One Credit will be awarded for the Dental Council of Hong Kong's CPD Program for Practising Dentists and one credit under the CDSHK CME Program (both subject to approval).*

## Introduction

Temporomandibular joint disorder (TMD) is one of the most common causes in patients presented with orofacial pain<sup>1</sup> (Jin et al 2004). In Hong Kong, 33% of the population reported to have jaw pain, and 5% of these patients actually had frequent pain with moderate to severe degree<sup>2</sup> (Pow et al 2001). These symptoms can be very debilitating which are not only affecting the patients physically but also psychologically. One study showed that 39.8% of TMD patients experienced moderate to severe depression, and psychosocial dysfunction was observed in 4.2% of the patients<sup>3</sup> (Yap et al 2003). The most common disease entities of TMD are 1) Myofascial pain, 2) Internal derangement and 3) Degenerative arthritis.

The muscles of mastication (temporalis, masseter, lateral and medial pterygoid) are responsible in myofascial pain. Micro- (e.g. bruxism) or macro-traumas (e.g. local trauma) to the muscles are thought to be the causes and resulted in painful myositis. Sometimes emotional stress and tension could cause and worsen the pain.

Internal derangement involved the actual joint apparatus. It usually presents with forward displacement of the articular cartilaginous disc overlying the condyle of the temporomandibular joint (TMJ). The two common clinical entities are 1) Disc displacement with reduction and 2) Disc displacement without reduction.

The study by Yap<sup>3</sup> has shown that muscle disorders (myofascial pain) were found in 31.4% of the TMD patients; disc displacement disorders (internal derangement) were found in 15% and arthritis were found in 13% of the patients.

## Myofascial Pain

It is the most common type of TMD, which is predominant in females with a mean age around 33 years old. Masseter muscles are frequently involved and followed by the temporalis. Pain usually located on the cheek areas, and is elicited on eating, or during mouth opening. The muscles are tender when palpated, especially on the trigger point. Mouth opening could be

normal or limited (due to muscle spasm). The pain also can radiate as headache, neck, shoulder and even back pain. These symptoms often improve without treatment in weeks to months. However, some individuals will experience an increase in symptom severity, and may develop long-term chronic jaw pain.

## Classical Treatment for Myofascial Pain

- Educate the patient on muscle fatigue and spasm as the cause of pain and dysfunction.
- Emphasise on the avoidance of clenching and grinding.
- Institute soft diet; avoid hard food and chewing gum.
- Apply moist heat to increase the circulation around tense jaw muscles.
- Isometric jaw exercise.
- Use of oral appliance (splint), to prevent muscle overuse, especially for bruxers.
- Analgesics such as NSAID.
- Muscle relaxants (valium).
- Refer patient for psychological counselling to identify stresses.

## New Treatment for Myofascial Pain - Botulinum Toxin-A (BTX-A) Injection

Most of the cases of myofascial pain can be managed by the atraumatic/conservative treatment mentioned above. However, there are still a small number of refractory cases with no improvement at all. These patients are very difficult to handle both physically and psychologically. Traditional muscle relaxants and NSAID therapy can have serious and unwanted side effects unacceptable to the patients. BTX-A injection offers an alternative for those who have failed in conservative treatment and has shown promising results in myofascial pain patients<sup>4</sup>. Its efficacy has also been studied, and reported that there was remarkable improvement observed in bruxers with myofascial pain<sup>5</sup> (Guarda-Nardini L 2008).

Kurtoglu and his colleagues<sup>6</sup> evaluated the effects of BTX-A injection in a group of non-bruxers with myofascial pain. Pain intensity and electromyography were measured. The results revealed a significant reduction in pain as well as improvement in patients'



psychological status. The only side effect was decrease in the action potential of the masseter muscles, which means the masticatory forces were reduced. However, this effect is usually temporary.

## Internal Derangement

Internal derangement is characterised by a progressive anterior disc displacement. It is often associated with a capsulitis, making pain a common feature.

### Pathogenesis

Nitzan et al.<sup>7</sup> proposed that there was a reversible restriction in gliding movements of the disc caused by its adherence to the fossa. Such adherence may arise from a number of possible causes such as fibrous adhesions, severe friction between damaged rough surfaces, stickiness that may be a direct result of an increase in synovial fluid viscosity, or a vacuum effect. A vacuum effect or alteration in synovial fluid consistency may create the environment for a suction effect of the disc to the fossa, restricting gliding movements and therefore resulting in displacement of the disc.

### 1) Disc Displacement with Reduction (DDWR)

DDWR derangement could be found with a clicking sound over the joint without associated pain. It is seen in over 50% of normal subjects. However, there is another type of DDWR derangement which has clicking of the joint associated with pain. The clicking is due to the noise the condyle makes as it moves under the anteriorly displaced disc. The pain is due to the stretching and subsequent inflammation of the retrodisc pad.

### 2) Disc Displacement without Reduction (DDWOR)

It is characterised with a persistent closed lock. The closed lock is due to the inability of the condyle to slide under the anteriorly displaced disc. Hence, there is usually no associated click or pop on physical exam and mouth opening is limited.

## Classical Treatment for Internal Derangement

DDWR without pain often requires no intervention, and treatment for the painful type of DDWR and DDWOR is similar to those in myofascial pain. Instruction of a soft diet and jaw rest is given as is the prescription of NSAIDs and muscle relaxants (valium). Failure of these methods requires the addition of a splint to attempt to reposition the condyle. The purpose is to reposition the condyle into a more favourable position related to the disc. Clicking is usually not eliminated, but it may be reduced to a soft pop with reduced pain. If repositioning with a splint fails, arthroscopic or open surgical repair is recommended. The purpose of these procedures is to surgically remove adhesions and to reposition the disc into a favourable position.

## New Treatment for Internal Derangement - Sodium Hyaluronic Acid Injection

Open joint surgery to reposition the displaced disc was

always the choice in the past when conservative approaches failed. However, morbidity to the facial nerve and recurrence of the disc displacement were frequently observed. In addition, the focus was shifted from a disc displacement theory (Nitzan et al.) to more emphases on the biochemical causes. The inflammatory mediators such as cytokines, interleukin 6 were found responsible for the pain inside the joint<sup>8,9</sup>. The idea of using high molecular weight hyaluronic acid for intra-articular injection was borrowed from the orthopaedics, and which showed promising results in treating TMJ pain with no additional morbidity<sup>10,11</sup>.

In a case series, 27 local Chinese patients with non-reduced disc displacement were treated with articular injection of sodium hyaluronate. The solution was mainly injected into the superior joint space (space between the articular disc and the glenoid fossa of the skull). There are a total of 34 injection sites in 27 patients. The age range was from 21 to 63 years, with a mean of 39.3 years. Two cycles of injections of high molecular weight sodium hyaluronate were performed in alternative weeks. Pain intensity was measured by the visual analog scale. Maximal mouth opening, clicking joint noise, and lateral movement were measured before and after injections for more than 6 months. The mean pain intensity decreased from 4.2 pre-operatively to 2.6 six months after the injections, and this change was statistically significant.

Besides reduction in pain, significant improvement in the maximum mouth opening was also observed. In conclusion, this intra-articular injection using high molecular weight sodium hyaluronate looks very positive for patients affected by non-reduced disc displacement and is encouraged to be used as a primary treatment to replace the open joint surgery<sup>12</sup>.

## Degenerative Arthritis

Degenerative arthritis can be either primary or secondary. Primary disease is seen in old people and is a disease of wear and tear. Patients are usually asymptomatic, and when symptomatic, the complaints are usually mild. Secondary degenerative arthritis occurs secondary to trauma or chronic bruxism. It occurs in younger people and the symptoms are much more severe. Radiographic findings consist of a primarily unilateral lipping of the joint with osteophyte formation or erosion and flattening of the articular surface of the condyle.

## Treatment for Degenerative Arthritis

Treatment of degenerative arthritis is similar to that of myofascial disorders and early internal derangements. NSAIDs and muscle relaxants with a soft diet are the primary treatment. Bite appliances are added as necessary. When conservative medical management fails to improve symptoms after a 3-6 month trial, surgery is considered. Surgical intervention includes removal of any surgical capsular abnormality, including osteophytes, until the joint space is smooth. A condylar shave is a procedure, which means removing the entire cortical plate, this is not routinely performed as resorption of condyle is a known complication.





## Image-guided Hyaluronate Injection in TMJ Inferior Joint for Degenerative Arthritis

### Case Report

A 18-year-old lady with history of chronic right TMJ pain and limited mouth opening, was prescribed with conservative treatment by her dentist for at least 9 months. However, no improvement of symptoms was seen. She was subsequently referred to our centre for further management. Clinical examination revealed pain on the right pre-auricular region in maximal mouth opening; there was no clicking on both joints. Maximal mouth opening was 22mm. No muscle tenderness was noted and thus myofascial pain was excluded. Magnetic resonance imaging (MRI) was performed to confirm the diagnosis of the degenerative arthritis in the right TMJ. The MRI image showed flattening of the condylar head of the right TMJ with no disc displacement (Fig.1). After confirming the diagnosis, treatment options were discussed with the patient. However, there were not many alternatives in this case as she had gone through a long period of conservative treatment including the use of oral appliance. The only choice was open joint surgery, but the patient was very reluctant to this option. Finally, intra-articular injection using hyaluronate was proposed and the patient agreed.

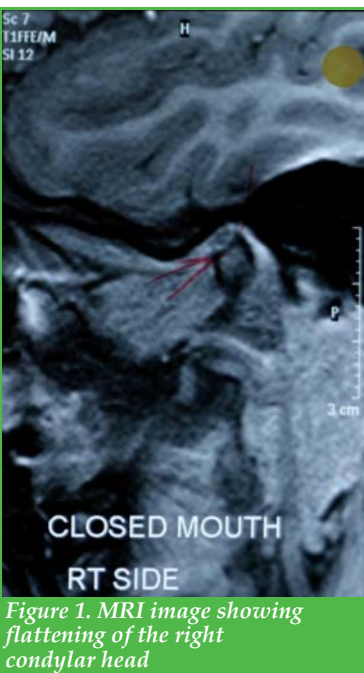


Figure 1. MRI image showing flattening of the right condylar head

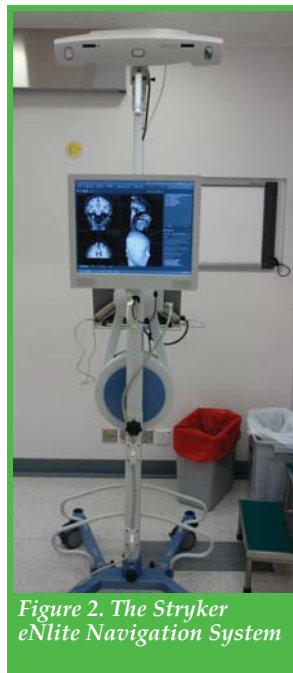

Figure 2. The Stryker eNlite Navigation System

In our previous experience, we have injected hyaluronate into the superior joint space to treat the non-reduced disc displacement, which was relatively easier to access as the superior joint space is bigger in volume. However, in this case the disease involved the condylar head, which was the inferior joint space. The accessibility of the inferior joint space was much more difficult. Thus we decided to use the image-guided technique to assist the injection. The navigation machine we used was the eNlite Navigation System from Stryker (Fig 2). MRI data were then imported into the navigation system and a 3-dimensional image of the patient was reconstructed (Fig 3). Preoperative planning of the entry point of the needle, needle pathway and

target point could be achieved on the 3D image using the designated software.

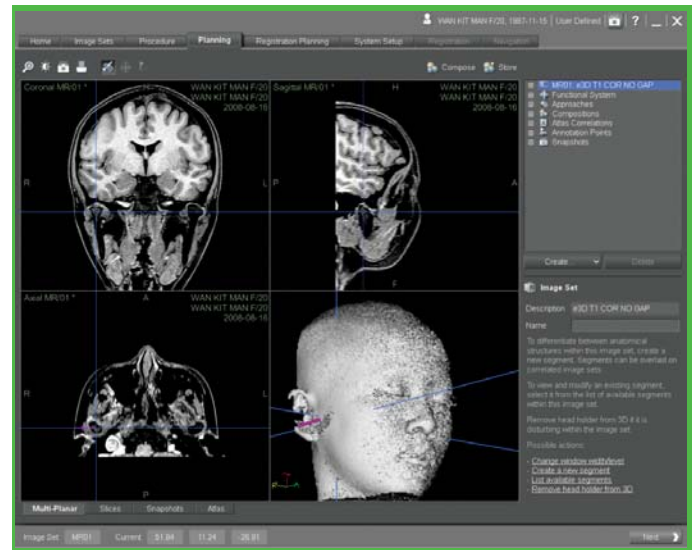


Figure 3. Reconstructed 3D image for MRI Data

Intra-operatively, the patient was prepared by placing the sensors on her head for calibration of the position of the needle (Fig 4). The solution we used was hyalgan (sodium hyaluronate, Fig 5). The injection was carried out under intravenous sedation to prevent unnecessary movement of the patient. After calibration of the needle, the injection began with inserting the needle in the pre-determined entry point and the monitor on the computer showed the real-time position of the needle until the target point is reached (Fig 6 &7). The hyaluronate solution was injected into the joint until a resistance and rebound of the needle was seen. A total of 1.5ml solution was injected.

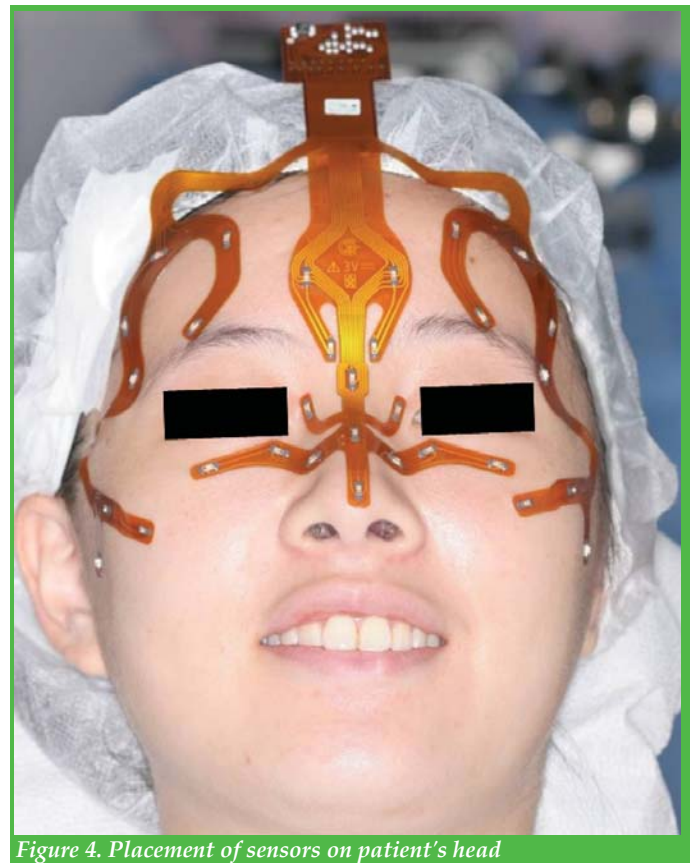


Figure 4. Placement of sensors on patient's head

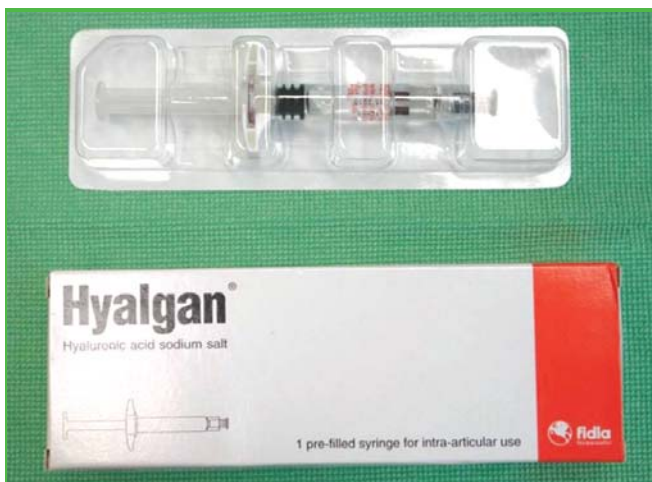

Figure 5. Sodium hyaluronate (Hyalgan)

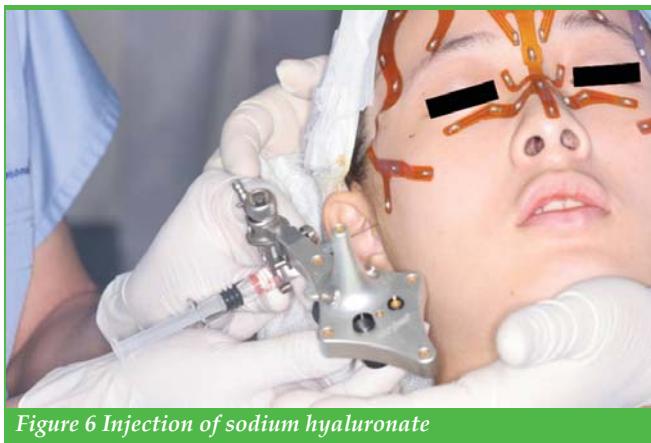

Figure 6 Injection of sodium hyaluronate

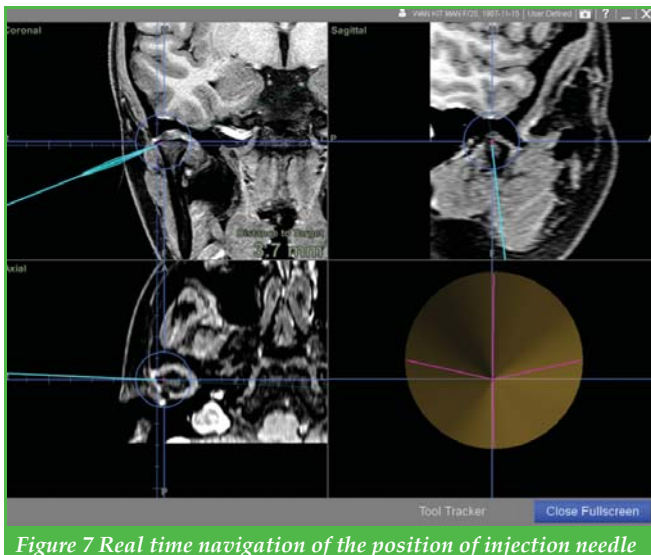


Figure 7 Real time navigation of the position of injection needle

Post-operative 1 week review showed minimal swelling and pain on the injection wound, and no abnormal feeling at the joint by the patient. At 6 month post-op, the pain intensity (VAS) decreased from 7 to 4 according to the patient, and maximal mouth opening increased from 22mm to 34mm. She was able to eat with lesser pain than previously. In conclusion, injection into the inferior joint space is feasible with the assistance of image-guided technique, and the hyaluronic acid seems effective in treating pain elicited by arthritis. However, further studies should be carried out, so that the effect can be evaluated thoroughly.

## References

1. Jin WC, Jae HK, Hyun DK, Hong SK, Young KK, Sung CC. Chronic orofacial pain among Korean elders: Prevalence and impact using the graded chronic pain scale. *Pain*. 2004; 112(1-2):164-170
2. Pow EH, Leung KC, McMillan AS. Prevalence of symptoms associated with temporomandibular disorders in Hong Kong Chinese. *J Orofac Pain*. 2001;15(3):228-34.
3. Yap AU, Dworkin SF, Chua EK, List T, Tan KB, Tan HH. Prevalence of temporomandibular disorder subtypes, psychologic distress, and psychosocial dysfunction in Asian patients. *J Orofac Pain*. 2003;17(1):21-8
4. Kin Man Philip Lee, J Chow, E Hui, W Li. Botulinum Toxin Type A Injection for the Management of Myofascial Temporomandibular Pain Disorder. *Asian J Oral Maxillofac Surg* 2005;17(2):100-103.
5. Guarda-Nardini L, Manfredini D, Salamone M, Salmaso L, Tonello S, Ferronato G. Efficacy of botulinum toxin in treating myofascial pain in bruxers: a controlled placebo pilot study. *Cranio*. 2008;26(2):126-35
6. Kurtoglu C, Gur OH, Kurkcu M, Sertdemir Y, Guler-Uysal F, Uysal H. Effect of botulinum toxin-A in myofascial pain patients with or without functional disc displacement. *J Oral Maxillofac Surg*. 2008;66(8):1644-51.
7. Nitzan DW, Dolwick WF. An alternative explanation for the genesis of closed lock symptoms in the internal derangement process. *J Oral Maxillofac Surg* 1991;49:810-5.
8. Nishimura M, Segami N, Kaneyama K, Sato J, Fujimura K. Comparison of cytokine level in synovial fluid between successful and unsuccessful cases in arthrocentesis of the temporomandibular joint. *J Oral Maxillofac Surg* 2004;62(3):284-7; discussion 287-8.
9. Sato J, Segami N, Nishimura M, Demura N, Yoshimura H, Yoshitake Y, et al. Expression of interleukin 6 in synovial tissues in patients with internal derangement of the temporomandibular joint. *Br J Oral Maxillofac Surg* 2003;41(2):95-101.
10. Kopp S, Wenneberg B, Haraldson T, Carlsson G. The short term effect of intra-articular injections of sodium hyaluronate and corticosteroids on temporomandibular joint pain and dysfunction. *J Oral Maxillofac Surg* 1985;43:429-35.
11. Kopp S, Carlsson G, Haraldson T, Wenneberg B. Long-term effect of intra-articular injections of sodium hyaluronate and corticosteroid on temporomandibular joint arthritis. *J Oral Maxillofac Surg* 1987;45:929-35.
12. Yeung WK, Chow LK, Samman N, Chiu K. Short-term therapeutic outcome of intra-articular high molecular weight hyaluronic acid injection for nonreducing disc displacement of the temporomandibular. *Oral Surg Oral Med Oral Pathol Oral Radiol Endod* 2006;102:453-61

## CPD / CME Programme Self-assessment Questions

Please read the article entitled "Overview and Update on Treatment of Common Temporomandibular Joint Disorders" by Dr. Raymond LK CHOW and Dr. Philip KM LEE and complete the following self-assessment questions. Participants in the MCHK CME Programme will be awarded 1 CME credit under the Programme for returning completed answer sheets via fax (2865 0345) or by mail to the Federation Secretariat on or before 30 June 2009. One Credit will be awarded for the Dental Council of Hong Kong's CPD Program for Practising Dentists and one credit under the CDSHK CME Program (both subject to approval). Answers to questions will be provided in the next issue of The Hong Kong Medical Diary.

Questions 1-10: Please answer T (true) or F (false)

1. The most common temporomandibular joint disorder is degenerative arthritis.
2. The most common clinical entities found in internal derangement of the temporomandibular joint are a) Disc displacement with reduction and b) Disc displacement without reduction.



3. One of the symptoms in Myofascial Pain Disorder is recurrent dislocation of the temporomandibular joint.
4. Botulinum toxin A injection is a promising option in Myofascial Pain Disorder.
5. Conservative non-surgical treatment is the first line of treatment for myofascial pain in temporomandibular joint disorders.
6. A clicking joint without pain requires surgical repositioning of the displaced disc to prevent development of degenerative changes in the temporomandibular joints.
7. Displacement of disc is due to restriction in gliding movements of the disc caused by its adherence to the fossa.
8. Secondary degenerative arthritis occurs more often in younger patients and could be due to acute or chronic trauma.
9. Total joint replacement should be considered in patients with non-reducible disc displacement and with limited mouth opening.
10. Condylar shave is the treatment of choice for patients with degenerative arthritis in temporomandibular joint disorder.

## ANSWER SHEET FOR JUNE 2009

Please return the completed answer sheet to the Federation Secretariat on or before 30 June 2009 for documentation. 1 CME point will be awarded for answering the MCHK CME programme (for non-specialists) self-assessment questions. One Credit will be awarded for the Dental Council of Hong Kong's CPD Program for Practising Dentists and one credit under the CDSHK CME Program (both subject to approval).

## Overview and Update on Treatment of Common Temporomandibular Joint Disorders

### Dr. Raymond LK CHOW

BDS, MDSHK(OMS), MOS RCS(Edin), FHKAM(DS), FCDSHK(OMS)  
Specialist in Oral and Maxillofacial Surgery

### Dr. Philip KM LEE

BDS, MDS(OMS), FFDRCSI, FRACDS, FCDSHK(OMS), FHKAM(DS)  
Specialist in Oral and Maxillofacial Surgery

1  2  3  4  5  6  7  8  9  10

Name (block letters): \_\_\_\_\_ DCHK/HKMA No.: \_\_\_\_\_

HKID No.: \_\_\_\_\_ - \_\_\_\_\_ X X (x) HKDU No.: \_\_\_\_\_

Contact TelNo.: \_\_\_\_\_ CDSHK No.: \_\_\_\_\_

## Answers to May 2009 Issue

What is the Consequence of Children with Medically Intractable Epilepsy?  
What are the Treatment Options?

1. T    2. F    3. F    4. T    5. T    6. T    7. T    8. T    9. F    10. T

## 2 Day Course

# Cone-beam CT - Revolution in Dental & Maxillofacial Imaging

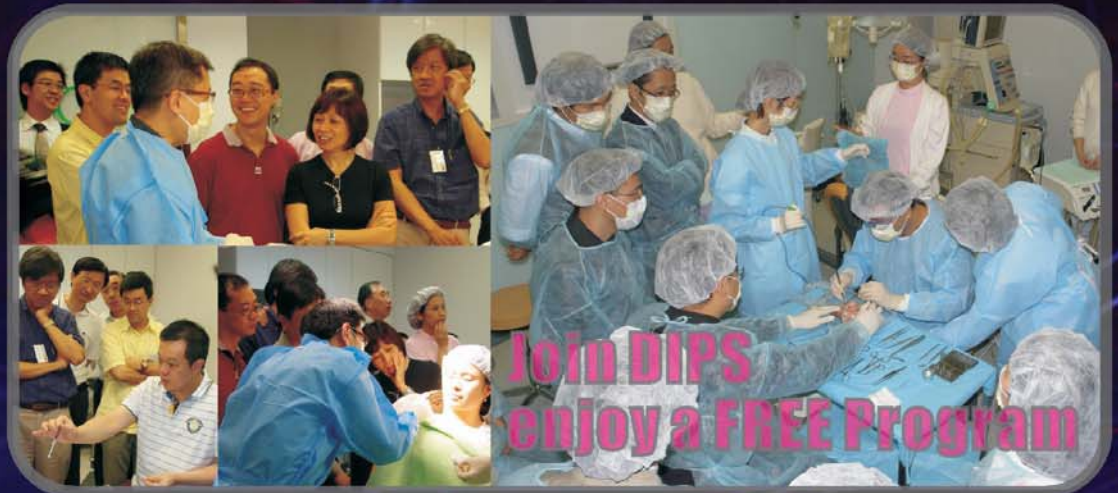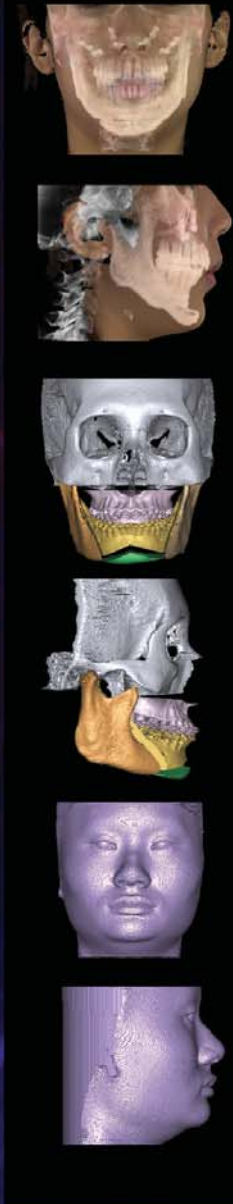
### 3 - 4 July 2009, HONG KONG

#### Day 1: The fundamentals & potentials

- The essentials of CBCT
- CBCT for dento-alveolar Surgery, periodontology & endodontics
- CBCT for orthodontics

#### Day 2: The current applications

- CBCT for maxillofacial anatomy and pathology
- CBCT for dental implants
- CBCT for OMFS



## What is DIPS?

Dental Implant Partner Scheme (DIPS) provides comprehensive consultation services to dentists who are doing dental implants or consider doing dental implants.

For further information, please contact Ms Jolie Kwok  
Tel: (852) 2851 4888 Fax: (852) 2851 4700 Email: [jolie.kwok@disc-hk.com](mailto:jolie.kwok@disc-hk.com)

[www.aboc.com.hk/ideasia/](http://www.aboc.com.hk/ideasia/)



# The Planning of Orthognathic Surgery - The Digital Era

## Dr. Ben CHOW

BDS, FRACDS, FCDSHK(OMS), FHKAM(DS)  
Specialist in Oral and Maxillofacial Surgery

## Dr. Alfred LAU

BDS, MDS(OMS), Adv Dip(OMS), MOSRCS, FCDSHK(OMS), FHKAM(DS)  
Specialist in Oral and Maxillofacial Surgery



Dr. Ben CHOW

Dr. Alfred LAU

Dentofacial deformity is defined as "the deviation from normal facial proportions and dental relationships that are severe enough to be handicapping". However the word "handicap" is not a pleasant word to use and the degree of deformity can vary from very mild to severe. Therefore this word has been seldomly used to describe this kind of patients. Although most of the time, treatments of dentofacial deformities are function restoring, a number of them are purely for cosmetic purposes. There is not a defined line between who needs and who does not need treatment. It all depends on the discussion between the patient and the surgeon, and sometimes, the patient's family members.

The word "handicapping malocclusion" was also used to describe dentofacial deformity in the 1975 report by the National Research Council of the United States of America, which focused attention on these problems. At of today, this term has largely been abandoned, because jaw function and facial esthetics, rather than dental occlusion, are the major problem. These patients almost always have severe malocclusion, but malocclusion is not the defining feature of their condition. Treatment almost always involves the co-operation between the orthodontist and the maxillofacial surgeon in different phases of treatment. Of course, a dentist is very important to be involved to maintain a healthy dental and oral condition before commencement of more complex treatment. The treatment process always starts with orthodontics for alignment, followed by surgical correction. It will then be followed by orthodontics again for fine alignment.

## Classification of Dentofacial Deformities

Most of the dentofacial deformities are developmental problems, either hypoplasia or hyperplasia of the jaw(s) or part of them, in any direction. There is not a unique system to classify all the deformities; however, it can be basically categorised into several types, as shown in table 1. Dentofacial deformity can be a part of some syndromes, associated with cleft lip and palate or an isolated problem.

## Orthognathic Surgeries

According to the diagnosis, orthognathic surgeries can be performed to correct the deformities. Le Fort I osteotomy is the most commonly performed maxillary surgery; It can move the maxilla, basically, in all dimensions. Maxilla can also be segmentalised into two

to five pieces to match the mandibular arch. If the nasal prominence or even the zygomatic buttresses are involved, Le Fort II or III osteotomy should be performed. Wunderer and Schuchardt osteotomies are performed when the correction of maxillary alveolar segment is needed. For the mandible, ramus surgeries such as sagittal split osteotomy and vertical subisigmoid osteotomy are performed to advance or set back the jaw and to correct asymmetry. Hofer osteotomy is performed when the angulation of the anterior mandibular alveolar segment needs to be corrected. Genioplasty is performed to correct deformed chin prominences in any direction, such as hyperplasia, hypoplasia and asymmetry. There are many other commonly performed procedures to correct dentofacial deformity in different situations; it all depends on the preference of the surgeon and the practice in different training centres.

Table 1. Different types of dentofacial deformities

Skeletal Deformity	Description	Underlying Skeletal Problem
Angle Class II	Short mandible in AP	1. Maxillary hyperplasia In AP
Angle Class III	Long mandible in AP / short maxilla in AP	1. Maxillary hypoplasia in AP or 2. Mandibular hyperplasia in AP or 3. Combination
Facial asymmetry	Deviated jaw / chin	1. Unilateral condylar hyperplasia or 2. Unilateral mandibular hyperplasia or 3. Chin deviation
Open Bite	Non-occluding anterior teeth	1. Reverse curve of Spee or 2. Posterior vertical maxillary excess 3. Short mandibular ramus or 4. Combination
Bimaxillary Protrusion	Proclined anterior bimaxillary alveolus	1. Bimaxillary dentoalveolar hyperplasia in AP
Vertical Maxillary Excess (VME)	Long maxilla in vertical	1. Maxillary hyperplasia in vertical

AP = anterior-posterior dimension

## Patient Evaluation

An accurate diagnosis will lead to good surgical planning, thus favourable results. A systematic and full evaluation of the patient is of utmost importance. The orthodontist and the surgeon should take part and be responsible throughout the evaluation process, and there should be always a joint discussion between the surgeon, the orthodontist and the patient, before a definitive treatment plan is made. Full history such as medical and dental history should be obtained before going into examination. Articulated dental models should be prepared for later evaluation. Understanding of the patient's socio-psychological profile will greatly reduce misunderstandings by knowing the patient's motives for surgery and expectations.

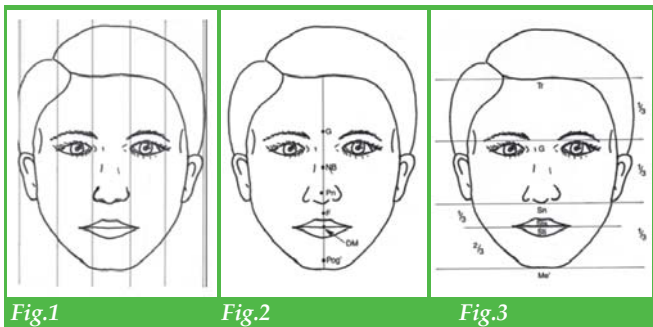
## Frontal and Profile Analyses

Esthetic facial evaluation should be separated into

frontal and profile analyses. For the frontal view, facial form should first be addressed. It is defined as the relationship between the facial width and vertical height. The general average of the height-to-width proportion is 1.3:1 for females and 1.35:1 for males. Short square facial types are usually associated with class II, deep bite, vertical maxillary deficiency and masseteric hypertrophy, while long narrow facial types are often associated with VME, narrow nose, high palatal vault and +/- anterior open bite. The "rule of fifths" is a commonly used method for analysing transverse facial proportion, where the face is divided into five equal parts as shown in Fig. 1.

Facial asymmetry is assessed through an imaginary line drawn from the soft tissue glabella, tip of nose, centre of filtrum and soft tissue pogonion. (Fig. 2) Assessment should be made not only on the chin midline, but also to facial balance, cheek and zygomatic prominence and level of the eyes. Vertical relationship can be assessed by dividing the face into upper, middle and lower thirds. Both skeleton and soft tissue should be evaluated in details, especially the symmetry. (Fig. 3)

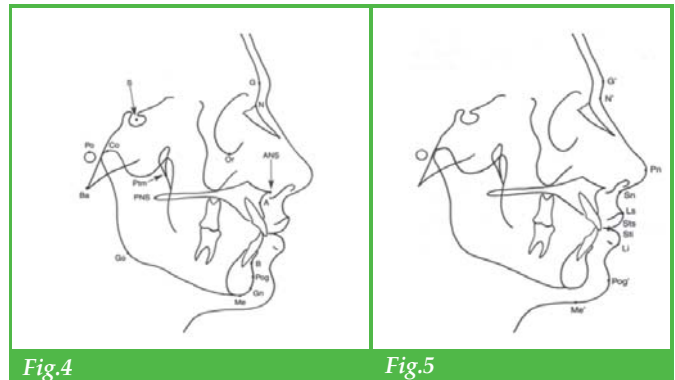
For the profile view, similar to frontal assessment, we would evaluate the form, the upper, middle and lower thirds. However, special attention is made to the nose, cheeks, naso-labial angle, lip prominence, labial-mental fold and the chin prominence.



**Lateral Cephalometric Analysis**

Before 3-dimensional radiology became popular, lateral cephalometric analysis was the gold standard. It helps in assessing both the skeletal and soft tissue profiles, with a list of standard landmarks. (Fig. 4, 5) Angulations and distances between different landmarks are usually compared with the calculated average, using reference data of the same ethnic group. It is a very useful tool, as it indicates very clearly where are the problems and to what degree the deformities are. However, although cephalometric analysis is very import in both diagnosis and development of a treatment plan, it has several limitations. Firstly, errors could be created by a moving patient or in different head positions. Also, some individual's deformities have anatomic variations in the location of the cephalometric landmarks used as a baseline in many averages of the left and right skull analyses, thus resulting in incorrect conclusions. Cephalometry is still, a 2D image where the left and right sides of the skull cannot be analysed separately, whereas only a 3D image can give a full impression especially in an asymmetric case. It is very important that the clinician should always remember not to rely on a single cephalometric finding. Although cephalometric analysis forms an important part of the data base for diagnosis,

it should not take precedence over the clinical evaluation of the patient.



**Protocol for 3D Orthognathic Workup**

One of the objectives of orthognathic surgery is to produce a harmonious occlusion and facial appearance by normalising the position of the teeth as well as the jaw bones. As the surgical techniques mature over time, the expectation of our patients also rises tremendously. We have to plan more carefully, perform more safely and communicate better with our patients. Nowadays different 3D imaging modalities and more user-friendly computer software serve us well in this aspect. Gradually we develop our own protocol for 3D orthognathic workup for our patients utilising both 3D scan and 3D photography.

Cone beam CT (CBCT) has gained popularity over the recent years because it can provide 3D DICOM data of both soft and hard tissues with a relatively low radiation dose when compared with conventional medical CT. It has also the added advantage of having the scanned subject positioned in an upright position. Therefore the soft tissue of the face can be captured in the natural head position which is important when doing soft tissue analysis and soft tissue simulation of our planned virtual surgery.

A 3D stereophotogrammetrical camera set up is used to capture a 3D photograph of the face. The camera generates a 3D photograph from six 2D photographs taken simultaneously (four grey-scale photographs and two full colour photographs). A polygon pattern is projected into four of these six images. Based on this pattern and its deformed image, a 3D photograph is reconstructed. The 3D photographs are taken in the natural head position with the eyes open. Image fusion, i.e. registration of a 3D photograph upon a CBCT, results in an accurate and photorealistic digital 3D data set of a patient's face. (Fig. 6)

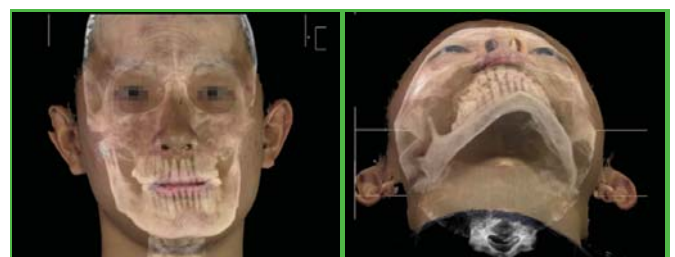

Fig. 6. High precision 3D surface image registered with CBCT data



## 3D Augmented or Composite Model

During CT scanning, artifacts generated due to metal fillings and orthodontic brackets are normally present at the teeth level causing inaccurate visualisation of the interocclusal relationship. There are different ways developed to set-up a 3D virtual augmented model of the skull with detailed dental surface. 3D virtual dental models can be obtained by using two different 3D image acquisition techniques: volumetric imaging techniques (e.g. computerised tomography) and surface acquisition systems (e.g. laser surface scanning, probe scanning). The digital image of the teeth surface can be combined with the skull model by registration techniques using special facial bow or occlusal wafer with radiographic markers. (Fig 7) For some difficult selected cases, we may produce a 3D stereolithographic model by the rapid-prototyping technique. We can physically perform surgical procedures on these models.

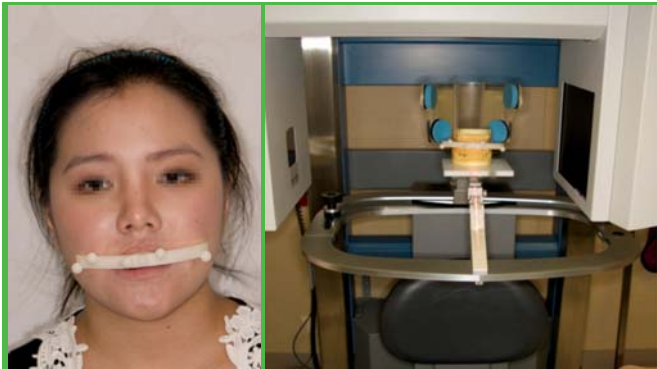

Fig. 7 CBCT of patient and dental casts for registration with special facebow

## Digital Copy of the Patient

Data from the CBCT are exported in DICOM format. The skull and skin surfaces are segmented by thresholding. The soft tissue surface is textured with 3D photographs. The dentition is augmented with high resolution scan of the study models. Now we actually have a digital copy of our patient in front of us for all the analysis, diagnosis and planning in the virtual environment. (Fig. 8)

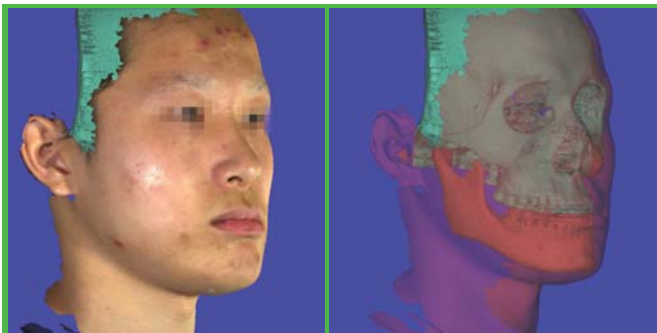


Fig. 8 Digital copy of patient comprising of CBCT data of skeletal and dental structures registered with photorealistic textured skin surface

## Computer Planning Software

There are various commercially available software programmes on the market that provide platform for us

to do our orthognathic workup from making the correct diagnosis to bringing the patient to the operating theatre.

## 3D Cephalometric Analysis

The traditional lateral cephalometric analysis has the difficulty of identifying the various anatomical landmarks projected onto a mid-sagittal plane as mentioned before. This limitation is even more noticeable when we are dealing with facial asymmetry. However location of anatomical landmarks on a 3D skull model is straight forward. Many research centres are coming up with 3D cephalometric data for normal population and individuals with various dentofacial deformities so that an accurate reference is available to make our diagnosis. (Fig. 9)

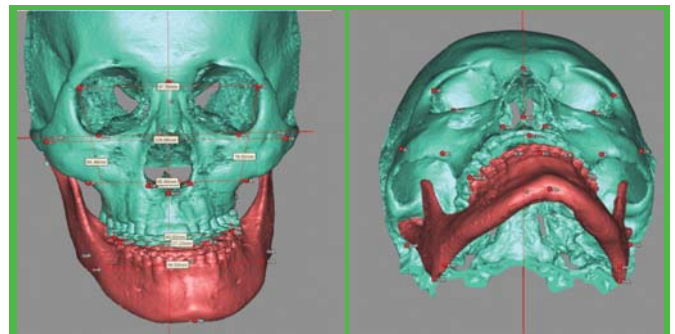


Fig. 9 Anatomical landmarks on 3D skull model and 3D cephalometric analysis

## Virtual Surgery

Surgeries can be performed on the 3D virtual model. It is possible to visualise the relative movements of different bony segments and identify any potential obstacles to our surgical movements. Therefore different surgical plans can be tried out, so as to optimise the surgical procedures and to improve the surgical outcome. All these help to reduce the surgical time and the chance of facing surprises on the operating table. (Fig. 10)

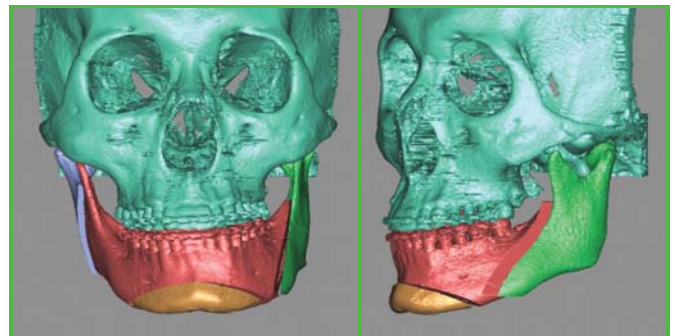


Fig. 10 3D virtual surgical plan

## Soft Tissue Simulation

Photorealistic computer simulation of the soft tissue change as a result of the surgical movements is the area that patients show most concern. Of course proper guidance is required for the patients to interpret the result properly. We can also fine-tune our surgical movement based on the simulation result. (Fig. 11)

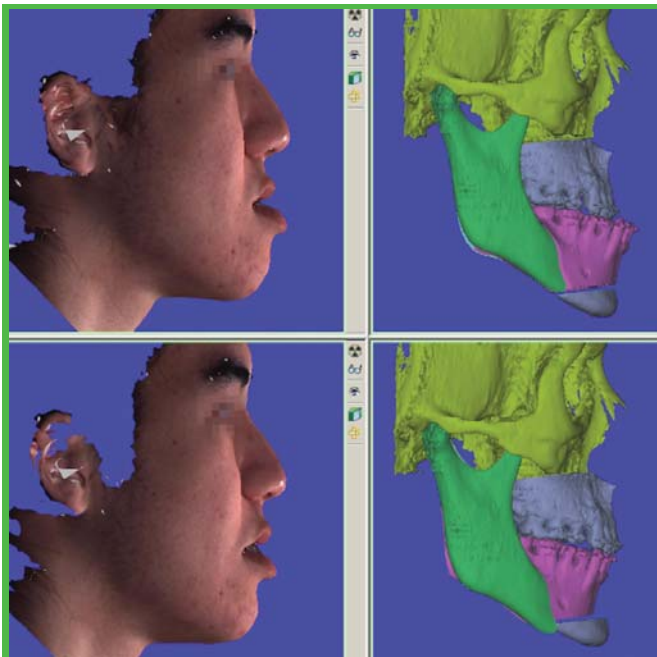


Fig. 11 Soft tissue simulation

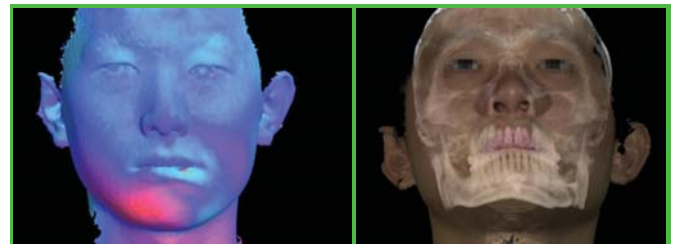


Fig. 14 Colour Histogram showing the difference between pre- and post-operative soft tissue surfaces

The application of 3D imaging modalities and computer planning software has helped a lot in our orthognathic workup making the surgery more acceptable and predictable. It is also a useful tool of communication with the patients so that they can understand their problems better and have more realistic expectation of the surgical outcome. It also opens up a totally new territory for clinical research leading to better understanding of the surgery and improved surgical techniques. In the end we will have more happy patients.

### Future

We still need to make a dental impression now. However the first intra-oral scanner that can capture the image of our dentition quickly and accurately will become available commercially very soon. We are just a tiny step away from having all our 3D orthognathic workup performed digitally.

### CAD/CAM Construction of Surgical Wafer

Time has arrived when physical model surgery is no longer necessary for the fabrication of surgical wafers. The virtual surgical plan can be transferred to the operating table through the CAD/CAM construction of surgical wafers. (Fig. 12)



Fig. 12 CAD/CAM construction of surgical wafer

### Clinical Audit of the Surgery

It is possible to superimpose the pre and post-operative 3D data sets, so enabling accurate 3D cephalometric comparison of the hard tissue changes after osteotomies. A study by Joanneke on sagittal split osteotomy, besides the expected AP movement of the distal segments of the mandible, unexpected rotational and translational movements of the proximal segments of the mandible were visualised, resulting in obviously changed positions of the condyles in the fossae. Furthermore, wide variations of the lingual fracture were observed. We can also make direct comparison of the pre and post-operative soft tissue 3D surfaces. (Fig. 13) A colour histogram is a convenient way to visualise the actual change in a glance. (Fig. 14)

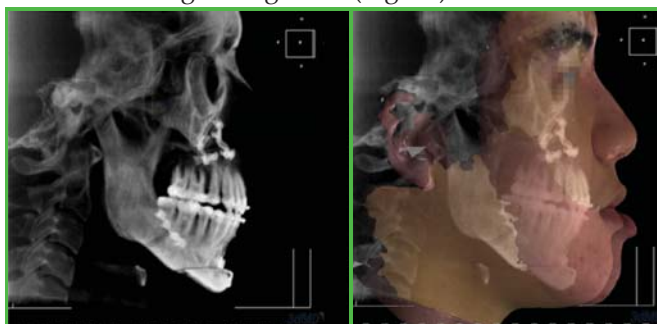

Fig. 13 Post-operative CBCT registered with pre- and post-operative soft tissue surfaces

## SurgiCase CMF—Stress-Free Surgery

- CT/MRI Reconstruction
- 2D/3D Cephalometric Analysis
- Simulation of CMF Surgery
- Soft Tissue Simulation
- CMF model and Guides

**Application Cases...**

	Dr Davids, Germany
	Dr Buchbinder, USA
	Dr Simon Holmes, UK
	Dr. J. Poukens, Holland

**Powerful, highly accurate 3D simulation environment for cranio-maxillofacial surgeries**

Optimize surgical procedures	Virtually simulate surgeries	Improve the surgical outcome
------------------------------	------------------------------	------------------------------

**Links with Surgery...**

Facilitate medical diagnoses	Cephalometric	Orthognathic
Reconstruction after tumor remove	Trauma	Anplastology and facial prosthese
Soft tissue simulation	Customize Implant	Export STL for RP model

**Materialise China**

Rm. 1803A, BaoAn Mansion, No.800, Dongfang Road  
 Pudong, Shanghai, P.R. China 200122  
 Tel: +86-21-58312406/5906  
 E-mail: software@materialise.com.cn  
 Web: www.materialise.com.cn/www.materialise.com

**Materialise**  
driving your innovations



# A huge step for mankind since 1998



**2001 Queen's Award for Enterprise**  
Innovation in the discovery and development of Viagra®<sup>1</sup>



**2001 The Prix Galien**  
Canada Innovative Drug Product Award for Viagra®<sup>1</sup>



**2003 Crystal Faraday Award**  
Green Technology for development of  
environmentally-friendly method of production of Viagra®<sup>1</sup>

Worldwide

**10-year**  
Anniversary



**Congratulations**

**VIAGRA®**  
(sildenafil citrate) tablets

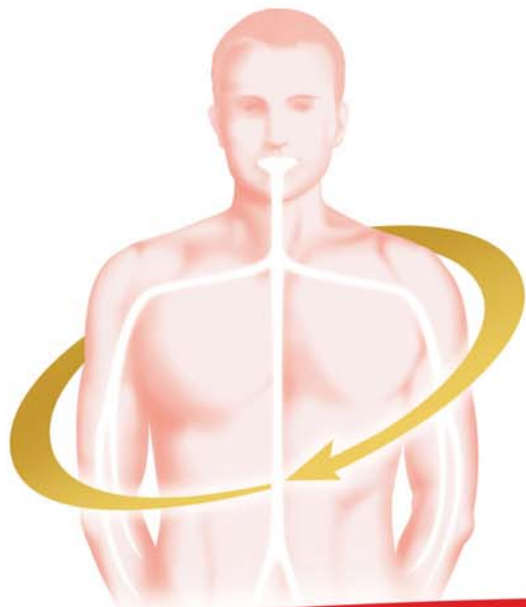


**Pfizer Corporation Hong Kong Limited**

16/F., Stanhope House, 738 King's Road,  
North Point, Hong Kong  
Tel: (852) 2811 9711 Fax: (852) 2579 0599  
Website: [www.pfizer.com.hk](http://www.pfizer.com.hk)

Viagra® is indicated for the treatment of erectile dysfunction (ED). The use of Viagra® and organic nitrates in any form, at any time, is contraindicated. The most common side effects of Viagra® were headache, flushing and dyspepsia. Adverse events including visual effects were generally transient and mild to moderate. Viagra® is available in 50mg and 100mg tablets. Detailed prescribing information is available upon request.

Reference 1: Data on file. Pfizer Inc. New York, NY.



# Think all toothpastes work the same?

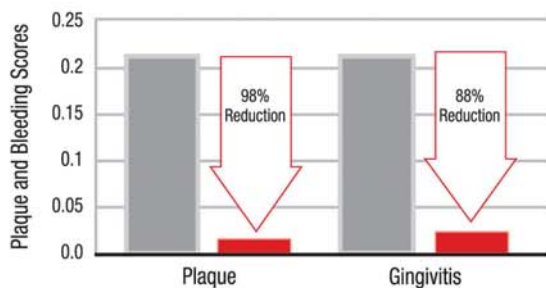
Colgate Total® is proven to help prevent gingival inflammation.<sup>1</sup>

**Colgate Total® contains a Triclosan + Copolymer formula that helps fight gingival inflammation in two ways:<sup>1,2,4</sup>**

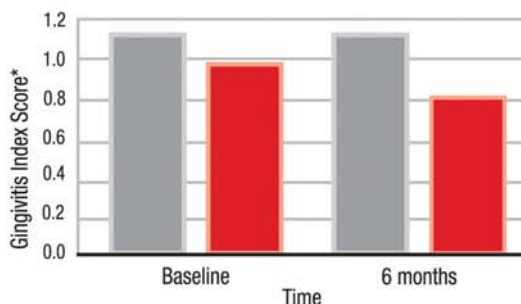
**1.** Kills plaque bacteria for a full 12 hours<sup>2</sup> to help reduce plaque by up to 98% and gingivitis by up to 88%.<sup>3</sup>

**2.** Shown to directly reduce gingival inflammation<sup>4</sup>

**Reduction compared with control**



**Reduction of gingival inflammation at sites without visible plaque**



\*At sites with Plaque Index Score = 0



Refer to Colgate Total package for approved uses

**12-Hour Protection that Helps Prevent Gingival Inflammation.  
Better Oral Health as Part of Better Overall Health.**

1. Panagakos F, et al. *J Clin Dent.* 2005; 16 (Suppl): S1-S20. 2. Amornchat C, et al. *Mahidol Dent J.* 2004; 24: 103-111. 3. Garcia-Godoy F, et al. *Am J Dent.* 1990; 3 (Special Issue): S15-S26. 4. Lindhe et al. *J Clin Periodontol.* 1993; 20: 323-334, supplemental report on file.

©2007 Colgate-Palmolive Company.



# Manifestations and Management of Oral Complications in Transplant Recipients

**Dr. Antonio TONG**

BDS, FRACDS, FFDRCSI, FRACDS(OMS), PhD, FCDSHK(OMS), FHKAM(DS)  
Senior Dental Officer, OMS and Dental Unit, Queen Mary Hospital



Dr. Antonio TONG

Advances in innovative surgical technique and immunology have enabled many organ and haematopoietic cell (bone marrow) transplant recipients to resume normal life. The likelihood of dental surgeons having the opportunity to manage transplant recipients is increasing. The common oral manifestations & management of complications related to tissue transplant are reviewed.

The indications for tissue transplantation are extensive. In this discussion, the focus will be on oral complications related to the transplant of major organs and haematopoietic cells. The need for transplantation in these situations is often related to end-stage organ failure and haematological neoplasms. A major concern following successful transplantation will be the prevention of not just graft rejection by the host but also graft-versus-host disease (GVHD). Despite sophisticated blood, genetic marker and tissue typing, allogeneic transplant is still fraught with complications. Therefore medications are commonly used for suppressing the recipient's immune system, and the new donor immune system in haematopoietic cell transplant (HCT) - also commonly called bone marrow transplant, to prevent GVHD.

Most immunosuppressive medications are nonspecific and have systemic side effects. Examples of commonly used medications for immunosuppression are corticosteroids, cyclosporine, azathioprine, tacrolimus, sirolimus, and myophenolate etc. Cytotoxic agents and total body irradiation are also used in conditioning bone marrow prior to HCT.

Cyclosporin is well known to be associated with gingival hyperplasia. Severe gingival hyperplasia is managed by gingivectomy followed by rigorous oral hygiene measures. The systemic side effects of immunosuppression related to the use of such medications will not be further discussed. Oral complications in transplant recipients often present as opportunistic infections or mucosal lesions. These can be broadly classified as:

1. Infective conditions.
2. GVHD.
3. Neoplasms.
4. Miscellaneous: mucositis, recurrent ulcerations, soft tissue overgrowth, salivary gland dysfunction etc.

Signs of infection in transplant patients may be muted or exaggerated depending on the patient's immunocompetence. Bacterial infections, including dentoalveolar abscess, while usually localised, may

soon show signs of systemic involvement in immunocompromised patients. They should be treated by prompt and appropriate empirical antibiotics, modified according to results of culture and sensitivity tests. Apart from periodontal and caries related dental infections, viral infections are a common problem in immunosuppressed patients. Herpes simplex virus (HSV) is one of the commonest pathogens, presenting as recurrent herpes labialis or intraoral herpes. Other common viral infections include herpes zoster and EBV infections. Oral hairy leukoplakia had been reported in transplant patients who are HIV negative.<sup>1</sup> While viral infections in normal patients require usually symptomatic treatment, early diagnosis and prompt treatment with appropriate antiviral agents are required in immunosuppressed patients. Fungal infections in this group of patients range from common Candidiasis to deep fungal infections. Fungal infections like aspergillosis, histoplasmosis and zygomycosis, which rarely affect immuno-competent patients can occur in transplant recipients. Deep fungal infections involving the upper respiratory tract and the paranasal sinuses can be fatal in severely neutropenic patients. Rhinocerebral zygomycosis is a destructive fungal infection of the midface and the nasal passages in severely immunocompromised patients, due to members of *Mucor* or *Rhizopus* of the phylum *Zygomycota*. Correction of predisposing conditions, surgical debridement and systemic antifungal treatment are needed.

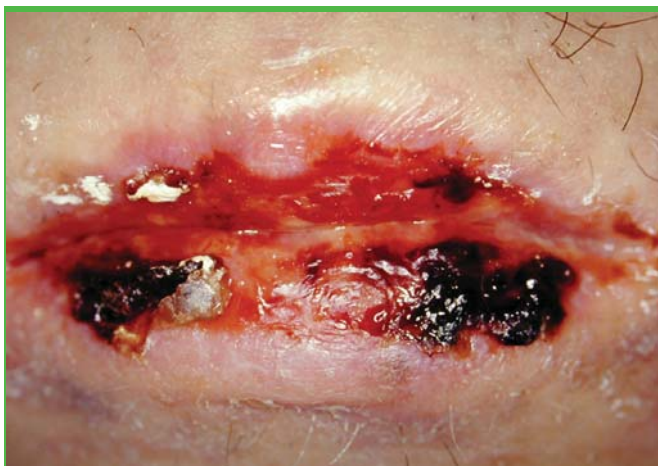GVHD is a complication following HCT. This occurs when acquired immunocompetent T lymphocytes from the graft attack the host cells of the graft recipient. GVHD affects the oral cavity, the entire gastrointestinal system, the skin and the liver. The mucosal reaction of GVHD is very similar to that of lichen planus. In severe cases, the mucosa of the oral cavity and the lips can be seriously eroded with ulceration and crusting (Figs. 1, 2). Biopsy is often required to confirm the diagnosis and to rule out malignancies. Management of such conditions is often difficult. It often requires modification of the immuno-suppression regimen. Oral symptoms can be relieved with benzydamine mouthrinse and topical steroids. Prevention of secondary bacterial infection in cases of extensive oral ulcerations can be achieved by using tetracycline mouthrinse and is often beneficial. Tetracycline mouthrinse can be prepared by dissolving the powder from a 250mg capsule in 10 to 20 cc of water. The patient is then advised to hold the mixture in the mouth for one to two minutes. Severe cases of oral ulceration may require intralesional or systemic steroids (Figs. 3,4).

The use of topical azathioprine has been reported with some success. However, topical azathioprine is not available in HK.<sup>2</sup>

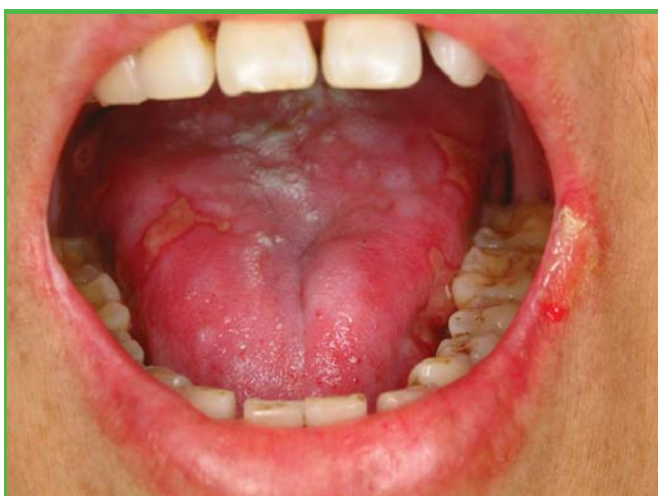In addition to GVHD, recipients of allogenic HCT may develop gingival and other mucosal soft tissue fibroepithelial polyp overgrowth, especially in patients on cyclosporine. As there is a potential danger of malignant transformation, such tissues should be excised and subjected to histopathology study (Fig. 5).

Because of immunosuppression, transplant patients are at risk of developing lymphoid & epithelial neoplasms. Lymphoma and Kaposi's sarcoma can present in the oral cavity. Squamous cell carcinomas can affect the lips.

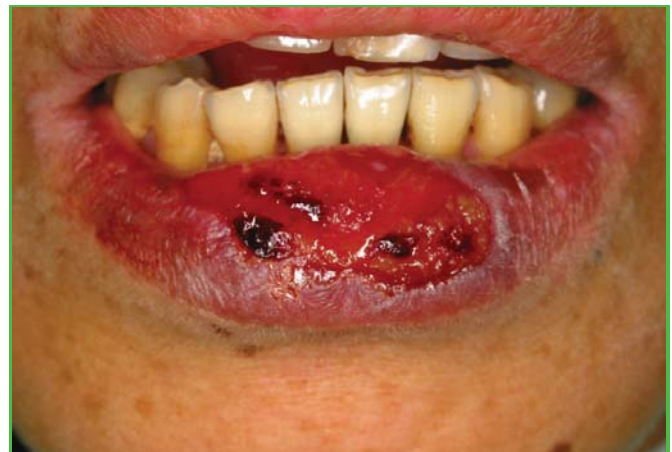Management of oral complications in transplant recipients requires collaboration of the oral and maxillofacial surgeon with the patient's physicians, surgeons or clinical oncologist. The oral surgeon plays an important role in the early diagnosis of such complications. Antimicrobial treatment and biopsy should not be delayed as fatal consequence can occur even in opportunistic infections, while malignancies should be recognised and treated early.



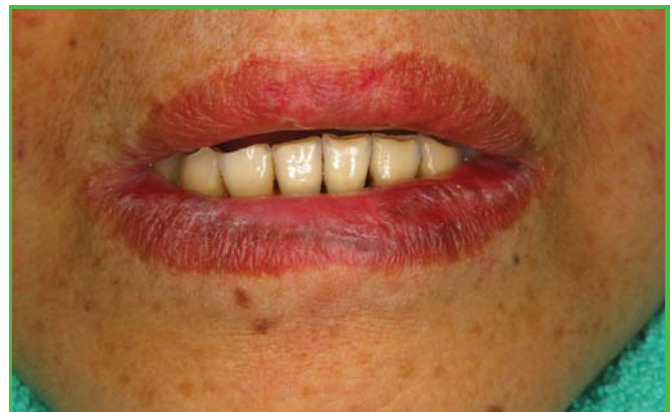*Fig. 1 Severe GVHD affecting the skin and oral mucosal surface with generalised ulceration and crusting of this patient who had received bone marrow transplant for leukaemia.*



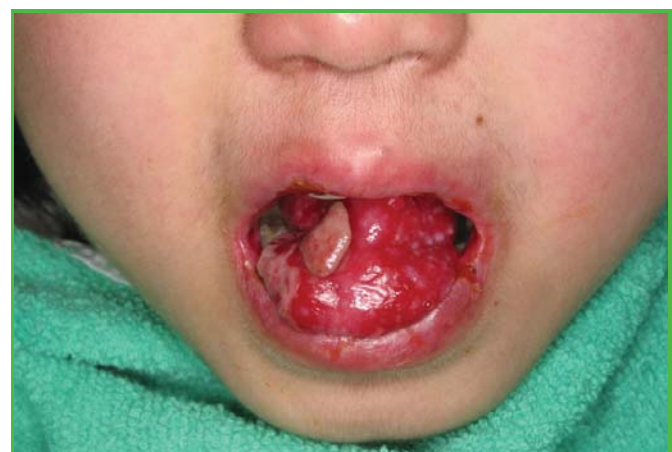*Fig. 2 Generalised mucositis and multiple ulcers involving the tongue borders and dorsum, and corner of mouth.*



*Fig. 3 Lower lip ulcer in a patient with GVHD following bone marrow transplant for leukaemia.*



*Fig. 4 Healing of the ulcer following topical steroid and intralesional injection of triamcinolone acetonide.*



*Fig. 5 Hyperplastic tissue growth on the tongue dorsum in GVHD following bone marrow transplant. Histopathological examination of the excision specimen confirmed squamous cell carcinoma.*

## References

1. Wurapa AK, Leque AE, Menegus MA. Oral hairy leukoplakia: a manifestation of primary infection with Epstein-Barr virus? *Scan J Infect Dis* 1999; 31: 505-506.
2. Epstein JB, Nantel S, Sheoltch SM. Topical azathioprine in the treatment of combined graft-versus-host-disease. *Bone Marrow Transplant* 2000; 25:683-687.
3. Sollecito TP, Pinto A, Naji A, Porter D. *Transplantation Medicine*. In: Greenberg MS, Glick M, Ship JA, editors. *Burket's Oral Medicine* Ch. 19. Hamilton: BC Decker Inc, 2008:461-480.

# THERAPEUTIC

D E R M A

THERAPEUTIC DERMA LIMITED

Therapeutic Dermatologic Formula (TDF) is proven by extensive dermatological tests and well recognized by many skin specialists and medical practitioners. TDF products are based on latest technology and scientific discoveries from both USA & ASIA. Meticulously and scientifically blended by experts at Ocean Health Lab Inc USA, TDF range of skin care contains the finest and most effective ingredients that give you the quality and the ideal results desired. What's more, TDF is among the leading brand of dermatologist and aesthetic physician prescribed skincare treatments, which offers a wide range of products that are superior in quality and efficacy, delivering visible results.

## THERAPEUTIC™ DERMATOLOGIC FORMULA MADE IN USA

Only available from physicians

Leading brand of dermatologist and  
aesthetic physician prescribed  
skincare products



Acne Treatments



Anti-Aging Products



Chemical Peels

### Therapeutic Derma Limited

Suites 2410-11, 24/F., Shell Tower, Time Square, 1 Matheson Street, Causeway Bay, Hong Kong.

Tel : (852) 8206 3113 Fax : (852) 2180 9163

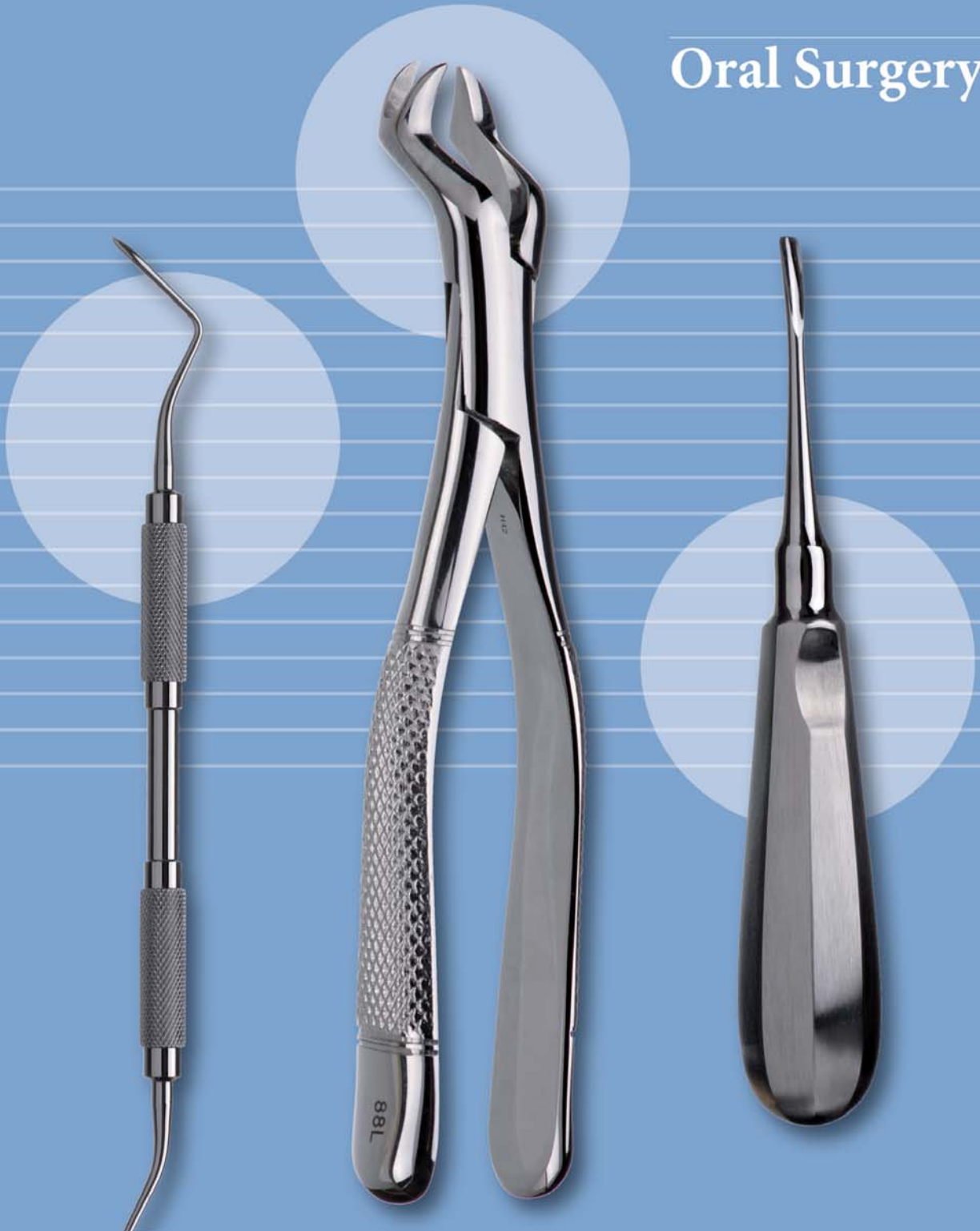Website : <http://www.therapeutic.com.hk>

stryker®

LEIBINGER

# Instrument Sets

Oral Surgery Set





# Tooth Autotransplantation as a Treatment Option

**Dr. Eddie CK YAU**

BDS, FFDRCSI, MSc, FHKAM (Dental Surgery), FCDSHK (OMS)  
*Consultant, Oral and Maxillofacial Surgeon, Princess Margaret Hospital*



Dr. Eddie CK YAU

## Introduction

Tooth autotransplantation refers to the extraction of a tooth from one location and its replantation in a different location in the same individual. The new location may be a fresh extraction socket after extraction of a non-restorable tooth, or an artificially drilled socket on an edentulous alveolar ridge. Its definition also encompasses the surgical repositioning of a tooth within the same socket. Cost effectiveness is the obvious advantage of this procedure which enables the utilisation of a tooth that is hitherto non-functional (usually third molar tooth) to be transferred to a functional position to replace a lost tooth in the same person. The main disadvantages are surgical involvements, technique sensitivity, relatively low versatility in their applications (e.g. tooth and space size discrepancy) and more importantly low predictability in results compared to conventional prosthetic (implants, bridge, dentures) restorations.

Over the years, the Oral & Maxillofacial Surgery & Dental Unit of the Princess Margaret Hospital has employed autotransplantation to manage patients' tooth loss as a cost-effective treatment modality in a variety of clinical scenarios. This article aims at sharing our clinical experience with our colleagues in this technique.

## Biological Principles and their Clinical Applications

The understanding of the healing process of a transplanted tooth is imperative to its success. In other words, it minimises the incidence of root resorption and tooth ankyrotic complications. The preservation of favourable periodontal ligament (PDL) on the donor tooth is the critical factor for success. Reattachment occurs in about 2 weeks after autotransplantation between the PDL connective tissues of the donor root surface and the wall of recipient socket. The type of healing of transplanted tooth is dependent on the surface area of the damaged root to be repopulated. When the damaged PDL surface is small, the healing can be achieved by cemental healing. However when the damaged PDL surface is large, some of the root surface will be resorbed followed by apposition of bone rather than dentine, thus root resorption will ensure. Genetically, PDL cells can differentiate into fibroblasts, cementoblasts and osteoblasts. In the ideal situation, one would hope PDL cells on the root surface to differentiate into cementoblasts and induce dentine formation, whereas PDL cells on the side of bony socket wall surface

to differentiate into osteoblasts thus inducing bone formation. In addition, the contributions of the progenitors PDL cells on the recipient fresh extraction sockets should not be overlooked, that also accounts for the higher successful rate for freshly extracted recipient sockets compared to artificially drilled ones. It is important to minimise inflammation so that reattachment can progress to the healing stage with the proper differentiation of the PDL cells. Inflammation will be minimised when the transplanted tooth is sealed with tight suturing of the gingival cuff around the tooth to prevent ingress of infective agents. This can be achieved by trimming and suturing of the recipient site flap before the implantation of the donor tooth. When the follicle or even dentigerous cyst is present over the amelo-dentinal junction of the donor tooth, it is also useful to preserve the soft tissue lining around the tooth to facilitate suturing to the recipient gingival cuff. It is also important to minimise inflammatory pulpal response from the transplanted tooth. For fully developed donor teeth, root canal treatment should be initiated 2 weeks after transplantation. The interim period of 2 weeks is chosen to minimise trauma to the PDL in the initial reattachment healing phase, yet further delay will increase the chance of complication of inflammatory resorption secondary to pulpal infection. In the case of donor tooth with incomplete root formation, the preservation of the apical Hertwig's epithelial sheath is important to ensure pulpal regeneration and root maturation and eruption. Ideally, one would prefer the donor tooth to be at its maximum length but still has its potential for pulp regeneration with apex opening >1mm radiographically. This will ensure that a sufficiently long root can still be preserved even root development is curtailed prematurely after autotransplantation.

## Case Reports

### Case 1:

A 12-year boy was referred from School Dental Clinic for a massive calcified mass in left mandible. He gave a history of recurrent swelling & tenderness. There was no mental nerve paraesthesia on presentation. Orthopantomogram (OPG) revealed a gigantic radiopaque mass extending from 36 to 38 molars region. The surface was convoluted and surrounded by a radiolucent rim distally. 36 was displaced to lower border and so was the inferior dental canal. The differential diagnosis made was complex composite odontoma

Surgical excision of the lesion and the displaced 36 was

done under general anaesthesia (GA). The inferior dental nerve was preserved with no sensory loss, nor had pathological fracture happened. New bone regenerated in the original defect left by the lesion. All lower left molars were missing and subsequent overeruption of upper molar 27 happened. At age 19, transplantation of right upper wisdom tooth 18 to left edentulous mandible was done under LA. Overerupted 27 was also extracted. On 5 year post-operative review at age 24, transplanted tooth 18 had further erupted with good bone support.

This case showed that transplanted tooth can be taken well in artificial cavity drilled in regenerated bone secondary to excision of pathological lesion.

### Case 2:

A 12-year old girl was referred from School Dental Clinic for odontomes and displaced lower right canine 43. OPG revealed a haphazard odontoma-like calcified mass in 43 region surrounded by radiolucent rim compatible to soft tissue sac. Canine 43 was displaced to lower border and towards midline, also surrounded by radiolucent rim attached at dentigerous relationship compatible to dentigerous cyst. Deciduous canine 83 was retained with short root and poor prognosis. Transplantation of displaced canine 43 to 83 socket after excision of 83 and odontoma via buccal window approach was carried out under GA. Overlying cystic lining of 43 was excised with soft tissue rim left attached to facilitate primary closure to the gingivae cuff. 43 was fixed with arch wire and composite splint for 2 weeks. At age 14 two years post-op, 43 had erupted into functional occlusion. Periapical X-ray confirmed healthy periodontal ligament space surrounded with lamina dura. Neither root resorption nor ankylosis was noted.

### Case 3:

A 12 year-old boy was referred for unerupted upper right lateral incisor & canine 12 & 13. OPG revealed displaced dilacerated 12 labially, 13 eruption was impeded and impacting against central incisor 11. The dilacerated 12 was excised and 13 was disimpacted from 11 and transplanted into position of 12 (Intra-alveolar transplantation) under local anaesthesia. It was noted that there was deficiency in bone support in the mesial aspect of 13 left by the void of the follicle of 12. 13 was fixed with arch wire and composite splint for 3 weeks. Post-operatively, 13 continued to erupt and upright into functional occlusion. At age 15 and 3-year post-op, OPG & periapical radiographs confirmed deposition of new alveolar bone mesial to 13 next to the incisor, close up to the amelo-cemental junction. The apex of 13 also continued to grow (Apexification) and there was obliteration of the root canal and chamber, signs of positive regeneration and absence of pulpal infection. This case illustrated the osteo-inducing potential of the PDL cells of the transplanted tooth which is a major advantage over implants.

## Discussion

Implant technology has taken great strides in recent years in terms of predictability in both success rate & aesthetic result. Comparison between autotransplantation & implantation as treatment options in replacing missing teeth seems inevitable. One major advantage of transplantation over implantation is its applicability

in the management of patients before puberty growth has finished. Implants will not grow with the growing patients and result in infraocclusion. The beauty of transplanted teeth is that they are biological and able to erupt in harmony with adjacent teeth and growing jaws. The open apex of the transplanted tooth with intact Hertwig epithelial root sheath also allows healing and regeneration of the pulpal tissue and therefore saving subsequent root canal procedures. Another advantage of transplantation is the osteoinducing potential of the periodontal ligament (PDL) cells resulting in bone regeneration between gap of the walls of socket and the transplanted tooth. This is a welcome phenomenon we observed again and again clinically and confirmed with radiographs, especially in children & adolescents. Genetically the PDL cells can differentiate into fibroblasts, cementoblasts and osteoblasts thus explaining this osteoinducing phenomenon. It would be an interesting thought to utilise these valuable PDL cells to the advantage of our implant technique in future. One might harvest PDL cells from the root surface of extracted non-functional wisdom tooth and transfer them to the gap between implant and the drilled hole. Just in the case when transplanted teeth induce bone growth in drilled bone cavity, it would be interesting to observe if the free PDL cells will have similar adjunctive bone inducing effect on the wall of the drilled implant cavity bony surface. The mode & medium of transfer remain to be a subject of further research.

## Conclusion

There is obvious limitation in terms of versatility in the application of transplantation verses implantation in replacing missing teeth. The availability of suitable size & morphology donor tooth being the major constraint. The success rate of implant is also higher than that of transplant. Reported survival rates of autotransplantation vary from 74-100%, artificially drilled recipient sockets tend to be at the lower end of the range of success rate. It is also more technique sensitive and less predictable in terms of success rate & aesthetic outcome. Admittedly our cases are more challenging than most reported autotransplantation series in that the ablations of associated pathological lesions result in less than ideal recipient socket wall support. However our experience in autotransplantation demonstrates that it is a viable treatment alternative especially in growing adolescents even in cases after ablation of pathology. It provides a biological & economical treatment alternative for tooth replacement subsequent to surgery loss in the patient group typical of public service.

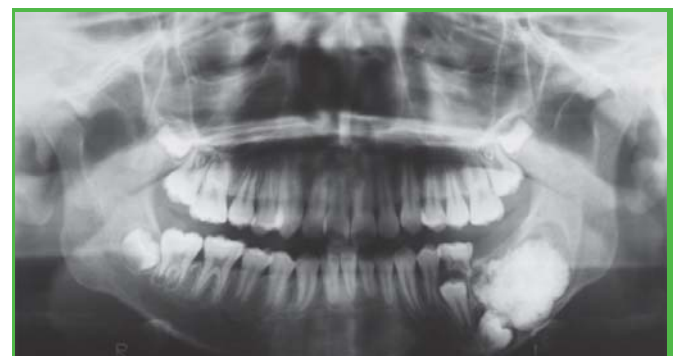

Figure 1a. Age 12. Gigantic complex composite odontoma of left mandible and displaced lower left first molar 36 prior to excision..



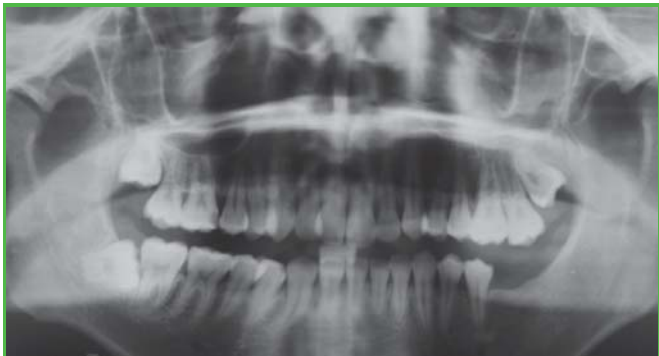

Figure 1b. Age 19. Good bone regeneration in left mandible but missing all molar teeth. Overerupted opposing upper molar tooth 27.

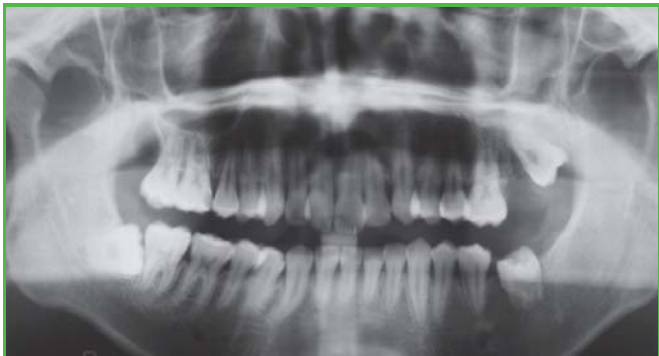

Figure 1c. Age 19. Transplantation of upper right wisdom tooth 18 to lower left mandible 36 molar region. Excision of opposing overerupted tooth 27.

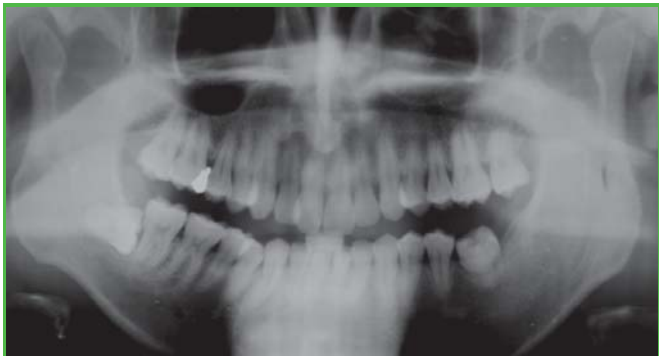

Figure 1d. Age 24. Five years post-op. Transplanted tooth showed further eruption and firm with good bone support.

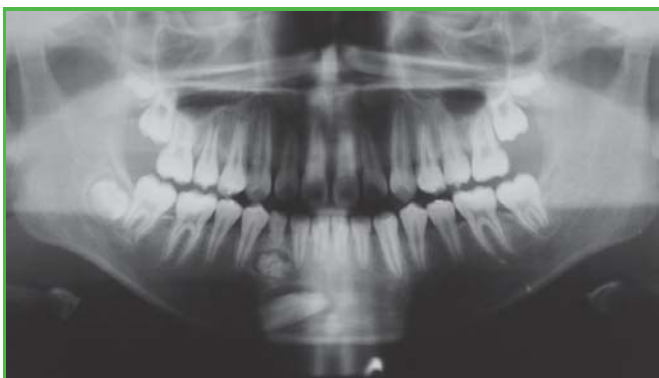

Figure 2a. Age 12. OPG showing displaced right lower canine 43 by odontoma. Retained right lower deciduous canine 83.

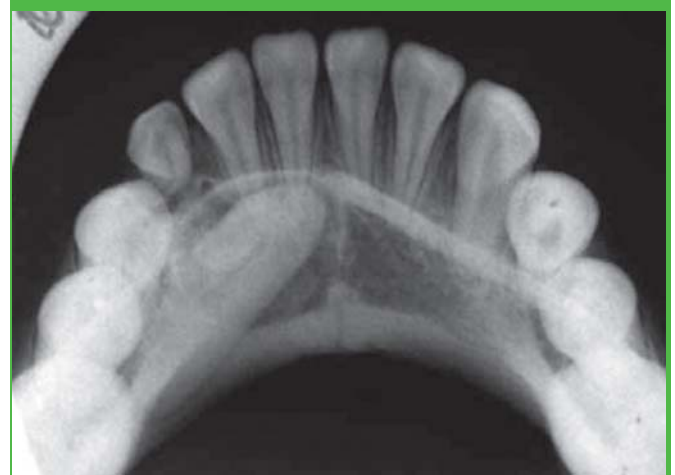

Figure 2b. Occlusal XR showing displaced canine 43.

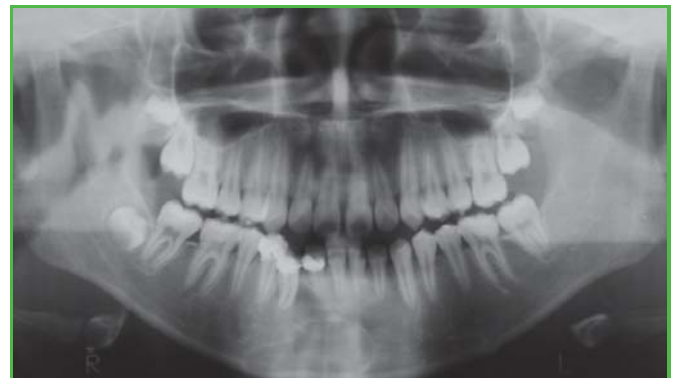

Figure 2c. Excision of odontoma and transplantation of impacted canine 43 to socket left by excision of deciduous tooth 85.

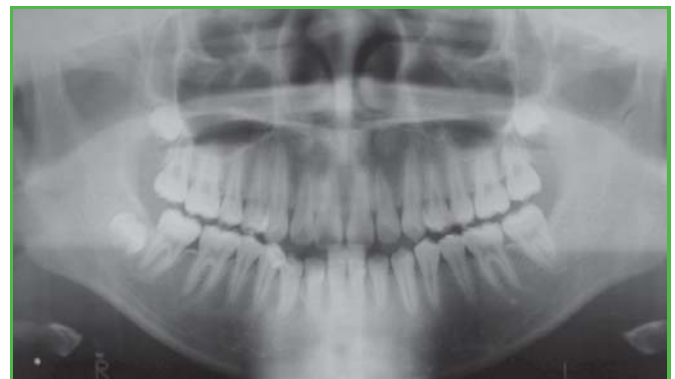

Figure 2d. Age 14. Two years post-op. Transplanted canine tooth 43 in good functional position.

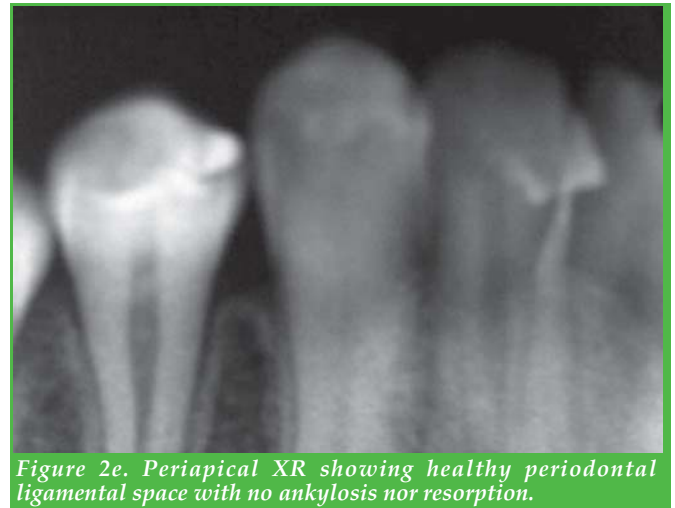

Figure 2e. Periapical XR showing healthy periodontal ligament space with no ankylosis nor resorption.

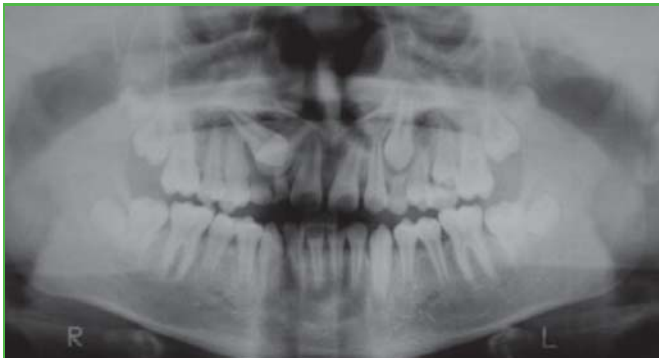

Figure 3a. OPG radiograph showing the dilacerated and displaced 12 and impacted 13

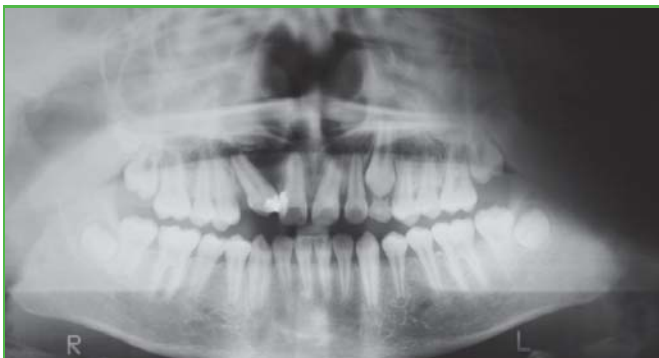

Figure 3b. Post-op OPG of intra-alveolar transplanted 13 after excision of 12.

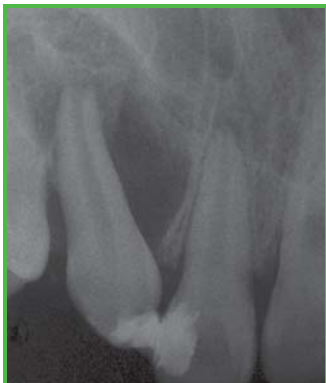
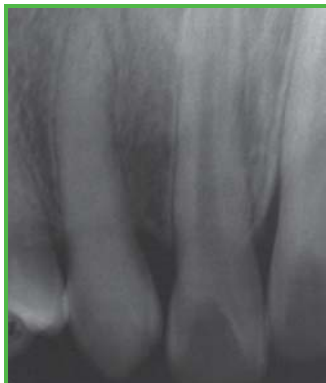
Figure 3c. Periapical XR highlighting the deficiency of mesial bone support adjacent to the transplanted 13, being the void left by the follicle of 12.



3d. Periapical XR 3-year post-op illustrating the deposition of alveolar bone next to the mesial surface of 13 with healthy PDL and lamina dura. Apex growth also completed with obliteration of pulp chamber and root canal.

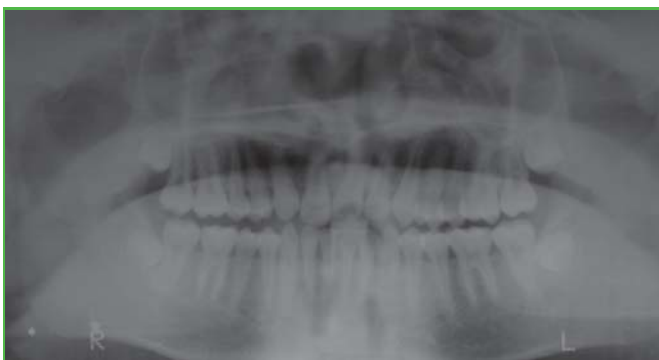

Figure 3e. OPG 3-year post-op showing satisfactory alignment and position of transplanted 13.

References

1. Tuskiboshi M. Autotransplantation of teeth: requirements for predictable success. *Dental traumatology* 2002; 18: 157-180.
2. Tuskiboshi M. Autotransplantation of teeth.
3. Andreasen JO. Periodontal healing after replantation and autotransplantation of incisors in monkeys. *Int J Oral Surg* 1981;10:54-61.
4. Andreasen JO. Relationship between surface and inflammatory resorption and changes in the pulp after replantation of permanent incisors in monkeys. *J Endod* 1981;7:294-301.
5. Andreasen JO. The effect of pulp extirpation or root canal treatment on periodontal healing after replantation of permanent incisors in monkeys. *J Endod* 1981;245-52
6. Andreasen JO, Kristerson L, Andreasen FM. Damage of the Hertwig's epithelial root sheath: effect upon root growth after autotransplantation of teeth in monkeys. *Endod Dent Traumatol* 1988;4:145-51.
7. Andreasen JO. Third molar autotransplantation, relation between successful healing and stage of root development at time of grafting. In: *Proceedings of the Annual Meeting of the Scandinavian Association of Oral and Maxillofacial Surgeons, Nyborg, Denmark; August 15-19,1990.*
8. Clokie CML, Yau DM, Chano L. Autogenous tooth transplantation: An alternative to dental implant placement. *J Can dent Assoc* 2001; 67:92-96.

**DENSPLY**  
FRIADENT

XIVE  
implantology advanced

ANKYLOS  
implantology advanced

Frialit

Biotech Dental Ltd. 拜奥迪牙科有限公司  
Rm.1707, 17/F, Billion Centre, 31 Hung To Road, Kwun Tong, Kowloon, Hong Kong  
E-mail: info@biotech.com.hk Web-site: http://www.biotech.com.hk  
Tel: (852) 2372 9128 Fax: (852) 2790 5826



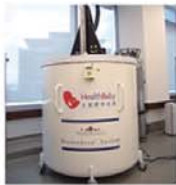**HealthBaby**  
生寶濟帶血庫



# Most Accredited Cord Blood Bank in HK



HK Science Park  
of Technology



BioArchive™  
System



AXP™ AutoXpress™  
System

**AXP™ AutoXpress™**  
*Highest mononuclear cell recoveries*

**+ BioArchive™ System**  
*Precise cryopreservation & retrieval*

---

**= The PERFECT combination of  
stem cell preserve & retrieval system**

HealthBaby is the only cord blood bank:

- ♥ Accredited by HOKLAS and AABB
- ♥ Practices automated processing and storage system
- ♥ Uses high cost liquid nitrogen storage
- ♥ Offers both cord blood and umbilical cord storage
- ♥ Locates at The Hong Kong Science Park of Technology
- ♥ Performs numerous successful cases
- ♥ Enters U.S market

HealthBaby Laboratory is:



HOTLINE: 31888899

www.healthbaby.hk

HK | MACAU | TAIWAN | THAI. | USA



# The Mysterious World of Particle Physics

## Dr. Antonio TONG

BDS, FRACDS, FFDRC SI, FRACDS(OMS), PhD, FCDSHK(OMS), FHKAM(DS)  
Senior Dental Officer, OMS and Dental Unit, Queen Mary Hospital



Dr. Antonio TONG

As medical professionals, we are familiar with various diagnostic imaging modalities and the use of radiation for therapy. Application of diagnostic imaging and treatment modalities including conventional radiography, CT, MR, PET scans, gamma knife, X knife etc., depends on an understanding and control of the fundamental physical processes involved. As 'End-users', we tend to focus on the practical aspects and care less about the fundamental processes involved. The countless efforts of basic research scientists and physicists have benefited the medical profession and our patients. A glimpse into the latest findings in particle physics and cosmology may be interesting.

At the beginning of the last century, the prevailing view amongst scientists was that humans had mastered nearly all the knowledge in Physics. It was thought that all matters in the universe were made up of two fundamental particles, the proton and the electron. Scientists were complacent because the model was simple, symmetrical and aesthetically pleasing. This was soon overturned by the introduction of quantum physics and general relativity. There remained huge gaps in our knowledge and lots of areas for research in physics. Now we know that we might understand less than 5% of our universe!

Scientists investigate the composition of matter simply by smashing it apart, like what curious kids would do to their toys. Hence they construct particle accelerators with ever increasing energies. The purpose of these monstrous machines is to accelerate matters to near the velocity of light (the limiting velocity in the universe) before smashing them apart to find out about the constituents. The Large Hadron Collider (LHC) which had attracted media and public attention recently, is currently the world's largest particle accelerator with the highest energy. It was suggested by the media that it might recreate the condition of the Big Bang and mini black holes. It crosses the border between Switzerland and France. It aims to provide enough collision energy to find a key particle called Higg's Boson which will substantiate the validity of what scientists called the standard model. What is the standard model then?

By the late 1960s, more than a hundred particles apart from the ones we are familiar with (protons, neutrons and electrons) were found and the simple atomic model we learnt was turned into chaos. Through long series of experimental and theoretical studies, order was slowly restored amongst chaos. According to the latest standard model in particle physics, there exists a very simple scheme of two classes of particles - the quarks

and leptons, and a set of fundamental forces that allow them to interact with each other. These 'forces' are regarded as being transmitted through the exchange of particles called gauge bosons. The photon is a gauge boson which transmits the electromagnetic force. These fundamental particles form various combinations that are observed today as neutrons, protons and the various particles seen in particle accelerators.

The following is a simplified scheme of the standard model:

Fundamental particles		
	Quarks	Leptons
Family one	<b>u</b> - up quark <b>d</b> - down quark	<b>e</b> - electron $\nu_e$ - electron neutrino
Family two	<b>c</b> - charm quark* <b>s</b> - strange quark	$\mu$ - muon $\nu_\mu$ - muon neutrino
Family three	<b>t</b> - top quark <b>b</b> - bottom quark	$\tau$ - tau $\nu_\tau$ - tau neutrino
Force carriers (the gauge bosons)		
Force	Relative strength	Gauge boson (carriers)
Strong	1	Gluon
Electromagnetic	1/137	Photon
Weak	$10^{-9}$	$W^+$ , $W^-$ , Z
Gravity	$10^{-38}$	Graviton

The standard model is the theory that describes the role of these particles and the interactions between them to produce the tangible matters in our universe. The names of the particles carry no literal meaning. Scientists just want to give them an identity. Their properties have nothing to do with e.g. positions (up, down) or attractiveness (strange, charm)!

The proton that we are familiar with consists of two up quarks and one down quark, while the neutron consists of two down and one up quark. Thus the up and down quarks together with the lightest lepton - the electron make up most of the known matters of our universe. What then, is the purpose of having the other two families? No one has yet the definite answer. The existence of more than one family of particles was predicted by theorist in the 70s. The 2008 Nobel Prize in Physics was awarded in part to two Japanese physicists - Kobayashi and Maskawa; for predicting the existence of at least 3 families of quarks & leptons in the early 1970s. You have to stay healthy to wait for your Nobel Prize. The particles of the other families were then discovered in particle accelerator experiments. The last one to unfold itself was the top quark, discovered at the FermiLab in Chicago in 1995. Its average lifetime is about 10-25s! Despite its short lifespan, its discovery is an important substantiation of the standard model.



Four fundamental forces mediate the interactions of these particles; electromagnetism, weak nuclear force, strong nuclear force and gravity.

We are most familiar with electromagnetism and gravity in our everyday world. We normally feel only the effect of gravity but not electromagnetic force because the universe is on the whole neutral; i.e. there is a balance of positive and negative charges. Gravity is ubiquitous. It acts on all matters to infinity but is weakest in strength. We can easily overcome the gravitational pull of the whole mass of the earth on any small object by simply picking it up with minimal effort. It is most important in defining the shape and structure of the whole universe. All matters in the universe are bound by gravity. Electromagnetic force also acts to infinity. It differs from gravity in that it can be attractive or repulsive, while gravity always attracts. Electromagnetic force is much stronger than gravity (by 1036 orders of magnitude). We don't feel it because of an exact balance between opposite charges. If a person standing at an arm's length has 1 % excess of electrons than protons, the resulting net electric force would be sufficient to lift the weight of the entire earth! The strong nuclear force binds quarks together and holds neutrons and protons in their atomic nuclei. The weak nuclear force mediates radioactive decay.

There is substantial evidence and experimental basis for the validity of the standard model. If all these seem dull and confusing, the followings might stimulate some sense of awe and points to ponder:

1. One might wonder what the shapes of these particles are. The leptons and quarks have all defined masses. However, they are regarded as points without a volume.
2. A single quark cannot be isolated. Quarks are permanently confined in the protons and neutrons. They carry fractional electric charges. (e.g. up quark charge  $2/3$ , down quark  $-1/3$ ; making up the  $+1$  charge of a proton and neutrality of the neutron).
3. All matters possess particle and wave properties, depending on how we 'look at' them even though in the macroscopic world, we see them usually as particles.
4. The positron used in PET scan is a positive electron, a kind of antimatter. There exist antimatter counterparts to all the matters i.e. antiprotons, antineutrons make up of anti-up, anti-down quarks; antineutrinos etc. They have the same mass but opposite charge to their counterparts. It was believed that matter and antimatter were created from energy in almost equal amounts in the early universe according to the famous Einstein equation  $E = mc^2$  (energy equals mass times the square of velocity of light). Particles and antiparticles are extremely inhospitable. They annihilate each other, turning back into energy. A tiny excess of matter over antimatter in the early universe result in the exclusive presence of matter in the current Universe. For every 109 antimatter particles, there were 109 + 1 matter particles. We owe our existence to this tiny imbalance in ratio.
5. It is believed that all matters in the universe, including space and time were created 13.7 billion years ago in a 'big bang'. Around 10-37 seconds after the moment of creation, the universe underwent a moment of inflation, lasting for 10-32 seconds. During this cosmic eyeblink, the universe expanded exponentially by a factor of 1040 to 10100! The surge in fuel price is nothing compared to cosmic inflation!
6. Why should there be three families of quarks and leptons? The first family makes up all the visible matters in the observable universe. The other two families exist only briefly at the moment of creation of the universe, in some exotic places of the universe, and in man-made particle accelerators. One of the famous remarks was made by Isador I Rabi (Nobel Prize Physics 1944). When the muon was discovered, he exclaimed, "Who ordered that?"
7. There is compelling evidence from current cosmological observations and research which suggest that leptons and quarks make up at most about 4% of the universe. About 22% of the universe is believed to consist of some unknown dark matter, and 74% of the universe consists of some mysterious dark energy. Explaining the nature of dark energy is one of the great mysteries in modern physics. After all, we seem to know only about 4% of the universe.
8. Hydrogen and helium made up all the elements of the early universe. The carbon atoms present in our bodies had to be 'made' by nuclear fusion in the core of one of the first generation of stars. After an explosion of one of these first generation stars in the vicinity of our solar system, a second generation star (our sun) formed under gravity with heavier elements, allowing the formation of planets with elements for life. We are all (the atoms making up our bodies) manufactured and once closely packed in the core of another star!

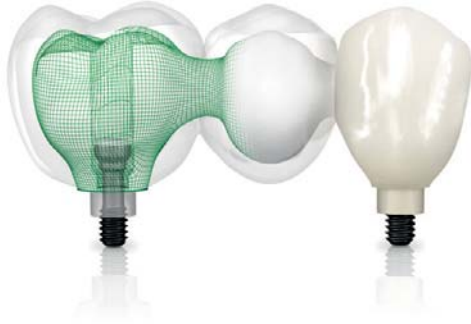In a nutshell, this is a simplified view of the standard model accepted by physicists nowadays. We don't actually need to know the theories behind all these. We might as well stay in our cozy homes to enjoy the benefits of technological advance from other people's effort. If JJ Thomson had not discovered the electron in a small lab in Cambridge in 1897, we will not even have televisions.

\* Professor Samuel Ting (丁肇中), was one of the co-discoverers of the charm quark (Nobel prize in Physics 1976); making up the J particle - after his family name as the letter J in the English alphabet resembles the Chinese character '丁'.



## NobelProcera™

Designed by clinicians for clinicians.



For more information please visit: [www.nobelbiocare.com/nobelprocera](http://www.nobelbiocare.com/nobelprocera)

Nobel Biocare Asia Ltd. 14/F, Cambridge House, Taikoo Place, 979 King's Road, Quarry Bay, Hong Kong. Phone 2845 1266; Fax 2537 6604  
© Nobel Biocare. All rights reserved. [www.nobelbiocare.com](http://www.nobelbiocare.com)



VOLUME 13  
JAN-DEC  
2008

# Stock Sale

The hard bound Medical Diary 2008 is now for sale. For \$150, you can keep a collection of all 12 monthly issues of the Medical Diary for the year. Should you wish to keep a copy, please feel free to contact our Secretariat on 2527 8898 or via email [info@fmshk.org](mailto:info@fmshk.org).



The Federation of Medical Societies of Hong Kong

# Members' Benefits

The Federation, in cooperation with Kingsway Concept Limited, offers a discount on petrol and diesel purchases of HK\$0.9/litre from **Caltex, Shell, Esso and Sinopec** to members and their families of all Ordinary and Associate member societies under the Federation. Please contact our Secretariat on 2527 8898 and [info@fmshk.org](mailto:info@fmshk.org) or Kingsway Concept Limited on 2541 1828 and [kingswayconcept@yahoo.com](mailto:kingswayconcept@yahoo.com) for further details and terms for this offer.



## Oral Surgery Quiz

**Dr. Philip KM LEE**

BDS, MDS(OMS), FFDRCSI, FRACDS, FCDSHK(OMS), FHKAM(DS)

*Specialist in Oral and Maxillofacial Surgery*



Dr. Philip KM LEE

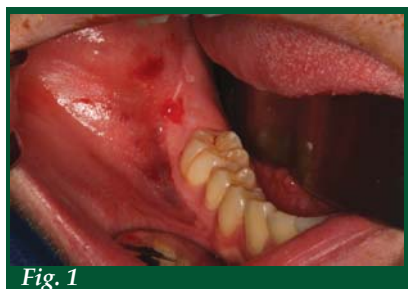

Fig. 1

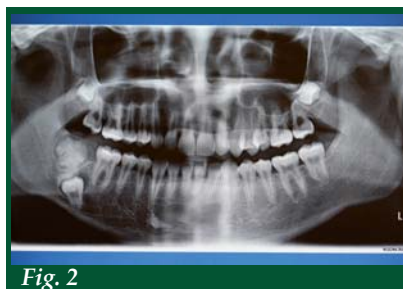


Fig. 2

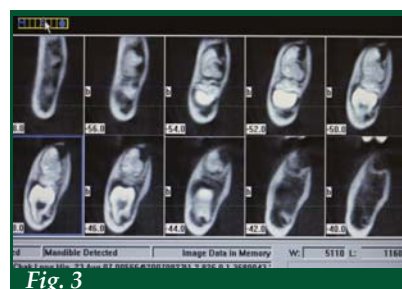


Fig. 3

A 12 years old boy presented with an unerupted lower right second molar.

On presentation, no overt pathology was found intra-orally. The gum was slightly swollen in the right retro-molar area (Fig. 1). OPG radiograph and CT showed a radio-opaque mass above the unerupted lower right second molar (Fig. 2, Fig. 3).

### Questions:

1. What is your diagnosis?
2. What is the appropriate treatment for this lesion?

*(See P. 33 for answers)*

## Society News



### News from Member Societies

#### American College of Chest Physicians (Hong Kong and Macau Chapter Ltd.)

Updated office-bearers for the year 2009-2010 are as follows: President: Dr. Mo-lin WONG; Honorary Secretary: Dr. Johnny Wai-man CHAN; Honorary Treasurer: Dr. Johnny Wai-man CHAN

#### Hong Kong College of Radiologists

Updated office-bearers for the year 2008-2009 are as follows: President: Dr. Chun-key LAW; Honorary Secretary: Dr. Stephen C.W. Cheung; Honorary Treasurer: Dr. Cheuk-man TONG

#### Hong Kong Geriatrics Society

Updated office-bearers for the year 2008-2009 are as follows: President: Dr. Felix CHAN; Honorary Secretary: Dr. Yee-ming WU; Honorary Treasurer: Dr. James LUK

#### Hong Kong Institute of Medical Laboratory Sciences Ltd.

Updated office-bearers for the year 2008-2009 are as follows: President: Mr. Yiu-lam TSIM; Honorary Secretary: Mr. Wing-yin HO; Honorary Treasurer: Mr. Bosco Wan-lung YAU

#### Hong Kong Paediatric Haematology & Oncology Study Group

Updated office-bearers for the year 2009-2010 are as follows: President: Dr. Vincent LEE; Honorary Secretary: Dr. Chak-ho LI; Honorary Treasurer: Dr. Siu-cheung LING

#### Hong Kong Surgical Laser Association

Updated office-bearers for the year 2009-2010 are as follows: Chairman: Dr. Wai-man CHAN; Honorary Secretary: Dr. Mon-ching WONG; Honorary Treasurer: Dr. Chi-kong OR

#### The Hong Kong Society of Community Medicine

Updated office-bearers for the year 2008-2009 are as follows: President: Dr. Ping-yan LAM; Honorary Secretary: Dr. Ho-ching FONG; Honorary Treasurer: Dr. Tonny NG

#### The Hong Kong Society for Infectious Disease

Updated office-bearers for the year 2009-2010 are as follows: President: Dr. Raymond Wai-hung YUNG; Honorary Secretary: Dr. Kin-wing CHOI; Honorary Treasurer: Dr. Wai-keung KWAN

The FMSHK would like to send its congratulations to the new office-bearers and look forward to working together with their societies.



Sunday	Monday	Tuesday	Wednesday	Thursday	Friday	Saturday
<ul style="list-style-type: none"> <li>★ WONCA 2009 Conference: Asia-Pacific Regional Conference</li> <li>★ HKMA Tenpin Bowling Tournament</li> </ul> <p><b>7</b></p>	<ul style="list-style-type: none"> <li>★ Certificate Course on Clinical Teaching and Assessment (Code no: TC-CTA-0902)</li> </ul> <p><b>1</b></p>	<ul style="list-style-type: none"> <li>★ FMSHK Officers' Meeting</li> </ul> <p><b>2</b></p>	<ul style="list-style-type: none"> <li>★ HKMA Kowloon East Community Network - Acneiform Eruptions - Clinical Features and Management</li> <li>★ Introduction to Clinical Molecular Genetics - the Science, Scope and Clinical Applications</li> <li>★ HKMA Choir Rehearsal</li> <li>★ HKMA Orchestra Rehearsal</li> </ul> <p><b>3</b></p>	<ul style="list-style-type: none"> <li>★ HKMA Council Meeting</li> <li>★ Paediatric Infectious Disease &amp; Immunology Course 2009</li> <li>★ WONCA 2009 Conference: Asia-Pacific Regional Conference</li> </ul> <p><b>4</b></p>	<ul style="list-style-type: none"> <li>★ WONCA 2009 Conference: Asia-Pacific Regional Conference</li> <li>★ Joint Surgical Symposium - New Horizon in Endovascular Aortic Grafts</li> <li>★ HKMA KE Network - Certificate Course in Paediatric Infectious Disease &amp; Immunology Course 2009</li> </ul> <p><b>5</b></p>	<ul style="list-style-type: none"> <li>★ WONCA 2009 Conference: Asia-Pacific Regional Conference</li> <li>★ 2nd Annual Scientific Meeting and 3rd Annual General Meeting</li> <li>★ Table Tennis Training Course</li> </ul> <p><b>6</b></p>
<ul style="list-style-type: none"> <li>★ WONCA 2009 Conference: Asia-Pacific Regional Conference</li> <li>★ HKMA Tenpin Bowling Tournament</li> </ul> <p><b>7</b></p>	<ul style="list-style-type: none"> <li>★ Certificate Course on Clinical Teaching and Assessment (Code no: TC-CTA-0902)</li> </ul> <p><b>8</b></p>	<ul style="list-style-type: none"> <li>★ FMSHK Executive Committee Meeting</li> </ul> <p><b>9</b></p>	<ul style="list-style-type: none"> <li>★ Introduction to Clinical Molecular Genetics - the Science, Scope and Clinical Applications</li> <li>★ HKMA Choir Rehearsal</li> <li>★ Hong Kong Neurosurgical Society Monthly Academic Meeting - SPCEAL LECTURE: Swallowing Disorder and Management for Neurosurgical Patients</li> </ul> <p><b>10</b></p>	<ul style="list-style-type: none"> <li>★ HKMA Structured CME Programme with Hong Kong Sanatorium &amp; Hospital Year 2009 (VI) - Management of Kidney Stone</li> </ul> <p><b>11</b></p>	<ul style="list-style-type: none"> <li>★ HKMA Shatin Doctors Network - Certificate Course on Infant Nutrition</li> <li>★ HKPGA Mid-year Scientific Meeting 2009</li> <li>★ Wine Dinner</li> <li>★ HKMA KE Network - Certificate Course in Psychiatry and Psychology for General Practitioners</li> </ul> <p><b>12</b></p>	<ul style="list-style-type: none"> <li>★ Table Tennis Training Course</li> <li>★ Refresher Course for Health Care Providers 2008/ 2009 - Approach to Patient with Postmenopausal Symptoms</li> <li>★ HKMA Orchestra - accompaniment in Die Fledermaus staged by the City Opera</li> </ul> <p><b>13</b></p>
<ul style="list-style-type: none"> <li>★ HKMA Orchestra - accompaniment in Die Fledermaus staged by the City Opera</li> <li>★ HKMA Certificate Course on Family Medicine 2009</li> <li>★ HKMA Table-Tennis Tournament</li> </ul> <p><b>14</b></p>	<ul style="list-style-type: none"> <li>★ Certificate Course on Clinical Teaching and Assessment (Code no: TC-CTA-0902)</li> </ul> <p><b>15</b></p>	<ul style="list-style-type: none"> <li>★ FMSHK Executive Committee Meeting</li> </ul> <p><b>16</b></p>	<ul style="list-style-type: none"> <li>★ Introduction to Clinical Molecular Genetics - the Science, Scope and Clinical Applications</li> <li>★ HKMA Choir Rehearsal</li> </ul> <p><b>17</b></p>	<ul style="list-style-type: none"> <li>★ Hong Kong East Community Network Committee Meeting cum AGM</li> <li>★ Certificate Course on Communication and Swallowing Problems in the Elderly Population</li> <li>★ HKMA KE Network - Certificate Course in Psychiatry and Psychology for General Practitioners</li> </ul> <p><b>19</b></p>	<ul style="list-style-type: none"> <li>★ Table Tennis Training Course</li> <li>★ Certificate Course on Clinical Teaching and Assessment (Code no: TC-CTA-0902)</li> </ul> <p><b>20</b></p>	<ul style="list-style-type: none"> <li>★ Table Tennis Training Course</li> </ul> <p><b>21</b></p>
<ul style="list-style-type: none"> <li>★ HKMA Table-Tennis Tournament</li> <li>★ HKMA Structured CME Programme with PMH Year 2009 (5) - i) Proteinuria &amp; Nephrotic Syndrome in Children ii) Childhood Anaemia</li> </ul> <p><b>28</b></p>	<ul style="list-style-type: none"> <li>★ Certificate Course on Clinical Teaching and Assessment (Code no: TC-CTA-0902)</li> </ul> <p><b>22</b></p>	<ul style="list-style-type: none"> <li>★ FMSHK Executive Committee Meeting</li> </ul> <p><b>23</b></p>	<ul style="list-style-type: none"> <li>★ Introduction to Clinical Molecular Genetics - the Science, Scope and Clinical Applications</li> <li>★ HKMA Choir Rehearsal</li> <li>★ HKMA Orchestra Rehearsal</li> </ul> <p><b>24</b></p>	<ul style="list-style-type: none"> <li>★ HKMA Shatin Doctors Network - Certificate Course on Infant Nutrition</li> <li>★ Certificate Course on Communication and Swallowing Problems in the Elderly Population</li> </ul> <p><b>25</b></p>	<ul style="list-style-type: none"> <li>★ HKMA Shatin Doctors Network - Certificate Course on Infant Nutrition</li> <li>★ Certificate Course on Communication and Swallowing Problems in the Elderly Population</li> </ul> <p><b>26</b></p>	<ul style="list-style-type: none"> <li>★ Table Tennis Training Course</li> </ul> <p><b>27</b></p>
<ul style="list-style-type: none"> <li>★ HKMA Table-Tennis Tournament</li> </ul> <p><b>28</b></p>	<ul style="list-style-type: none"> <li>★ Certificate Course on Clinical Teaching and Assessment (Code no: TC-CTA-0902)</li> </ul> <p><b>29</b></p>	<ul style="list-style-type: none"> <li>★ FMSHK Executive Committee Meeting</li> </ul> <p><b>30</b></p>				





Date / Time	Function	Enquiry / Remarks
<b>1</b> (8,15,20,22,29 Jun, 6 Jul) <b>MON</b>	<b>Certificate Course on Clinical Teaching and Assessment (Code no: TC-CTA-0902)</b> Organised by: College of Nursing, Hong Kong	Secretariat Tel: 2572 9255 Fax: 2838 6280 24 CNE Points
<b>2</b> 8:00 pm - 10:00pm <b>TUE</b>	<b>FMSHK Officers' Meeting</b> Organised by: The Federation of Medical Societies of Hong Kong, Venue: Gallop, 2/F., Hong Kong Jockey Club Club House, Shan Kwong Road, Happy Valley, Hong Kong	Ms. Paulina TANG Tel: 2527 8898 Fax: 2865 0345
<b>3</b> 1:00 pm <b>WED</b> 7:00 pm - 8:30 pm (10,17,24 Jun, 8, 15 Jul)	<b>HKMA Kowloon East Community Network - Acneiform Eruptions - Clinical Features and Management</b> Organised by: HKMA KE Network, Venue: Kwun Tong, Kowloon <b>Introduction to Clinical Molecular Genetics - the Science, Scope and Clinical Applications</b> Organised by: The Federation of Medical Societies of Hong Kong, Speakers: Various, Venue: 4/F, Duke of Windsor Social Service Building, 15 Hennessy Road, Wanchai, Hong Kong 8:00 pm (10,17,24) <b>HKMA Choir Rehearsal</b> Organised by: The Hong Kong Medical Association, Venue: CR1, Hong Kong Cultural Centre 8:00 pm (24) <b>HKMA Orchestra Rehearsal</b> Organised by: The Hong Kong Medical Association, Venue: Pui Ching Education Centre	Miss Alice TANG Tel: 2527 8285 Ms. Erica HUNG Tel: 2527 8898 Fax: 2865 0345 CME / CNE Points Ms. Candy YUEN Tel: 2527 8285 Ms. Candy YUEN Tel: 2527 8285
<b>4</b> 8:00 pm <b>THU</b> (25) (5,6,7)	<b>HKMA Council Meeting</b> Organised by: The Hong Kong Medical Association, Chairman: Dr. H.H. TSE, Venue: HKMA Head Office, 5/F., Duke of Windsor Social Service Building, 15 Hennessy Road, Wanchai, Hong Kong <b>Paediatric Infectious Disease &amp; Immunology Course 2009</b> Organised by: The Hong Kong Society For Paediatric Immunology & Infectious Diseases & Hospital Authority Infectious Disease Centre, Speakers: Various, Venue: Lecture Theatre, H7, Princess Margaret Hospital, Kowloon <b>WONCA 2009 Conference: Asia-Pacific Regional Conference</b> Organised by: The Hong Kong College of Family Physicians, Venue: Hong Kong Convention and Exhibition Centre	Ms. Christine WONG Tel: 2527 8285 Email: idcpidimcourse2009@hotmail.com Charlotte / Patrick Tel: 2528 6618 Email: enquiry@wonca2009.org, Website: http://www.wonca2009.org
<b>5</b> 8:00 am - 9:00 am <b>FRI</b> 1:30 pm (12,19)	<b>Joint Surgical Symposium - New Horizon in Endovascular Aortic Grafts</b> Organised by: Department of Surgery, The University of Hong Kong and Hong Kong Sanatorium & Hospital, Chairman: Dr. SIU Wing-Tai, Speakers: Prof. Stephen CHENG & Dr. CHAN Yiu-Che, Venue: Hong Kong Sanatorium & Hospital, Hong Kong <b>HKMA KE Network - Certificate Course in Psychiatry and Psychology for General Practitioners</b> Organised by: HKMA KE Network, Venue: United Christian Hospital, Kowloon	Department of Surgery, Hong Kong Sanatorium & Hospital Tel: 2835 8698 Fax: 2892 7511 1 CME Point (Active) Miss Alice TANG Tel: 2527 8285
<b>6</b> <b>SAT</b> 4:00 pm (13,20,27)	<b>2nd Annual Scientific Meeting and 3rd Annual General Meeting</b> Organised by: The Hong Kong Society for Paediatric Immunology and Infectious Diseases, Speakers: Dr. Vas NOVELLI & Prof. Nigel KLEIN, Venue: Marco Polo Hong Kong Hotel, Centenary Ballroom, G/F, Harbour City, Tsim Sha Tsui, Kowloon <b>Table Tennis Training Course</b> Organised by: The Hong Kong Medical Association	Ms. Alison SHIEH Tel: 2599 8848 Fax: 2599 8998 Email: shieha@wyeth.com Ms. Dora HO Tel: 2527 8285
<b>7</b> <b>SUN</b> 2:00 pm	<b>HKMA Tenpin Bowling Tournament</b> Organised by: The Hong Kong Medical Association, Venue: South China Athletic Association	Ms. Dora HO Tel: 2527 8285
<b>10</b> <b>WED</b> 7:30 am	<b>Hong Kong Neurosurgical Society Monthly Academic Meeting - SPCEIAL LECTURE: Swallowing Disorder and Management for Neurosurgical Patients</b> Organised by: Hong Kong Neurosurgical Society, Speaker: Ms. Pance KUNG, Venue: Seminar Room, G/F, Block A, Queen Elizabeth Hospital, Kowloon	Dr. Y.C. PO Tel: 2990 3788 Fax: 2990 3789 2 CME Points
<b>11</b> <b>THU</b> 2:00 pm	<b>HKMA Structured CME Programme with Hong Kong Sanatorium &amp; Hospital Year 2009 (VI) - Management of Kidney Stone</b> Organised by: The Hong Kong Medical Association and Hong Kong Sanatorium & Hospital, Speaker: Dr. WONG Wai Sang, HKMA Wanchai Premises, 5/F, Duke of Windsor Social Service Building, 15 Hennessy Road, Wanchai, Hong Kong	Miss Viviane LAM Tel: 2527 8452 1 CME Point
<b>12</b> 1:00 pm (26) 2:00 pm - 6:00 pm <b>FRI</b> 7:30 pm	<b>HKMA Shatin Doctors Network - Certificate Course on Infant Nutrition</b> Organised by: HKMA Shatin Doctors Network, Venue: Shatin <b>HKPGA Mid-year Scientific Meeting 2009</b> Organised by: Hong Kong Psychogeriatric Association Ltd, Venue: Lecture Theatre, G/F, Block P, United Christian Hospital, Kowloon <b>Wine Dinner</b> Organised by: The Hong Kong Medical Association, Venue: The HKMA Dr. Li Shu Pui Professional Education Centre, 2/F, Chinese Club Building, 21-22 Connaught Road Central, Hong Kong	Miss Alice TANG Tel: 2527 8285 Website: www.hkpga.org Email: info@hkpga.org Ms. Dora HO Tel: 2527 8285
<b>13</b> <b>SAT</b> 2:30 pm 8:00 pm (14)	<b>Refresher Course for Health Care Providers 2008/ 2009 - Approach to Patient with Postmenopausal Symptoms</b> Organised by: The Hong Kong Medical Association and Our Lady of Maryknoll Hospital, Chairman: Dr. CHEUNG Wing Wo, Speaker: Dr. LEUNG Tsin Wah, Venue: Training Room II, 1/F, OPD Block, Our Lady of Maryknoll Hospital, 118 Shatin Pass Road, Wong Tai Sin, Kowloon <b>HKMA Orchestra- Accompaniment in Die Fledermaus Staged by the City Opera</b> Organised by: The Hong Kong Medical Association, Venue: Grand Theatre, Hong Kong Cultural Centre	Ms. Clara TSANG Tel: 2354 2440 2 CME Points Ms. Candy YUEN Tel: 2527 8285
<b>14</b> <b>SUN</b> 2:00 pm	<b>HKMA Certificate Course on Family Medicine 2009</b> Organised by: The Hong Kong Medical Association, Speakers: Prof. CHAN Kwok Wai & Dr. WONG Hon Wai Simon, Venue: Lecture Theatre, G/F, Block M, Queen Elizabeth Hospital, Kowloon	Miss Viviane LAM Tel: 2527 8452 3 CME Points



Date / Time	Function	Enquiry / Remarks
<b>14</b> SUN 2:00 pm (28)	<b>HKMA Table-Tennis Tournament</b> Organised by: The Hong Kong Medical Association, Venue: Dr. Stephen Hui Sports Hall, Hong Kong Baptist University, Kowloon	Ms. Dora HO Tel: 2527 8285
<b>16</b> TUE 8:00 pm - 10:00 pm	<b>FMSHK Executive Committee Meeting</b> Organised by: The Federation of Medical Societies of Hong Kong, Venue: Council Chambers, 4/F., Duke of Windsor Social Service Building, 15 Hennessy Road, Wanchai, Hong Kong	Ms. Paulina TANG Tel: 2527 8898 Fax: 2865 0345
<b>19</b> FRI 1:30 pm  7:00 pm - 8:30 pm (26 Jun, 3,10,17,24 Jul)	<b>Hong Kong East Community Network Committee Meeting cum AGM</b> Organised by: Hong Kong East Community Network, Chairman: Dr. S.P. CHIU, HKMA Head Office, 5/F., Duke of Windsor Social Service Building, 15 Hennessy Road, Wanchai, Hong Kong  <b>Certificate Course on Communication and Swallowing Problems in the Elderly Population</b> Organised by: The Federation of Medical Societies of Hong Kong & The Hong Kong Association of Speech Therapists, Speakers: Various, Venue: 4/F, Duke of Windsor Social Service Building, 15 Hennessy Road, Wanchai, Hong Kong	Miss Alice TANG Tel: 2527 8285  Ms. Erica HUNG Tel: 2527 8898 Fax: 2865 0345 CME / CNE Points
<b>28</b> SUN 2:00 pm	<b>HKMA Structured CME Programme with PMH Year 2009 (5) - i) Proteinuria &amp; Nephrotic Syndrome in Children ii) Childhood Anaemia</b> Organised by: The Hong Kong Medical Association, Speaker: Dr. CHIU Man Chun & Dr. LI Chi Keung, Venue: G8 Hall, Princess Margaret Hospital, Kowloon	Miss Viviane LAM Tel: 2527 8452 2 CME Points

## Meetings

18/7/2009	<b>Hong Kong Surgical Forum - Summer 2009: Minimally Invasive Surgery</b> Organised by: Department of Surgery, Li Ka Shing Faculty of Medicine, The University of Hong Kong; Queen Mary Hospital & Hong Kong Chapter of American College of Surgeons, Venue: Underground Lecture Theatre, New Clinical Building, Queen Mary Hospital, Pokfulam, Hong Kong, Enquiry: Forum Secretary, Hong Kong Surgical Forum, Tel: (852) 2855 4885 / (852) 2855 4886, Fax: (852) 2819 3416, E-mail: hksf@hkucc.hku.hk, Web-site: <a href="http://www3.hku.hk/surgery/forum.php">http://www3.hku.hk/surgery/forum.php</a>
8/11/2009	<b>International Symposium on Hepatology 2009 / 22nd Annual Scientific Meeting</b> Organised by: The Hong Kong Association for the Study of Liver Diseases, Venue: Hong Kong Convention and Exhibition Centre, Enquiry: Ms. Melissa LEUNG, CMPMedica Pacific Limited, Tel: 2116 4348, E-mail: <a href="mailto:melissa.leung@asia.cmpmedica.com">melissa.leung@asia.cmpmedica.com</a>

## Courses

7/7/2009	<b>Care at the Moment of Death (Code no. SE-CMD-0902)</b> Organised by: College of Nursing, Hong Kong, Speaker: Ms. SHIU Sin Man Vicky, Enquiry: Secretariat, Tel: 2572 9255, Fax: 2838 6280, 3 CNE points
18&26/7/2009, 19&27/9/2009, 21&29/11/2009	<b>Pre-Hospital Trauma Life Support (PHTLS) Provider Course</b> Organised by: Department of Surgery, Queen Mary Hospital; Hong Kong Chapter of the American College of Surgeons & Hong Kong St. John Ambulance Association, Venue: St. John Ambulance Association, 2 Macdonnell Road, Mid-Levels, Hong Kong, Enquiry: Hong Kong St. John Ambulance Association, Tel: 2530 8020, Email: <a href="mailto:assn@stjohn.org.hk">assn@stjohn.org.hk</a> , Web site: <a href="http://www.hku.hk/surgery">http://www.hku.hk/surgery</a>
14-16/8/2009, 11-13/9/2009, 20-22/11/2009	<b>Advanced Trauma Life Support (ATLS) Student Course</b> Organised by: Department of Surgery, Queen Mary Hospital & Hong Kong Chapter of the American College of Surgeons, Venue: The Jockey Club Skills Development Centre, C3, Main Block, Queen Mary Hospital, Pokfulam, Hong Kong, Enquiry: Course Administrator, Tel: 2855 4885 / 2855 4886, Fax: 2819 3416, Email: <a href="mailto:hnsrg@hkucc.hku.hk">hnsrg@hkucc.hku.hk</a> , Web site: <a href="http://www.hku.hk/surgery">http://www.hku.hk/surgery</a>
15,22,29/8/2009 2,9/9/2009	<b>Certificate Course on Clinical Teaching and Assessment (Code no: TC-CTA-0903)</b> Organised by: College of Nursing, Hong Kong, Enquiry: Secretariat, Tel: 2572 9255, Fax: 2838 6280, 24 CNE points
11-12/9/2009, 20-21/11/2009	<b>Advanced Trauma Care for Nurses (ATCN) Provider Course</b> Organised by: Department of Surgery, Queen Mary Hospital & Hong Kong Chapter of the American College of Surgeons Venue: The Jockey Club Skills Development Centre, C3, Main Block, Queen Mary Hospital, Pokfulam, Hong Kong Enquiry: Course Administrator Tel: 2855 4885 / 2855 4886 Fax: 2819 3416 Email: <a href="mailto:hnsrg@hkucc.hku.hk">hnsrg@hkucc.hku.hk</a> Web site: <a href="http://www.hku.hk/surgery">http://www.hku.hk/surgery</a>
12-13/12/2009	<b>Advanced Medical Life Support (AMLS) Provider Course</b> Organised by: Department of Surgery, Queen Mary Hospital & Hong Kong Chapter of the American College of Surgeons, Venue: The Jockey Club Skills Development Centre, C3, Main Block, Queen Mary Hospital, Pokfulam, Hong Kong, Enquiry: Course Administrator, Tel: 2855 4885 / 2855 4886, Fax: 2819 3416, Email: <a href="mailto:hnsrg@hkucc.hku.hk">hnsrg@hkucc.hku.hk</a> Web site: <a href="http://www.hku.hk/surgery">http://www.hku.hk/surgery</a>

## Upcoming Certificate Courses of the Federation of Medical Societies of Hong Kong

Date	Course No	Course Name	Co-organiser	Target Participants
3 Jun 09 - 15 Jul 09 (Every Wed)	C142	Introduction to Clinical Molecular Genetics - the Science, Scope and Clinical Applications	Nil	Medical and Other Healthcare Providers
6 Jun 09 - 13 Jun 09 (Every Sat)	C144	The Changing Face of Medical/Dental Practice	Wellex Consultancy Limited	Medical and Dental Practitioners
19 Jun 09 - 24 Jul 09 (Every Fri)	C143	Certificate Course on Communication and Swallowing Problems in the Elderly Population	The Hong Kong Association of Speech Therapists	Medical and Health Professionals
22 Jul 09 - 26 Aug 09 (EveryWed)	C149	Certificate Course on Measures Against Drug Abuse in School	Nil	Teachers and Social Workers
6 Aug 09 - 10 Sep 09 (Every Thu)	C141	Certificate Course on Wilderness Medicine	Hong Kong Society for Emergency Medicine and Surgery	Healthcare Professionals
2 Sep 09 - 7 Oct 09 (Every Wed)	C148	Certificate Course on Clinical Ophthalmology	The Hong Kong Ophthalmological Society	General Practitioners and Allied Health Professions
8 Oct 09 - 12 Nov 09 (Every Thu)	C146	Certificate Course on Management of Common Psychiatric Disorders	The Hong Kong College of Psychiatrists	Medical and Health Professionals
4 Nov 09 - 9 Dec 09 (Every Wed)	C145	Certificate Course on Sports Medicine and Emergencies	Hong Kong Society for Emergency Medicine and Surgery	Medical and Health Professionals



## Answer to Oral Surgery Quiz

1. This is quite a typical presentation of a Complex Odontoma. Odontomas are known as mixed odontogenic tumours because they are composed of tissue that is of both epithelial and mesenchymal origin. These tissues become fully differentiated, resulting in deposition of enamel by ameloblasts and dentin by odontoblasts respectively. Although these cells and tissues appear normal, the architecture is defective. Odontomas are lesions of children and young adults; mostly discovered in the second decade of life. There are two general configurations. They may appear as numerous miniature or rudimentary teeth, in which case they are known as compound odontomas, or they may appear as amorphous conglomerations of hard tissue, as in this case, they are known as Complex Odontoma.
2. The treatment of choice is surgical enucleation. Recurrence is not a problem. Any associated unerupted tooth will need monitoring for their eruption. The unerupted tooth may require orthodontic traction for eruption or indicated for extraction if there is too much impaction as in this case (Fig.4).

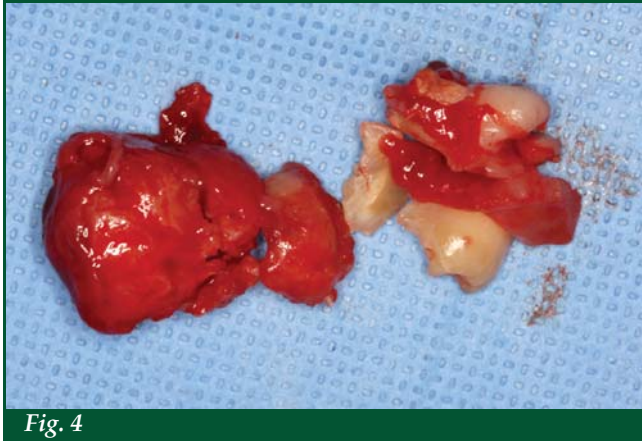

Fig. 4

### Dr. Philip KM LEE

BDS, MDS(OMS), FFDRCSI, FRACDS, FCDSHK(OMS), FHKAM(DS)  
Specialist in Oral and Maxillofacial Surgery

### The Federation of Medical Societies of Hong Kong

4/F Duke of Windsor Social Service Building,  
15 Hennessy Road, Wanchai, Hong Kong  
Tel: 2527 8898 Fax: 2865 0345

<b>Patron</b>	
The Honourable Donald TSANG, GBM	曾蔭權先生
<b>President</b>	
Dr. FONG To-sang, Dawson	方道生醫生
<b>1st Vice-President</b>	
Dr. LO See-kit, Raymond	勞思傑醫生
<b>2nd Vice-President</b>	
Dr. LO Sze-ching, Susanna	盧時楨醫生
<b>Hon. Treasurer</b>	
Mr. LAM Lop-chi, Nelson	林立志先生
<b>Deputy Hon. Treasurer</b>	
Mr. LEE Cheung-mei, Benjamin	李祥美先生
<b>Hon. Secretary</b>	
Dr. CHAN Sai-kwing	陳世炯醫生
<b>Executive Committee Members</b>	
Dr. CHAN Chi-fung, Godfrey	陳志峰醫生
Dr. CHAN Chi-kuen	陳志權醫生
Dr. CHAN Hau-ngai, Kingsley	陳厚毅醫生
Dr. CHIM Chor-sang, James	詹楚生醫生
Dr. CHOI Kin	蔡堅醫生
Dr. LEE Kin-man, Philip	李健民醫生
Dr. MAN Chi-wai	文志衛醫生
Dr. MOK Chun-on	莫鎮安醫生
Dr. MUI, Winnie	梅麥惠華醫生
Dr. NG Yin-kwok	吳賢國醫生
Dr. YU Chau-leung, Edwin	余秋良醫生
Dr. YU Kong-san	俞江山醫生

### Founder Members

#### British Medical Association (HongKong Branch)

#### 英國醫學會(香港分會)

<b>President</b>	
Dr. WU, Adrian	鄔揚源醫生
<b>Vice-President</b>	
Dr. LO See-kit, Raymond	勞思傑醫生
<b>Hon. Secretary</b>	
Dr. LI, Anthony	李志毅醫生
<b>Hon. Treasurer</b>	
Dr. LEUNG, Clarence	梁顯信醫生
<b>Council Representatives</b>	
Dr. LO See-kit, Raymond	勞思傑醫生
Dr. CHEUNG Tse-ming	張子明醫生
Tel: 2527 8898 Fax: 2865 0345	

#### The Hong Kong Medical Association

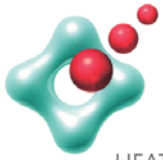#### 香港醫學會

<b>President</b>	
Dr. TSE Hung-hing	謝鴻興醫生
<b>Vice-Presidents</b>	
Dr. CHAN Yee-shing, Alvin	陳以誠醫生
Dr. CHOW Pak-chin	周伯展醫生
<b>Hon. Secretary</b>	
Dr. LO Chi-fung, Ernie	羅智峰醫生
<b>Hon. Treasurer</b>	
Dr. LEUNG Chi-chiu	梁子超醫生
<b>Council Representatives</b>	
Dr. CHAN Yee-shing	陳以誠醫生
Dr. CHOI Kin	蔡堅醫生
<b>Chief Executive</b>	
Mrs. LEUNG, Yvonne	梁周月美女士
Tel: 2527 8285 (General Office)	
2527 8324 / 2536 9388 (Club House in Wanchai / Central)	
Fax: 2865 0943 (Wanchai), 2536 9398 (Central)	
Email: hkma@hkma.org	
Website: http://www.hkma.org	

#### The HKFMS Foundation Limited

#### 香港醫學組織聯會基金

<b>Board of Directors</b>	
<b>President</b>	
Dr. FONG To-sang, Dawson	方道生醫生
<b>1st Vice-President</b>	
Dr. LO See-kit, Raymond	勞思傑醫生
<b>2nd Vice-President</b>	
Dr. LO Sze-ching, Susanna	盧時楨醫生
<b>Hon. Treasurer</b>	
Mr. LAM Lop-chi, Nelson	林立志先生
<b>Hon. Secretary</b>	
Dr. CHAN Sai-kwing	陳世炯醫生
<b>Directors</b>	
Dr. CHAN Chi-kuen	陳志權醫生
Mr. CHAN Yan-chi, Samuel	陳恩賜先生
Dr. CHIM Chor-sang, James	詹楚生醫生
Mr. LEE Cheung-mei, Benjamin	李祥美先生
Dr. WONG Mo-lin, Maureen	黃慕蓮醫生

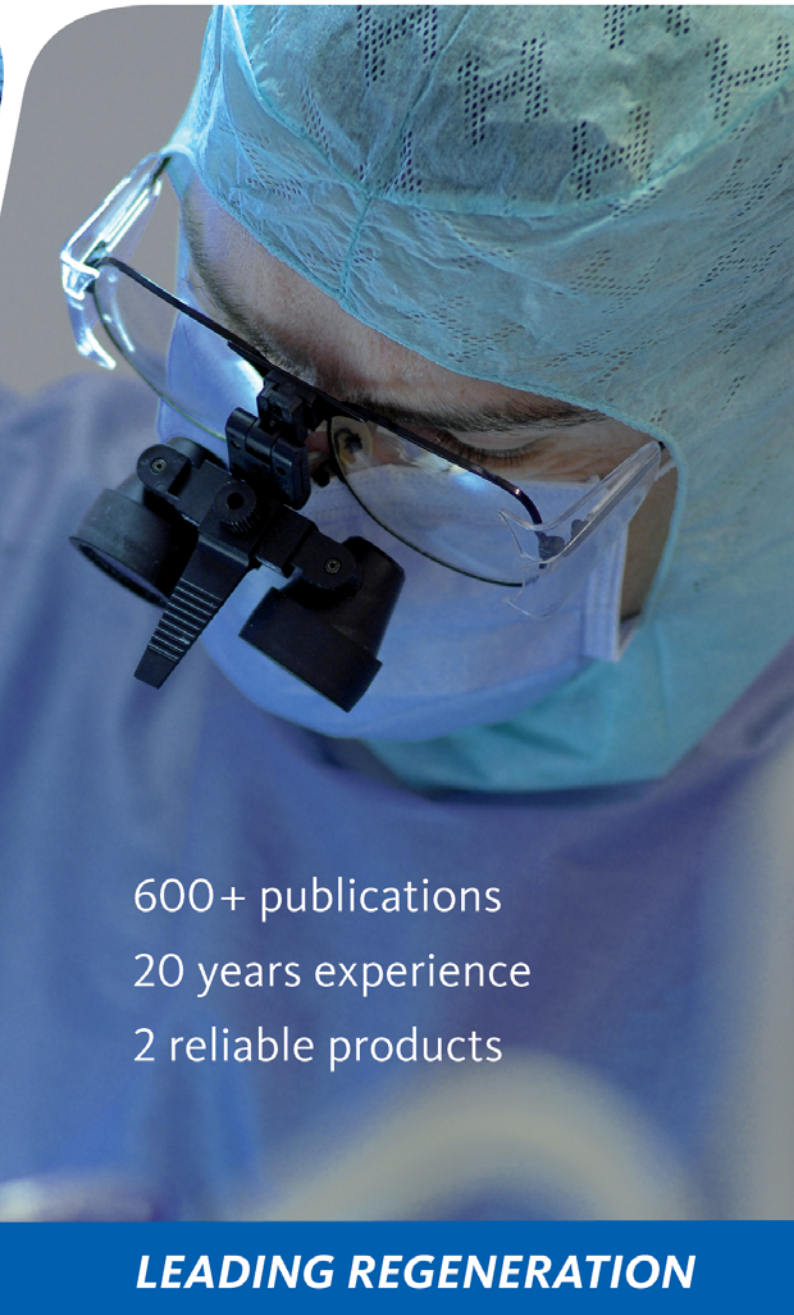

HEAT Consultancy Co. Ltd.  
1912-13, The Centre  
99 Queen's Road Central  
Hong Kong  
Tel. (852) 2851 4888  
Fax (852) 2581 3880  
Mobile (852) 6823 1608

Geistlich  
**Bio-Gide**<sup>®</sup>

Geistlich  
**Bio-Oss**<sup>®</sup>

# The Master's Choice



600+ publications  
20 years experience  
2 reliable products

**LEADING REGENERATION**