



[www.fmshk.org](http://www.fmshk.org)

THE HONG KONG 香港醫訊  
*MEDICAL DIARY*

VOL.23 NO.3 March 2018

*Ophthalmology*





In patients with visual impairment due to DME\*...

# START STRONG STAY STRONG

## START STRONG

EYLEA® provides **strong, increasing** vision gains over the course of 5 initial monthly doses<sup>1</sup>

## STAY STRONG

In EYLEA pivotal trials, patients maintained Year 1 mean vision gains of **>10 letters** through 148 weeks<sup>1,2</sup>

## UNIQUE MOA

EYLEA was designed to **inhibit both VEGF and PGF** by binding with **greater affinity** than each of their **natural receptors**<sup>3</sup>



\* DME - Diabetic Macular Edema

### Abbreviated Prescribing Information

Eylea® 40 mg/ml solution for injection in a vial (aflibercept)

Refer to full prescribing information before prescribing.

**Presentation:** 1 ml solution for intravitreal injection contains 40 mg

aflibercept. Each vial contains 100 microdoses, equivalent to 4 mg aflibercept.

**Indication:** (1) Treatment of neovascular (wet) age-related macular degeneration (AMD), visual impairment due to diabetic macular oedema (DME) in adults, and visual impairment due to myopic choroidal neovascularisation (myopic CNV).

**Dose and method of administration:** For intravitreal injection only. It must only be administered by a qualified physician experienced in administering intravitreal injections. Each vial should only be used for the treatment of a single eye. The vial contains more than the recommended dose of 2 mg aflibercept. The extractable volume of the vial (100 microdoses) is not to be used in total. The excess volume should be expelled before injecting. The recommended dose is 2 mg aflibercept, equivalent to 50 microdoses. Wet AMD treatment is initiated with one injection per month for three consecutive doses, followed by one injection every two months. No requirement for monitoring between injections. After the first 12 months of treatment, and based on visual and/or anatomic outcomes, treatment interval may be extended, such as with a treat-and-extend dosing regimen, where the treatment intervals are gradually increased to maintain stable visual and/or anatomic outcomes; however, there are insufficient data to conclude on the length of these intervals. If visual and/or anatomic outcomes deteriorate, the treatment interval should be shortened accordingly. For macular oedema secondary to RVO, after the initial injection, treatment is given monthly at intervals not shorter than one month. Monthly treatment continues until maximum visual acuity is achieved and/or there are no signs of disease activity. Three or more consecutive, monthly injections may be needed. Treatment should be discontinued if visual and anatomic outcomes indicate that the patient is not benefiting from continued treatment. Treatment may be continued with a treat-and-extend dosing regimen, where the treatment intervals are gradually increased to maintain stable visual and/or anatomic outcomes; however, there are insufficient data to conclude on the length of these intervals. If visual and/or anatomic outcomes deteriorate, the treatment interval should be shortened accordingly. Monitoring for disease activity includes clinical examination, functional testing or imaging techniques (e.g. optical coherence tomography or fluorescein angiography). For DME, initiate treatment with one injection per month for five consecutive doses, followed by one injection every two months. No requirement for monitoring between injections. After the first 12 months of treatment, and based on visual and/or anatomic outcomes, the treatment interval may be extended, such as with a treat-and-extend dosing regimen, where the treatment intervals are gradually increased to maintain stable visual and/or anatomic outcomes; however, there are insufficient data to conclude on the length of these intervals. If visual and/or anatomic outcomes deteriorate, the treatment interval should be shortened accordingly. The schedule for monitoring should be determined by the treating physician and may be more frequent than the schedule of injections. If visual and anatomic outcomes indicate that the patient is not benefiting from continued treatment, treatment should be discontinued.

**Contraindications:** Hypersensitivity to active substance or any excipients; active or suspected ocular or periorbital infection; active severe intracocular inflammation.

**Warnings & precautions:** As with other intravitreal therapies, endophthalmitis, intracocular inflammation, rhegmatogenous retinal detachment, retinal tear and iatrogenic traumatic cataract have been reported. Aseptic injection techniques should always be used in all patients during the week following the injection to permit early treatment if an infection occurs. Patients must report any symptoms of endophthalmitis without delay. Increases in intraocular pressure have been seen within 60 minutes of intravitreal injection; special precaution is needed in patients with poorly controlled glaucoma (do not inject while the intraocular pressure is  $\geq 30$  mmHg). Both intraocular pressure and perfusion of optic nerve head must be monitored and managed appropriately. There is a potential for immunogenicity as with other therapeutic proteins; patients should report any signs or symptoms of intracocular inflammation e.g. pain, photophobia or redness, which may be a clinical sign of hypersensitivity. Systemic adverse events (including intracocular haemorrhages and several thromboembolic events) following intravitreal injection of VEGF inhibitors have been reported. Safety and efficacy of concurrent use in both eyes have not been systematically studied. Caution in patients with risk factors for development of retinal pigment epithelial tears including large and/or high pigment epithelial retinal detachment. Without treatment in patients with rhegmatogenous retinal detachment or stage 3 or 4 macular holes, with retinal break and do not resume treatment until the break is adequately repaired. Without treatment and do not resume before next scheduled treatment if there is: decrease in best corrected visual acuity of  $\geq 30$  letters compared with the last assessment; central foveal subretinal haemorrhage, or haemorrhage  $\geq 50\%$  of total lesion area. Do not treat in the 28 days prior to or following performed or planned intracocular surgery. Eylea should not be used in pregnancy unless the potential benefit outweighs the potential risk to the foetus. Women of childbearing potential have to use effective contraception during treatment and for at least 3 months after the last intravitreal injection. Populations with limited data: There is limited experience of treatment with Eylea in patients with ischaemic CRVO and BRVO. There are limited data on safety in the treatment of patients with CRVO, BRVO, DME or myopic CNV with a history of stroke or transient ischaemic attacks or myocardial infarction within the last 6 months. Caution should be exercised when treating such patients. There is no data available on the concomitant use of Eylea with other anti-VEGF medicinal products (systemic or ocular). In patients presenting with clinical signs of irreversible ischaemic visual function loss, the treatment is not recommended. There is limited experience in subjects with DME due to type 1 diabetes or in diabetic patients with an HbA1c over 12% or with proliferative diabetic retinopathy. Eylea has not been studied in patients with active systemic infections, with concurrent eye conditions such as retinal detachment or macular hole, or in diabetic patients with uncontrolled hypertension. This lack of information should be considered when treating such patients. In myopic CNV there is no experience with Eylea in the treatment of non-Asian patients, patients who have previously undergone treatment for myopic CNV, and patients with extrafoveal lesions.

**Undesirable effects:** Very common visual acuity reduced, conjunctival haemorrhage, eye pain. Common: retinal detachment, vitreous detachment, injection site pain, foreign body sensation in eyes, increased lacrimation, eyelid oedema, injection site haemorrhage, punctate keratitis, conjunctival or ocular hyperaemia. Uncommon: hypersensitivity, endophthalmitis, retinal detachment, vitreal tear, floaters, vitritis, iridocyclitis, lenticular opacities, corneal epithelium defect, injection site irritation, abnormal sensation in eye, eyelid irritation, anterior chamber flare, corneal oedema. Rare: blindness, cataract, traumatic vitritis, hypotony.

**Special Precautions for Storage:** Store in a refrigerator (2°C to 8°C). Do not freeze. Unopened vials may be kept at room temperature (below 25°C) for up to 24 hours before use. After opening the vial, proceed under aseptic conditions. Keep the vial in the outer carton in order to protect from light.

For further prescribing information, please contact: Bayer HealthCare Limited, Nos. 803-808, 8/F, Shui On Centre, 6-8 Harbour Road, Wanchai, Hong Kong. Tel: (852) 2814 7337. Fax: (852) 3526 4755

**References:** 1. KOROBELNIK JF, DO DV, SCHMIDT-ERLURTH U, ET AL. INTRAVITREAL AFLIBERCEPT FOR DIABETIC MACULAR EDEMA. OPTHALMOLOGY 2014;121(11):2247-2254. 2. Heier JS, Korobelnik JF, Brown DM, et al. Intravitreal aflibercept for Diabetic Macular Edema. 148-Week Results from the VISTA and VWD Studies Ophthalmology, 2016;123(11):2376-2385. 3. EYLEA® (aflibercept) solution for injection Full Prescribing Information, Hong Kong August 2016.







## Contents

Editorial		Life Style	
■ Editorial	2	■ Walking With the Poor Communities	33
<i>Dr Ian YH WONG</i>		<i>Dr Nim-chung CHAN</i>	
Medical Bulletin		Dermatological Quiz	
■ Updates on Treatment Options for Keratoconus	4	■ Dermatological Quiz	40
<i>Dr Alex LK NG &amp; Dr Arthur CK CHENG</i>		<i>Dr Chi-keung KWAN</i>	
■ MCHK CME Programme Self-assessment Questions	7	Medical Diary of March	
■ Current Trends in the Management of Thyroid Eye Disease	9	38	
<i>Dr Emmy Yuen-mei LI</i>		Calendar of Events	
■ Minimally Invasive Glaucoma Surgery	16	39	
<i>Dr Jonathan CHAN &amp; Dr Jasper WONG</i>			
■ Demyelinating and inflammatory optic neuropathies: an overview	24		
<i>Dr Jonathan Chun-ho HO &amp; Dr Andy Chi-on CHENG</i>			
■ Latest Measures in Controlling Myopia Progression in Children	28		
<i>Dr Patrick Kai-wah WU</i>			



### Scan the QR-code

To read more about  
The Federation of Medical  
Societies of Hong Kong

## Disclaimer

All materials published in the Hong Kong Medical Diary represent the opinions of the authors responsible for the articles and do not reflect the official views or policy of the Federation of Medical Societies of Hong Kong, member societies or the publisher.

Publication of an advertisement in the Hong Kong Medical Diary does not constitute endorsement or approval of the product or service promoted or of any claims made by the advertisers with respect to such products or services.

The Federation of Medical Societies of Hong Kong and the Hong Kong Medical Diary assume no responsibility for any injury and/or damage to persons or property arising from any use of execution of any methods, treatments, therapy, operations, instructions, ideas contained in the printed articles. Because of rapid advances in medicine, independent verification of diagnoses, treatment method and drug dosage should be made.

## The Cover Shot



This *Euphrates Poplar*, or desert poplar, was taken at the 'Strange-tree forest' in the Ejina County of the Inner Mongolia Autonomous Region of China, which is located in the Gobi Desert near the border neighbouring Mongolia.

The desert poplar has leaves of variable sizes and shapes, ranging from spindle shape, heart shape, and sometimes resembling that of a maple leaf. This plant is usually found in the deserts in Inner Mongolia and parts of the United States only. Its colour is usually green most time of the year, but turns golden-yellow for a few weeks around October during the 'Poplar Festival'.



**Dr Ian YH WONG**

MBBS (HKU),  
M.Med (Singapore),  
FCOphthHK,  
FHKAM (Ophthalmology),  
FRCSEd, FRCOphth  
*Clinical Associate Professor,  
LKS Faculty of Medicine,  
The University of Hong Kong*



**Published by**  
The Federation of Medical Societies of Hong Kong

**EDITOR-IN-CHIEF**

Dr MOK Chun-on  
莫鎮安醫生

**EDITORS**

Prof CHAN Chi-fung, Godfrey  
陳志峰教授 (Paediatrics)  
Dr CHAN Chi-kuen  
陳志權醫生 (Gastroenterology & Hepatology)  
Dr KING Wing-keung, Walter  
金永強醫生 (Plastic Surgery)  
Dr LO See-kit, Raymond  
勞思傑醫生 (Geriatric Medicine)

**EDITORIAL BOARD**

Dr AU Wing-yan, Thomas  
區永仁醫生 (Haematology and Haematological Oncology)  
Dr CHAK Wai-kwong  
翟偉光醫生 (Paediatrics)  
Dr CHAN Chun-kwong, Jane  
陳真光醫生 (Respiratory Medicine)  
Dr CHAN Hau-ngai, Kingsley  
陳厚毅醫生 (Dermatology & Venereology)  
Dr CHAN, Norman  
陳諾醫生 (Diabetes, Endocrinology & Metabolism)  
Dr CHEUNG Fuk-chi, Eric  
張復熾醫生 (Psychiatry)  
Dr CHIANG Chung-seung  
蔣忠想醫生 (Cardiology)  
Prof CHIM Chor-sang, James  
詹楚生教授 (Haematology and Haematological Oncology)  
Dr CHONG Lai-yin  
莊禮賢醫生 (Dermatology & Venereology)  
Dr CHUNG Chi-chiu, Cliff  
鍾志超醫生 (General Surgery)  
Dr FONG To-sang, Dawson  
方道生醫生 (Neurosurgery)  
Dr HSUE Chan-chee, Victor  
徐成之醫生 (Clinical Oncology)  
Dr KWOK Po-yin, Samuel  
郭寶賢醫生 (General Surgery)  
Dr LAM Siu-keung  
林兆強醫生 (Obstetrics & Gynaecology)  
Dr LAM Wai-man, Wendy  
林慧文醫生 (Radiology)  
Dr LEE Kin-man, Philip  
李健民醫生 (Oral & Maxillofacial Surgery)  
Dr LEE Man-piu, Albert  
李文彪醫生 (Dentistry)  
Dr LI Fuk-him, Dominic  
李福謙醫生 (Obstetrics & Gynaecology)  
Prof LI Ka-wah, Michael, BBS  
李家驊醫生 (General Surgery)  
Dr LO Chor Man  
盧礎文醫生 (Emergency Medicine)  
Dr LO Kwok-wing, Patrick  
盧國榮醫生 (Diabetes, Endocrinology & Metabolism)  
Dr MA Hon-ming, Ernest  
馬漢明醫生 (Rehabilitation)  
Dr MAN Chi-wai  
文志衛醫生 (Urology)  
Dr NG Wah Shan  
伍華山醫生 (Emergency Medicine)  
Dr PANG Chi-wang, Peter  
彭志宏醫生 (Plastic Surgery)  
Dr TSANG Kin-lun  
曾建倫醫生 (Neurology)  
Dr TSANG Wai-kay  
曾偉基醫生 (Nephrology)  
Dr WONG Bun-lap, Bernard  
黃品立醫生 (Cardiology)  
Dr YAU Tsz-kok  
游子覺醫生 (Clinical Oncology)  
Prof YU Chun-ho, Simon  
余俊豪教授 (Radiology)  
Dr YUEN Shi-yin, Nancy  
袁淑賢醫生 (Ophthalmology)

**Design and Production**

A-PRO MULTIMEDIA LTD www.apro.com.hk

# Editorial

## Dr Ian YH WONG

MBBS (HKU), M.Med (Singapore), FCOphthHK, FHKAM (Ophthalmology), FRCSEd, FRCOphth

Clinical Associate Professor,  
LKS Faculty of Medicine, The University of Hong Kong



Dr Ian YH WONG

**Editor**

In the last two decades, the medical world has witnessed dramatic advancements in ophthalmology. From imaging advancements to new therapeutic agents and strategies, many eye diseases which were not amenable to treatment can now be treated, or at least, enable us to have a better understanding of the underlying pathophysiology. In this issue of the Hong Kong Medical Diary, we have gathered experts in the various subspecialty areas within ophthalmology, to summarise various important disease entities for our readers.

One of the major advancements in recent years has been the development of minimally invasive glaucoma surgery (MIGS), which has been a popular and promising new treatment in the management of glaucoma. This was made possible by the advancements in the manufacturing technology such that these micro devices could be made with precision. In this issue, Dr Jonathan Chan and Dr Jasper Wong have provided a comprehensive account of this new development.

Another important advancement is the use of collagen cross-linking in the treatment of corneal diseases. This technology enhances cross-linking bonding formation between corneal stromal collagen fibrils and increases the overall strength and stability of the cornea. It has been implemented in the treatment of corneal conditions such as keratoconus. Dr Alex Ng and Dr Arthur Cheng have together written a very in-depth review of this new technique, and how it has transformed the management of keratoconus in recent years.

With the advancement in laboratory diagnosis, discovery of novel serum antibodies was made possible. Following the discovery of the serum antibodies against water channel protein aquaporin-4 (AQP4) in patients with neuromyelitis optica (NMO) in 2005, NMO has now proven itself to be a separate disease entity with distinct clinical features. In this issue, Dr Jonathan Ho and Dr Andy Cheng have together written a comprehensive review of NMO, along with a few other neuro-ophthalmological conditions.

Another major development in recent years is the use of atropine in the control of myopia progression. Since the early 1960s atropine was found to be able to retard the progression of myopia in both animal and human studies. However, the use of the standard dosage of 1% inevitably produces pupil dilation, thus resulting in photophobia and inability to accommodate. This prevents the practical use of atropine and thus popularity is low. Only until recently the use of atropine in retarding myopia progression has been revisited. This was largely due to the findings in the ATOM1 and ATOM2 studies in Singapore, which found that the use of 0.01% atropine was well tolerated without the noticeable side effects but at the same time able to achieve a significantly lower rate of progression in the same period when compared to other higher concentrations such as 0.1% and 0.5%. This re-ignited the enthusiasm of the scientific world in the search of the holy grail in preventing myopia progression. In this issue, Dr Patrick Wu has reviewed and summarised the latest measures in this regard.






Dr Emmy Li has given a very detailed account of the latest updates on the management of thyroid eye disease. The clinical features and grading system are revisited, and the measures to control the disease discussed. This enables non-ophthalmologists to grasp the fundamentals in the management of the ocular manifestation of this important systemic condition.

Last but not least, in the Life Style section, Dr Nim-chung Chan has shared with us his legendary days spent in Afghanistan before the Taliban came to power, where he helped to train the local ophthalmologists, and to serve the poor and needy. He also shares his experience in Myanmar where he and his wife have helped to setup local medical facilities in mountain villages. In his story, one can feel the courage humanitarians possess, and also the greater love that inspires enemies to become friends. His experience has been most unique in many ways, especially in that it reminds us that we should be grateful for what we already have and should not take things for granted. More importantly, it shows us the simplest way how a doctor should serve his or her patients. This could be distorted at times in the sophisticated world where we live in.

Once again, I would like to thank all the authors of this issue for their contributions. I am sure both ophthalmologists and non-ophthalmologists would enjoy reading them, and would find it informative.



**DRI OCT Triton series**  
Swept Source OCT

9×9 mm

SS OCT Angio (BRVO) (Superficial)

- » Superior visualization of the retina, vitreous and choroid.
- » Remarkable diagnostic capability: Swept Source OCT combined with multimodal imaging<sup>1</sup> (Color, Red-Free, FA, FAF, Anterior OCT<sup>2</sup>)
- » SS OCT Angio: OCT Angiography using Swept Source OCT
- » Unique tracking system provides unmatched accuracy

**TOPCON**  
YOUR VISION. OUR FOCUS.

<sup>1</sup>DRI OCT Triton plus : OCT / Anterior OCT (Option) / Color / Red-Free/ FA / FAF  
DRI OCT Triton : OCT / Anterior OCT (Option) / Color / Red-Free  
<sup>2</sup>Option  
Not available for sale in the US.  
Courtesy: Dr. Carl Glittenberg Karl Landsteiner Institute for Retinal Research and Imaging  
TOPCON CORPORATION: <http://global.topcon.com/eyecare/>

Hong Kong Authorized Sole Agent:

## Topcon Beijing (HK) Limited

2/F., Meeco Industrial Building, 53 - 55 Au Pui Wan Street,  
Fo Tan, New Territories, Hong Kong  
Tel: 2690 1328 Email: [tbhk@topconhk.com](mailto:tbhk@topconhk.com)  
[www.topconhk.com](http://www.topconhk.com)

Our Partner:

**icare**  
tonometer

**Ocular**  
Instruments, Inc.

**ASICO**

# Updates on Treatment Options for Keratoconus

## Dr Alex LK NG

MBBS (HKU), FRCS (Edinburgh), FCOphthHK, FHKAM (Ophthalmology)  
Department of Ophthalmology, The University of Hong Kong

## Dr Arthur CK CHENG

MBBS (Sydney), MRCS (Edinburgh), FCOphthHK, FRCOphth,  
FHKAM (Ophthalmology)  
Department of Ophthalmology, Hong Kong Sanatorium and Hospital



Dr Alex LK NG



Dr Arthur CK CHENG

*This article has been selected by the Editorial Board of the Hong Kong Medical Diary for participants in the CME programme of the Medical Council of Hong Kong (MCHK) to complete the following self-assessment questions in order to be awarded 1 CME credit under the programme upon returning the completed answer sheet to the Federation Secretariat on or before 31 March 2018.*

## Introduction

Keratoconus is a bilateral, non-inflammatory, ectatic disorder of the cornea characterised by progressive corneal thinning and bulging, resulting in a protruded, cone-shaped cornea. It usually manifests between the first to the third decade of life, and causes irregular astigmatism that could not be corrected by spectacles, severely affecting the patient's quality of vision. Keratoconus is a multi-factorial disease. Common causative factors include genetics, chromosomal disorders (e.g. Down syndrome), atopy, connective tissue disorder (e.g. Marfan syndrome) and frequent eye rubbing.<sup>1</sup> The diagnosis of keratoconus is mainly based on corneal tomographies and pachymetry. With recent advancements in imaging techniques such as corneal tomographies with Scheimpflug imaging systems or swept-source optical coherent tomographies, more accurate diagnosis and detection of earlier stages of the disease is now possible.<sup>2</sup>

For many years, treatment options for keratoconus were limited. The role of spectacles or contact lenses is to improve the vision by means of correcting the associated refractive errors. However, they do not alter the disease process nor correct the underlying problem. Traditional spectacles approach often fails because of its inability to correct irregular astigmatism, and patients often have very asymmetric refractive errors between both eyes. Specialty contact lenses like rigid gas-permeable hard contact lenses or scleral contact lenses can correct irregular astigmatism but they may be uncomfortable to wear. Surgical approaches such as corneal stromal ring implantations can also improve the corneal irregularity, but the disease would still progress due to the cornea's in-born weakened biomechanical properties. In advanced keratoconus when the above options have failed, corneal transplantation is required.

Treatment options for keratoconus have a dramatic change in the last decade after the emergence of corneal collagen cross-linking (CXL). CXL is a technique that enhances cross-linking bonding formation between corneal stroma collagen fibrils and increases the overall strength and stability of the cornea. CXL alone or in-combination with other surgical techniques has dramatically changed our approach to keratoconus in recent years. Now, there are two treatment goals: to stop the disease progression, and to improve the vision.<sup>3,4</sup>

The aim of this article is to briefly discuss how we use CXL to stop disease progression, and how to improve vision with modalities including contact lenses, intra-corneal ring segments implantation, photorefractive keratectomy, corneal transplantation and intra-ocular lens implantations.

## Corneal Collagen Cross-linking (CXL)

Corneal collagen cross-linking is a photochemical reaction that occurs when riboflavin (vitamin B2) are activated by ultra-violet A in the presence of oxygen. It increases the bonding formation between collagen fibrils in the corneal stroma and thus increases the overall mechanical strength of the cornea. In keratoconic eyes, the corneal biomechanical strength is reduced, and cross-linking can restore it. Applying CXL in the treatment of keratoconus was first reported in 2003 in Europe. Since then, a number of studies with long follow up durations have consistently reported that CXL is able to halt the keratoconus progression, both in paediatric and adult populations, and has an excellent safety profile.<sup>5,6</sup> In other words, CXL can stiffen the cornea to prevent it from further coning and thinning. Apart from this, most studies also report an improvement in visual acuity and corneal topographic parameters. In 2016, it received the FDA's approval for treating keratoconus.<sup>7</sup> Nowadays, CXL is indicated for most keratoconic eyes to stop the disease progression, unless it is diagnosed at a very advanced stage where the patient may need a transplant straight away, or at an advanced age where there is no longer disease progression (as the cornea naturally stiffens with increasing age). Recent advances in CXL include how to improve the surgical technique, aiming for a shorter treatment duration, or ways to preserve the corneal epithelium intra-operatively.<sup>8</sup>

## Contact lenses

As mentioned in the introduction, apart from stopping disease progression with CXL, the other main treatment aim is to improve visual function. Using contact lenses is the usual first line for this purpose. In keratoconus, patients have irregular astigmatism where the anterior corneal surface is non-uniform due to progressive coning and steepening. Conventional spectacles or soft contact lenses are designed to only correct a uniformly oval – shaped cornea (meaning regular astigmatism) and could not correct irregular astigmatism. Instead,



they need rigid gas-permeable (RGP) 'hard contact lenses' to improve vision. They can usually improve the visual quality significantly in the earlier stages of disease. Some recent newer contact lens designs (such as hybrid lenses or mini-scleral lenses) can also improve the comfort level when wearing them. However, in moderate to advanced stages, the cornea may be too irregular, making lens fitting impossible. In these cases, other surgical interventions will be needed to reduce the irregularity of the cornea, so that contact lenses would become feasible again.<sup>9</sup>

### Topography-guided phototherapeutic keratectomy (tPTK)

Phototherapeutic keratectomy (PTK) is a type of laser refractive surgery where an excimer laser is used to ablate corneal stromal tissue directly. Before the era of CXL, any form of laser vision correction is contraindicated in keratoconus, because ablation of corneal stromal tissue in the already weakened-cornea (keratoconus eyes are biomechanically weaker than normal eyes), it will accelerate further disease progression. Fortunately, because now we can increase the corneal biomechanical strength with CXL, tPTK can be combined with CXL to safely treat keratoconus. Together, the procedure can improve the regularity of the anterior corneal surface, as well as stopping the disease progression from the CXL effect.<sup>10</sup> The main aim of PTK, with the help of topography-guidance, is to reduce the irregularity of the corneal surface, making it easier for contact lens fitting or even spectacles correction. The amount of the refractive error can also be reduced. Large case series have proven the safety and efficacy of this technique. (Fig. 1 (left) shows the pre-operative irregular corneal surface from a Pentacam scan (Scheimpflug tomography), and the right shows it has become much more regular after receiving combined tPTK with CXL. Best-corrected visual acuity also improved from 20/100 to 20/20) Main limitations of the procedure include its dependence on the pre-operative corneal thickness which limits the amount of corneal stromal tissue available for laser ablation (the more advanced disease stage, the thinner is the cornea), and the availability of the excimer laser platform.

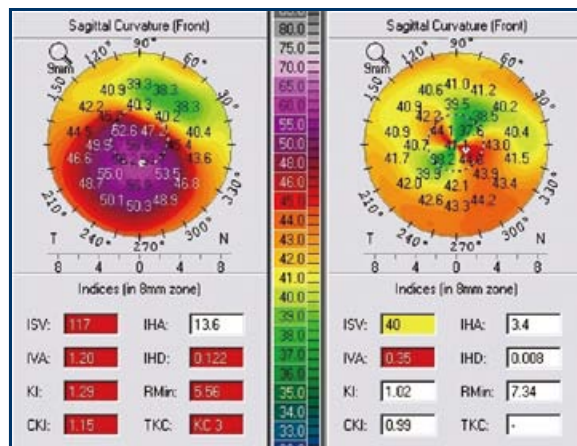


Fig. 1

### Intra-corneal Ring Segments Implantation

Apart from using excimer lasers to modify the corneal shape, implanting intra-corneal ring segments (ICRS) into the corneal stroma can also improve the shape and refractive power of the cornea. These ring-like implants are synthetic materials of various sizes and thicknesses. They are inserted into a corneal stromal tunnel, created either mechanically or with a femtosecond laser machine. The sizing, placement location and number of implants required depend on the topographic maps of the cornea, with the aim of flattening and regularising the corneal shape. Studies have reported that ICRS implantation is a safe, predictable and reversible option for keratoconus, and patients with reduced best-corrected visual acuity pre-operatively would most likely benefit from the procedure.<sup>11</sup> It can also be performed at the same stage with CXL, or sequential to CXL. Fig. 2 shows the slit lamp photo of an eye implanted with an ICRS.

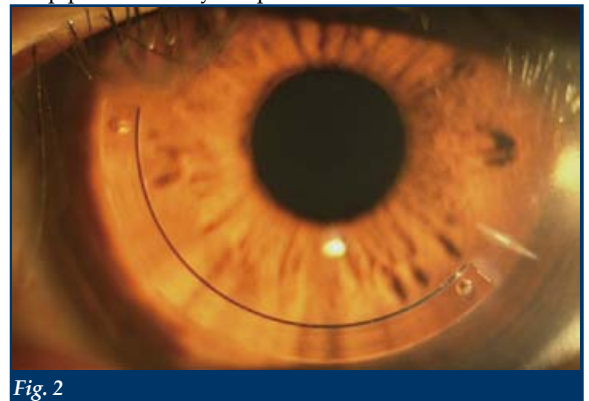
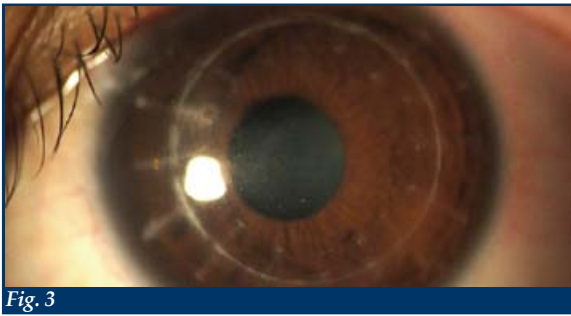


Fig. 2

### Corneal Transplantation

In advanced stages when the above options have failed, or when corneal scarring has developed, corneal transplantation would be indicated. By replacing the diseased cornea with a new full-thickness cornea (penetrating keratoplasty, PK), vision can be restored. Long term problems of corneal transplantation include risk of rejection, steroid-induced glaucoma (long term steroid is required to prevent rejection), graft failure and significant astigmatism. Previous studies have reported an average graft span of 18 years using regression models.<sup>12</sup> In recent years, lamellar transplantation where surgeons only replace the diseased layer(s) of cornea, has gained popularity with good results. In keratoconus, the innermost layer (endothelial layer) is often unaffected. Thus, we could replace only the diseased anterior layers (corneal stroma) with deep anterior lamellar keratoplasty (DALK). Because the patient's own corneal endothelium is now preserved, the rejection rate is much reduced, so is the need of using long-term steroids. Studies have proven a lower rejection rate and longer graft survival using DALK when compared with PK.<sup>13,14</sup> However, intra-operative challenges in DALK remain, where sometimes the surgeon needs to convert back to PK intra-operatively. Nevertheless, with the increasing use of CXL in stopping keratoconus disease progression, it is predicted that less keratoconus patients will require corneal transplant in future. Fig. 3 shows a patient who has received corneal transplant.



**Fig. 3**

## Lens-based surgery

For most of the treatment options discussed above, the keratoconus disease progression could be halted, and the amount of refractive error including irregular astigmatism could be reduced. Nevertheless, residual refractive error often remains. Implanting intraocular lenses (IOL), either during cataract surgery (in the older age-groups) or as phakic IOL (preserving patient's own crystalline lens and inserting another IOL on top), can further reduce the refractive errors, especially for myopia or hyperopia. However, IOLs should only be used when the corneal condition has already stabilised. Furthermore, irregular astigmatism could not be corrected with IOLs, and has to be managed with other options discussed above.

## Summary

In summary, a variety of treatment options are available for keratoconus. The treatment decision would depend on lots of factors, in particular, the patient's condition, life style and expectation, and the availability of the expertise and equipment. Using cross-linking to stop disease progression has dramatically changed our management algorithm, as well as the patient's prognosis in the long-term.

### References

- Mas Tur V, MacGregor C, Jayaswal R, O'Brart D, Maycock N. A review of keratoconus: Diagnosis, pathophysiology, and genetics. *Surv Ophthalmol.* Nov - Dec 2017;62(6):770-783.
- Martinez-Abad A, Pineró DP. New perspectives on the detection and progression of keratoconus. *J Cataract Refract Surg.* Sep 2017;43(9):1213-1227.
- Andreas K, Hashemi K, Petrelli M, Droustas K, Georgalas I, Kymionis GD. Keratoconus Treatment Algorithm. *Ophthalmol Ther.* Jul 28 2017.
- Gomes JA, Rapuano CJ, Belin MW, Ambrosio R, Jr. Global Consensus on Keratoconus Diagnosis. *Cornea.* Dec 2015;34(12):e38-39.
- McAnena L, Doyle F, O'Keefe M. Cross-linking in children with keratoconus: a systematic review and meta-analysis. *Acta Ophthalmol.* May 2017;95(3):229-239.
- Meiri Z, Keren S, Rosenblatt A, Sarig T, Shenhav L, Varssano D. Efficacy of Corneal Collagen Cross-Linking for the Treatment of Keratoconus: A Systematic Review and Meta-Analysis. *Cornea.* Mar 2016;35(3):417-428.
- Hersh PS, Stulting RD, Muller D, Durrie DS, Rajpal RK. United States Multicenter Clinical Trial of Corneal Collagen Crosslinking for Keratoconus Treatment. *Ophthalmology.* Sep 2017;124(9):1259-1270.
- Ng AL, Chan TC, Cheng AC. Conventional versus accelerated corneal collagen cross-linking in the treatment of keratoconus. *Clin Exp Ophthalmol.* Jan-Feb 2016;44(1):8-14.
- Downie LE, Lindsay RG. Contact lens management of keratoconus. *Clin Exp Optom.* Jul 2015;98(4):299-311.
- Kontadakis GA, Kankariya VP, Tsoulnaras K, Pallikaris AI, Plaka A, Kymionis GD. Long-Term Comparison of Simultaneous Topography-Guided Photorefractive Keratectomy Followed by Corneal Cross-linking versus Corneal Cross-linking Alone. *Ophthalmology.* May 2016;123(5):974-983.
- Giacomin NT, Mello GR, Medeiros CS, et al. Intracorneal Ring Segments Implantation for Corneal Ectasia. *J Refract Surg.* Dec 01 2016;32(12):829-839.
- Borderie VM, Sandali O, Bullet J, Gaujoux T, Touzeau O, Laroche L. Long-term results of deep anterior lamellar versus penetrating keratoplasty. *Ophthalmology.* Feb 2012;119(2):249-255.
- Henein C, Nanavaty MA. Systematic review comparing penetrating keratoplasty and deep anterior lamellar keratoplasty for management of keratoconus. *Cont Lens Anterior Eye.* Feb 2017;40(1):3-14.
- Sarezky D, Orlin SE, Pan W, VanderBeek BL. Trends in Corneal Transplantation in Keratoconus. *Cornea.* Feb 2017;36(2):131-137.



**HENSEN** SINCE 1993 **INTERIORS**  
藝信室內設計

Hensen Interiors is an award winning design firm, focusing on design excellence and exceptional project delivery in the medical, retail and commercial sectors.

We design each project to meet specific needs and conditions of our clients from concept to completion. With over 20 years of experience, we have established a long and trustworthy sourcing network which allows us to refine our design to bound by clients' predetermined financial parameters, in the meantime, achieving their satisfaction.

成立於1993 · 專為診所 · 寫字樓 · 美容院及店舖 · 提供室內設計及裝飾工程服務 · 有豐富的設計 · 施工及工程管理經驗 · 歡迎查詢 ·



榮獲  
2018年度最具企業價值大獎  
2017年度室內設計權威大獎

Contact Us:



Yisrael Cophas Yip ☎ +852 9019 2570  
Christine Cheung ☎ +852 9626 2570  
24/F, Wlan Choi Central Building,  
89, Lockart Road, Wlan Choi, Hong Kong



## MCHK CME Programme Self-assessment Questions

Please read the article entitled "Updates on Treatment Options for Keratoconus" by Dr Alex LK NG and Dr Arthur CK CHENG and complete the following self-assessment questions. Participants in the MCHK CME Programme will be awarded CME credit under the Programme for returning completed answer sheets via fax (2865 0345) or by mail to the Federation Secretariat on or before 31 March 2018. Answers to questions will be provided in the next issue of The Hong Kong Medical Diary.

Questions 1-10: Please answer T (true) or F (false)

- The following are all causative factors for keratoconus?  
A. Genetics B. Ageing C. Chromosomal disorders D. Connective Tissue disorders
- Keratoconus is a significant risk factor for glaucoma, leading to blindness in keratoconus patients.
- Corneal collagen cross-linking is the only treatment option that can halt keratoconus disease progression.
- Use of rigid gas-permeable contact lenses should be considered as first-line treatment for keratoconus patients with irregular astigmatism not corrected by spectacles.
- Corneal transplantation is most suitable for keratoconus patients with late stage disease?
- Eye rubbing can cause keratoconus to deteriorate.
- Early keratoconus can have no apparent signs on clinical / slit lamp examination.
- Corneal collagen cross-linking should be considered in all keratoconus patients with evidence of disease progression.
- Corneal refractive surgery alone (e.g. LASIK) can be safely performed in patients with early stage keratoconus.
- Some forms of corneal refractive surgery, when combined with corneal collagen cross-linking, can be safely performed in patients with early stage keratoconus.

## ANSWER SHEET FOR MARCH 2018

Please return the completed answer sheet to the Federation Secretariat on or before 31 March 2018 for documentation. 1 CME point will be awarded for answering the MCHK CME programme (for non-specialists) self-assessment questions.

### Updates on Treatment Options for Keratoconus

#### Dr Alex LK NG

MBBS (HKU), FRCS (Edinburgh), FCOphthHK, FHKAM (Ophthalmology)  
Department of Ophthalmology, The University of Hong Kong

#### Dr Arthur CK CHENG

MBBS (Sydney), MRCS (Edinburgh), FCOphthHK, FRCOphth,  
FHKAM (Ophthalmology)  
Department of Ophthalmology, Hong Kong Sanatorium and Hospital

1  2  3  4  5  6  7  8  9  10

Name (block letters): \_\_\_\_\_ HKMA No.: \_\_\_\_\_ CDSHK No.: \_\_\_\_\_

HKID No.: \_\_\_ - \_\_\_ X X (X) HKDU No.: \_\_\_\_\_ HKAM No.: \_\_\_\_\_

Contact Tel No.: \_\_\_\_\_ MCHK No.: \_\_\_\_\_ (for reference only)

### Answers to February 2018 Issue

#### Primary Cleft Lip and Palate Repair

1. F 2. T 3. F 4. T 5. T 6. T 7. T 8. F 9. T 10. F

# LUCENTIS®: STATE-OF-THE-ART PREFILLED SYRINGE<sup>1,3</sup>

## 4 EASY STEPS<sup>1</sup>

### 1 RELEASE

#### Release the syringe from its pack

- Use aseptic technique throughout the procedure
- The prefilled syringe is for single use only
- Do not use if any part of the packaging is damaged or if the solution is discolored, cloudy, or contains particles

### 2 SNAP

#### Snap off the protective syringe cap

- Do not twist – the cap must be snapped off

### 3 ATTACH

#### Attach the injection needle of your choice

- Attach a 30G x 1/2 inch sterile injection needle
- Do not wipe the needle at any time

### 4 SET

#### Set the dose

Align the edge below the dome of the stopper with the dose mark

- The rubber stopper is non-retractable to prevent air from being drawn into the syringe
- 0.05 mL equals 0.5 mg of ranibizumab

**EASY TO HANDLE**  
to potentially minimize ocular risk<sup>1,2</sup>

- Non-retractable stopper<sup>2</sup>
- Advanced silicization process<sup>1,2</sup>
- Easy to hold<sup>2</sup>

**EASY TO USE**  
with fewer preparation steps<sup>1</sup>

**EASY TO SAVE TIME**  
in your daily practice<sup>3</sup>

Easy to offer the benefits of LUCENTIS® to your nAMD, DME, BRVO, CRVO, and CNV patients<sup>1,3</sup>

#### LUCENTIS®

**Note:** Before prescribing, consult full prescribing information. **Presentation:** Vial: Ranibizumab. Each vial contains 2.3 mg of ranibizumab in 0.23 mL solution. **Prefilled syringe:** Ranibizumab. Each pre-filled syringe contains 1.65 mg of ranibizumab in 0.165 mL solution. The extractable volume of one pre-filled syringe is 0.1 mL. This provides a usable amount to deliver a single dose of 0.05 mL containing 0.5 mg ranibizumab. **Indications:** • Treatment of neovascular (wet) age-related macular degeneration (AMD). • Treatment of visual impairment due to diabetic macular edema (DME). • Treatment of visual impairment due to macular edema secondary to retinal vein occlusion (branch RVO or central RVO). • Treatment of visual impairment due to choroidal neovascularization (CNV). **Dosage and administration:** • The recommended dose is 0.5 mg (0.05 mL) given as a single intravitreal injection. The interval between two doses injected into the same eye should be at least four weeks. • Treatment is initiated with one injection per month until maximum visual acuity is achieved and/or there are no signs of disease activity. • Thereafter, monitoring and treatment intervals should be determined by the physician and should be based on disease activity as assessed by visual acuity and/or anatomic parameters. • Monitoring for disease activity may include clinical examination, functional testing or imaging techniques (e.g. optical coherence tomography or fluorescein angiography). In patients with wet AMD, DME and RVO, initially, three or more consecutive, monthly injections may be needed. The treatment of visual impairment due to CNV should be determined individually per patient based on disease activity. Some patients may only need one injection during the first 12 months; others may require more frequent treatment, including a monthly injection. For CNV secondary to pathologic myopia (PM), many patients may only need one or two injections during the first year. **break-and-extend regimen:** While applying the treat-and-extend regimen, the treatment interval should be extended by no more than two weeks at a time for wet AMD and extended by up to one month at a time for DME. For RVO, treatment intervals may also be gradually extended, however there are insufficient data to conclude on the length of these intervals. If disease activity recurs, the treatment interval should be shortened accordingly. **Lucentis and laser photocoagulation in DME or in branch RVO:** Lucentis has been used concomitantly with laser photocoagulation in clinical studies. When given on the same day, Lucentis should be administered at least 30 minutes after laser photocoagulation. Lucentis can be administered in patients who have received previous laser photocoagulation. • Lucentis must be administered by a qualified ophthalmologist using aseptic techniques. Broad-spectrum topical antibiotic and anesthetic should be administered prior to the injection. • Not recommended in children and adolescents. **Contraindications:** Hypersensitivity to ranibizumab or to any of the excipients, patients with active or suspected ocular or perocular infections, patients with active intraocular inflammation. **Warnings and precautions:** • Intravitreal injections have been associated with endophthalmitis, intraocular inflammation, rhegmatogenous retinal detachment, retinal tear and iatrogenic traumatic cataract. Therefore proper aseptic injection techniques must be used. Patients should be monitored during the week following the injection to permit early treatment if an infection occurs. • Transient increases in intraocular pressure (IOP) have been seen within 60 minutes of injection of Lucentis. Sustained IOP increases have also been reported. Intraocular pressure and the perfusion of the optic nerve head must be monitored and managed appropriately. Patients should be informed of the symptoms of these potential adverse reactions and instructed to inform their physician if they develop signs such as eye pain or increased discomfort, worsening eye redness, blurred or decreased vision, an increased number of small particles in their vision, or increased sensitivity to light. • There is a potential risk of arterial thromboembolic events following intravitreal use of VEGF inhibitors. A low incidence rate of arterial thromboembolic events was observed in the Lucentis clinical trials in patients with AMD, DME, RVO and CNV and there were no major differences between the groups treated with ranibizumab compared to control. Patients with known risk factors for stroke, including history of prior stroke or transient ischemic attack should be carefully evaluated by their physicians as to whether Lucentis treatment is appropriate and the benefit outweighs the potential risk. • Available data do not suggest an increased risk of systemic adverse events with bilateral treatment. • As with all therapeutic proteins, there is a potential for immunogenicity with Lucentis. • Lucentis has not been studied in patients with active systemic infections or in patients with concurrent eye conditions such as retinal detachment or macular hole. • There are insufficient data to conclude on the effect of Lucentis in patients with RVO presenting irreversible ischaemic visual function loss. • Should not be used during pregnancy unless the expected benefits outweigh the potential risk to the fetus. For women who wish to become pregnant and have been treated with ranibizumab, it is recommended to wait at least 3 months after the last dose of ranibizumab before conceiving a child; use of effective contraception is recommended for women of child-bearing potential; breast-feeding is not recommended. • Following treatment patients may develop transient visual disturbances that may interfere with their ability to drive or use machines. Patients should not drive or use machines as long as these symptoms persist. • Risk factors associated with the development of a retinal pigment epithelial tear after anti-VEGF therapy for wet AMD and potentially also other forms of CNV, include a large and/or high pigment epithelial retinal detachment. When initiating Lucentis therapy, caution should be used in patients with these risk factors for retinal pigment epithelial tears. **Interactions:** No formal interaction studies have been performed. **Adverse drug reactions:** • **Very common (≥10%):** vitritis, vitreous detachment, retinal hemorrhage, visual disturbance, eye pain, vitreous floaters, conjunctival hemorrhage, eye irritation, foreign body sensation in eyes, lacrimation increased, blepharitis, dry eye, ocular hyperemia, eye pruritus, intraocular pressure increased, nasopharyngitis, headache, arthralgia. • **Common (≥1 to <10%):** hypersensitivity, retinal degeneration, retinal disorder, retinal detachment, retinal tear, detachment of the retinal pigment epithelium, retinal pigment epithelium tear, visual acuity reduction, vitreous hemorrhage, vitreous disorder, uveitis, iritis, iridocyclitis, cataract, cataract subcapsular, posterior capsule opacification, punctate keratitis, corneal abrasion, anterior chamber flare, vision blurred, injection site hemorrhage, eye hemorrhage, conjunctivitis, conjunctivitis allergic, eye discharge, photophobia, phorbophobia, ocular discomfort, eyelid edema, eyelid pain, conjunctival hyperemia, urinary tract infection<sup>3</sup>, anemia, anxiety, cough, nausea, allergic reactions (rash, pruritus, urticaria, erythema). • **Uncommon (≥1 to <10%):** blindness, endophthalmitis, hypopyon, hyphema, keratopathy, iris adhesions, corneal deposits, corneal edema, corneal striae, injection site pain, injection site irritation, abnormal sensation in eye, eyelid irritation. • **Serious adverse events** related to intravitreal injections include endophthalmitis, blindness, rhegmatogenous retinal detachment, retinal tear and iatrogenic traumatic cataract. <sup>3</sup>observed only in the DME population A meta-analysis of pooled safety data from completed, randomized, double masked global clinical studies showed a higher incidence rate of non-serious, non-ocular wound infection/inflammation in DME patients treated with ranibizumab 0.5 mg (1.85/100 patient years) compared to control (0.27/100 patient years). The relationship to ranibizumab remains unknown. **Packs:** 1 vial or 1 pre-filled syringe per pack. Not all packs are marketed. **Legal classification:** P1/S3.

Ref: EMA Dec 2016 - CDSPres (TG)

1. Lucentis Product Information (Hong Kong) 2. Michael JE, et al. Ranibizumab pre-filled syringe approved in the European Union: innovation to improve dose accuracy, reduce potential infection risk, and offer more efficient treatment administration. Poster presented at the Association for Research in Vision and Ophthalmology (ARVO 2014) 3. Souled E, et al. Ranibizumab pre-filled syringe versus single-use vial: syringe-preparation time in real-world clinical practice. Poster 256 presented at ESASO 2014, Istanbul, Turkey.





# Current Trends in the Management of Thyroid Eye Disease

Dr Emmy Yuen-mei LI

MBBS (Honours), MPH, FRCS (Edinburgh), FCOphthHK, FHKAM (Ophthalmology)

Specialist in Ophthalmology

Honorary Associate Consultant, Hong Kong Eye Hospital

Honorary Assistant Professor, Department of Ophthalmology and Visual Sciences, The Chinese University of Hong Kong

President, Hong Kong Federation of Societies for Prevention of Blindness

Honorary Secretary, Hong Kong Ophthalmological Society



Dr Emmy Yuen-mei LI

## Introduction

Thyroid eye disease (TED) is also known as Graves' ophthalmopathy/orbitopathy, thyroid-associated ophthalmopathy/orbitopathy or thyrotoxic/endocrine exophthalmos. It is the most important extrathyroidal manifestation of autoimmune thyroid diseases including Graves' disease and Hashimoto thyroiditis. It was estimated that up to 50% of patients with autoimmune thyroid diseases develop TED, and of these, as many as 10–20% develop severe inflammation, orbital congestion, impaired ocular motility or dysthyroid optic neuropathy (DON).

Orbital inflammation in TED is due to shared antigens and cross-reactivity of orbital and thyroid tissues, circulating thyroid antibodies stimulate proteins of the extraocular muscles and orbital fat, resulting in lymphocytic infiltration, proliferation of fibroblasts and production of glycosaminoglycans. The expansion of fibroadipose tissue and the infiltration of extraocular muscles lead to orbital congestion and exophthalmos, impaired ocular motility, diplopia, and rarely, sight threatening compressive optic neuropathy. These changes progress during the active phase of disease, typically lasting 6–18 months and followed by a stable plateau of inactive disease. The plot of the natural history of the orbital disease over time is called the Rundle's curve. A steeper slope in the active phase means a more acute onset and likely more serious sequelae (Fig. 1).

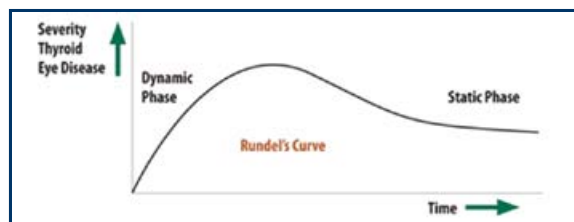


Fig. 1. Rundle's curve describes the natural history of TED. Progressive active phase lasts for up to 18 months before settling in the stable inactive phase

TED tends to have a bimodal presentation during the fourth or sixth decade of life. The female-to-male ratio is about 9:1 for all forms of clinical TED and drops to 3:1 for the severe form. About 20% of patients have concurrent ocular and dysthyroid features at presentation, around 23% of patients present before the diagnosis of thyroid dysfunction, and 57% develop ocular features after being treated for

thyroid dysfunction. Risk factors for the development of TED include the male gender, older age (>50 years) at onset, smoking, use of radioactive iodine (RAI), and post-ablative hypothyroidism. Compared with nonsmokers, smokers have more severe TED, a higher rate of recurrence, are more likely to show progression or occurrence of TED after radioactive iodine, and are less responsive to immunosuppressants or orbital radiotherapy. Statin use was shown to have a 40% decreased hazard for TED but it may increase the risk of liver derangement in patients receiving intravenous steroids for active TED.

## Clinical Features of Thyroid Eye Disease

Typical signs of TED in Caucasians include eyelid retraction, lid lag, proptosis, restrictive myopathy, and optic nerve dysfunction. In Asians, extraocular features including lid puffiness, lid retraction (Fig. 2a), lid lag, lagophthalmos, proptosis, restrictive strabismus, and acquired lower lid epiblepharon are observed. Intraocular features include conjunctival injection, particularly around the insertion of the rectus muscle, superior limbic keratitis, exposure keratopathy (Fig. 2b), chemosis, raised intraocular pressure, optic disc swelling, retinal venous congestion, and choroidal folds are the signs to be looked for. Lid retraction is the most common sign in TED. The normal upper lid rests at 1-2 mm below the superior limbus (corneoscleral junction), and the lower lid rests at the inferior limbus. Other causes of lid retraction include facial paralysis, myasthenia gravis, myotonic dystrophy, Marcus-Gunn jaw winking, metabolic disease (uraemia, cirrhosis), dorsal midbrain syndrome, Parkinson's disease, contralateral ptosis, and aberrant third nerve regeneration. These conditions are however not associated with lid lag. Patients with TED have axial non-pulsatile proptosis/exophthalmos secondary to orbital venous congestion, enlargement of the extraocular muscles and enhanced adipogenesis. Exophthalmos can be clinically quantified using various types of exophthalmometers (e.g. Hertel) or radiologically with axial orbital scans (Fig. 3). Diplopia or double vision in TED is related to restrictive myopathy rather than muscle paralysis. The inferior rectus is most commonly involved, followed by the medial, superior, and lateral rectus. Movement is therefore usually worst in elevation or abduction.

Vision loss in TED can be caused by optic nerve dysfunction (DON), exposure keratopathy, uncontrolled intraocular pressure, and globe subluxation. Asian patients often have a delayed and atypical presentation

of TED compared with Caucasians. With a darker complexion, thicker skin and conjunctival tissues and possibly a higher pain threshold, clinical examinations often underestimate the deeper orbital involvements. More Asian patients with DON are 'cold-presenters' with minimal signs of active inflammation. DON is thought to be a result of optic nerve compression by the enlarged extra-ocular muscles (EOM) at the orbital apex. Postulated mechanisms of DON include inflammation, ischaemia or mechanical stretching. Signs of DON include impaired vision, colour vision and/or visual field, presence of afferent papillary defects and optic disc swelling. Asian patients with shallow orbits and patients with existing diabetes are at higher risk of developing DON. Advanced radiological imaging available nowadays may help to identify 'subclinical', localised inflammation and allow prompt medical treatment to reduce the development of DON and progressive deformity requiring subsequent rehabilitative surgery.

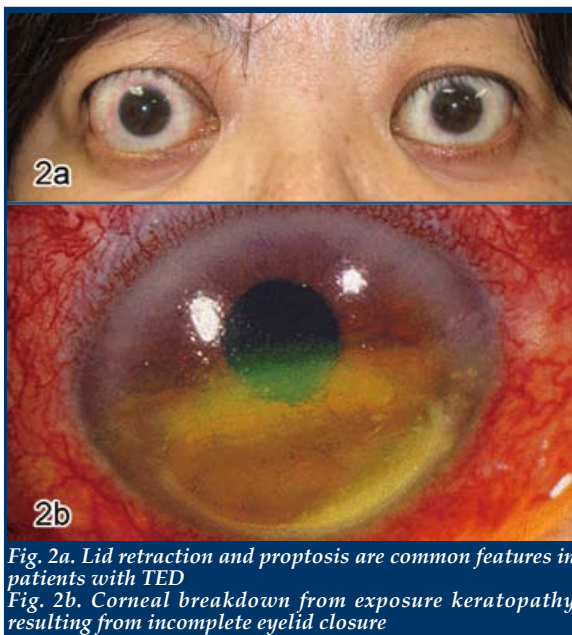


Fig. 2a. Lid retraction and proptosis are common features in patients with TED

Fig. 2b. Corneal breakdown from exposure keratopathy resulting from incomplete eyelid closure

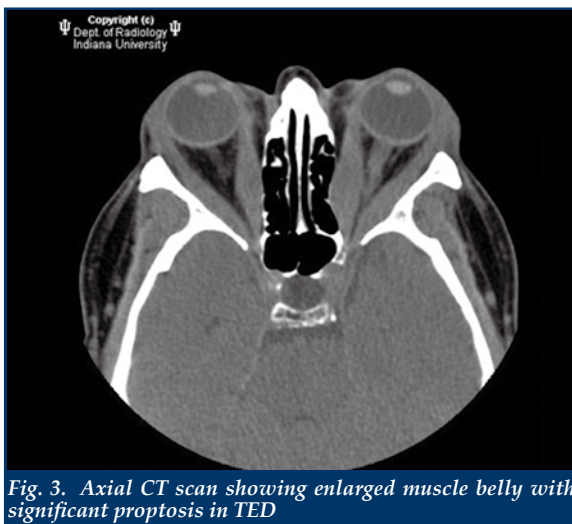


Fig. 3. Axial CT scan showing enlarged muscle belly with significant proptosis in TED

## Grading and Investigation of Thyroid Eye Disease

TED is graded by its disease activity (extent of inflammation) and disease severity (degree of deformities). The Clinical Activity Score (CAS) is used to measure the degree of inflammation. One point is given for the presence of each of the parameters assessed, including spontaneous orbital pain, gaze evoked orbital pain, eyelid swelling, eyelid erythema, conjunctival redness, chemosis and inflammation of the caruncle. The sum of all points defines clinical activity: active orbitopathy if the score is above 3/7 at the first examination or above 4/10 in successive examinations. The NOSPECS Grading is a traditional assessment on disease severity which describes the combination of deformities (N = Normal, O = Only sign, S = Soft tissue involvement, P = Proptosis, E = Extraocular Motility, C = Corneal exposure, S = Sight-threatening). The European Group On Graves' Orbitopathy (EUGOGO) has proposed a standard protocol to assess the severity of TED and offer image atlases (<http://www.eugogo.eu/>) for assessors to take reference. According to the EUGOGO Classification, mild disease has minimal eyelid swelling, lid retraction or proptosis with little or no extraocular muscle dysfunction, with a minor impact on daily life. Moderate disease implies inflammatory features interfering with the ability to function, possible ocular motility dysfunction with diplopia, lid retraction greater than 2mm and variable proptosis. At this grade, the disease has sufficient impact on daily life to justify the risks of immunosuppressants in cases of active disease, or surgical intervention in inactive cases. Severe disease refers to sight-threatening conditions such as DON or corneal ulceration from exposure keratopathy, which often necessitates some form of surgical intervention. The VISA system is recently proposed by the International Thyroid Eye Disease Society (ITEDS) (<http://www.thyroideyedisease.org/>) which tries to combine the assessment of disease activity and severity into one. The system assesses 4 severity parameters: V (vision), I (inflammation/congestion), S (strabismus/motility restriction) and A (appearance/exposure). Each feature is considered and graded independently to give a global severity grade with a maximum score of 20.

Diagnosis of TED is still largely clinical, based on a history of autoimmune thyroid disease and compatible examination findings. All patients should have appropriate endocrinological evaluation with thyroid function test for serum sensitive thyrotropin, free thyroxine and triiodothyronine levels. Thyroid-related antibodies, specifically thyrotropin receptor antibodies, may be evaluated in patients without a clear history of thyroid disorder. Other ancillary ocular evaluations include visual field (automated perimetry), colour vision assessment (Ishihara pseudoisochromatic plates), Hess chart (for extraocular movement), and most importantly a field of binocular single vision for patients with diplopia. Differential diagnoses of TED include other orbital disorders such as idiopathic orbital inflammation (pseudotumour), orbital or preseptal cellulitis, carotid-cavernous fistula and orbital tumour. Orbital imaging revealing proptosis with EOM enlargement and expansion of the fatty compartment can help to differentiate TED from these conditions. Rarely, a tissue



biopsy is required in patients with euthyroid TED and atypical clinical features to confirm the diagnosis.

## Management of Thyroid Eye Disease

### *Measures for All Patients with Thyroid Eye Diseases*

#### **Restore Euthyroidism**

Management of patients with TED includes restoring and stabilising thyroid function. Patients with uncontrolled thyroid dysfunctions are more likely to experience severe disease. Constant monitoring (every 4–6 weeks) of thyroid function is particularly important during the early stages of treatment. Evidences suggest that radioactive iodine (RAI) worsens the active ocular disease in 15% of cases within the 6 months after the treatment. Patients who are smokers, with unstable thyroid function and high levels of thyroid-stimulating immunoglobulin are at risk. RAI should be avoided in patients with active TED (clinical activity score  $\geq 3/10$ ). Standard dose oral prednisolone prophylaxis (0.4–0.5 mg/kg for 3 months) should be prescribed in patients with mild to moderate TED and a high risk of progression, whereas a lower dose (0.2–0.3 mg/kg for 4–6 weeks) is preferred for patients with mild TED or without preexisting TED but with risk factors.

#### **Conservative Measures**

Patients should be advised to adopt general measures such as the use of artificial tears, sunglasses, and sleep with the head of the bed slightly elevated. Nocturnal ointment is of great benefit for incomplete eyelid closure to protect the cornea.

#### **Smoking Cessation**

Smoking is the most important modifiable risk factor in patients with TED and the risk is proportional to the daily cigarette intake. Smokers with TED are more likely to develop a severe condition and have poor response to immunosuppressant therapies. It was demonstrated that smoking, even past smoking, is an independent risk factor associated with impaired response to intravenous corticosteroids in patients with TED. Never smokers with active moderate-to-severe TED, who were treated with cumulative doses of 4.5 g intravenous methylprednisolone within 3 months, responded better than both active smokers and past smokers.

### *Measures for Patients with Mild Thyroid Eye Diseases*

Local measures are the mainstay therapy for patients with mild TED that generally have a self-limiting process. Studies investigating the natural history of TED in untreated patients show that the disease improved in 50% of the patients, remained stable in about 35%, and worsened in approximately 15%. A recent study showed that a 6-months course of oral selenium (100  $\mu$ g twice daily) significantly improved the quality of life, reduced ocular involvements, and prevented progression in patients with mild TED. The use of oral corticosteroids is usually not recommended in patients with mild TED. Botulinum toxin injection may be considered to reduce upper lid retraction. It is a valuable therapeutic option in active disease where definitive surgery is contraindicated.

### *Measures for Patients with Moderate to Severe Thyroid Eye Diseases*

In these patients, the eye involvement has sufficient impact on daily life to justify the risks of immunosuppressant treatment (if active) or surgical intervention (if inactive).

#### **Immunosuppressive Medical Treatment and Orbital Radiotherapy**

Only patients with active disease will respond to immunosuppressive treatments. These treatments have no benefit for patients in the quiescent phase in whom disease manifestations are the consequence of fibrotic changes in the orbital tissues. Among the available options for immunosuppression, corticosteroids continue to be the first-line treatment of moderate-to-severe active TED. They can be administered orally, intravenously, and locally via injection into the orbital soft tissues directly. The overall response rate was 82% and 53.4% for intravenous (IV) and oral steroids respectively according to a review. Pulses of IV steroids were also associated with fewer side effects, shorter treatment courses, and a lower relapse risk compared with oral administration. Oral corticosteroids might be considered when IV infusions are not logistically possible or if the patient prefers the oral route. Oral corticosteroids might be prescribed in some moderate to severe cases when the determination of activity is uncertain. A trial of therapy using a three-day course of oral prednisolone (50 mg) can determine whether clinical features show improvement, and guide subsequent IV corticosteroids or radiotherapy. A commonly used regimen for IV corticosteroids is 500 mg methylprednisolone weekly for 6 weeks followed by 250 mg weekly for another 6 weeks, giving a cumulative dose of 4.5 g. This weekly protocol of 4.5 g IV methylprednisolone cumulative dose is not only safer but is also more effective than a daily protocol (500 mg daily for 3 consecutive days per week for 2 weeks, followed by 250 mg daily for 3 consecutive days per week for another 2 weeks, and by tapering oral prednisone). If there is no clinical response, treatment with corticosteroids may be discontinued after the first 6 weeks. Prolongation of treatment after 12 weeks in patients who are responsive to corticosteroids should be related to disease severity and its impact on the quality of life, providing that the cumulative dose does not exceed 8 g and consecutive day-dosing should be avoided. Liver function tests, detection of hepatitis viral markers, and autoantibodies have to be performed prior to the administration of IV treatment. Patients with recent hepatitis, liver dysfunction, severe cardiovascular morbidity, or severe hypertension must be excluded. Liver enzymes, glucose levels, and blood pressure should be monitored monthly during treatment.

In patients who are not responsive to corticosteroids, other treatments may be attempted. Orbital radiotherapy is a useful adjuvant for patients with steroid-dependent, intolerant or resistant inflammatory orbitopathy, recent-onset progressive myopathy, and in some cases of DON. It consists of fractionated external beam irradiation of 20G in 10 sessions over 2 weeks. Orbital radiotherapy is supposed to work through its nonspecific anti-inflammatory effects and the high radiosensitivity of lymphocytes infiltrating the orbital space and, hence



Alaska



Pacific Ocean

Scandinavia & Russia



Arctic Ocean

Japan



British Isles



Panama Canal & South America



South Atlantic Ocean

Mediterranean



Equator

Singapore



Indian Ocean

Australia



BEST CRUISE FOR FOOD LOVERS  
FOOD & WINE MAGAZINE

HIGHEST CUSTOMER SATISFACTION  
TRAVELAGE WEST

BEST CRUISE LINE ITINERARIES  
RECOMMEND MAGAZINE  
15-TIME WINNER



PRINCESS CRUISES  
come back new

2952 8079 | 6898 8919

www.princess.com



reduces the secretion of proinflammatory cytokines from activated lymphocytes. Orbital radiotherapy may not show benefits for several days to weeks, but its effects last longer. Compared with oral corticosteroid therapy, orbital radiotherapy has a comparable effect for moderate to severe orbitopathy and a better long-term effect on motility restriction. Combined IV pulse steroid plus orbital radiotherapy is more effective than IV pulse steroid alone. The risk of DON was reduced in the combined orbital radiotherapy and steroid group than in the steroid-only group. Orbital radiotherapy is most useful when administered during the course of IV pulse steroid yet should be avoided in young patients (age <30 years) or those with diabetic retinopathy. Complications of orbital radiotherapy include dry eyes, cataract, radiation retinopathy, optic neuropathy, and an increased long-term risk of malignancy.

It was observed that some patients seem to have an active phase which lasts longer than usual. They have recurrence of inflammation soon after withdrawal of corticosteroid treatment. These patients can go for a trial of methotrexate (MTX), which has been shown to be effective as sole treatment in patients who fail corticosteroids or become steroid-dependent, weekly dose varied from 5 to 20 mg. Mycophenolate mofetil (MMF) is an immune modulatory drug which demonstrates superior response, in terms of reduction of CAS, improvement in diplopia and proptosis and less disease reactivation, compared to corticosteroids. Alternatively, patients who are nonresponsive to corticosteroids may be treated with a combination therapy of cyclosporin A (5 mg/kg/day in 2 doses plus oral prednisolone), azathioprine, or specific monoclonal antibody agents. In preliminary clinical trials, rituximab significantly reduced the inflammatory activity and severity in patients with TED. However, two recent randomised trials on the efficacy of rituximab in moderate to severe TED reported conflicting results. There are some evidences in short series reports on the efficacy of other immune modulators such as tocilizumab, adalimumab, or etanercept. Other promising treatments such as the production of TSH-R antagonists, either as monoclonal TSH-R-blocking antibodies or as small-molecule-ligand antagonists of TSH-R, are being developed.

### Surgical Treatment

Elective surgery is only recommended at least 6 to 9 months after stabilisation of endocrine and TED status. Available procedures include orbital decompression for disfiguring proptosis; strabismus surgery for diplopia; eyelid recession for eyelid retraction causing lagophthalmos, exposure keratitis, and disfigurement; and blepharoplasty for excessive soft tissue prominence of the eyelids. In planning surgery, orbital decompression must be first addressed because of its influence on ocular motility and lid width, followed by strabismus surgery and, finally, eyelid surgery.

Many different techniques and approaches have been described for orbital decompression surgery, including 1-, 2-, and 3-wall(s) decompression and/or orbital fat removal depending on the degree of proptosis. Different combinations of medial, inferior, and lateral wall decompression have been used as areas of bone removal. New-onset diplopia is the most common

complication of orbital decompression, with the highest rates of 38%–60% reported with inferomedial decompression, possibly as a result of inferomedial shift of the globe after removing the inferomedial strut. Balanced orbital decompression reduces the incidence of postoperative diplopia by producing a more equivalent displacement of the medial and lateral soft tissues into the surrounding space. Newer techniques such as deep lateral wall orbital decompression or modified endoscopic medial orbital fat decompression seem to carry a lower risk of ocular motility problems while offering a significant proptosis reduction.

Strabismus surgery in TED is challenging due to the fibrotic muscles and surrounding soft tissues. The goal of strabismus surgery in patients with TED is to restore binocular single vision at the primary gaze. Residual double vision may persist in peripheral gaze. The basic concept of most operations is to recess the fibrotic muscles in order to correct ocular deviations. Muscle resections should be avoided since any restriction is likely to be aggravated if a muscle is shortened. Most vertical deviations can be corrected by single inferior rectus recessions due to high-dose effect. Dose effects for medial rectus recessions are lower and bilateral medial rectus muscle is often required to treat horizontal strabismus. Different techniques have been proposed to improve the outcomes including an intraoperative relaxed muscle positioning technique, the use of adjustable sutures, operating under monitored anaesthetic care or local anaesthesia, and simultaneous recession of the tenon capsule. Detachment of the lower lid retractor is also recommended to minimise postoperative lower lid retraction or inferior scleral show.

Lid retraction of both upper and lower eyelids is probably the most common feature of TED. Surgery is recommended for significant upper lid retraction of >1 mm, asymmetry of palpebral apertures, or presence of lateral flare. Surgery for upper lid retraction is divided into the anterior approach through an eyelid crease incision where the levator aponeurosis and Müller's muscle are disinserted from the tarsus until an appropriate height of the eyelid is achieved and a posterior approach through the conjunctiva and Müller's muscle. In most cases, the use of implants is not necessary. In lower lid retraction corrections, the conjunctiva and lower lid retractors are detached from the edge of the tarsus through a posterior approach and a spacer (auricular cartilage, hard palate mucosa, expanded polyethylene microplates, autogenous tarsus transplants, porcine acellular dermal matrix, donor sclera, or pericardium) is placed between the retractors and tarsus to achieve lower eyelid lengthening.

Upper and/or lower eyelid blepharoplasty is sometimes needed as the last step in the functional and cosmetic rehabilitation of TED patients.

### Measures for Patients with Sight-Threatening TED

Patients with sight-threatening TED due to DON must be treated urgently. High-dose intravenous corticosteroids are recommended as the first-line treatment for DON (500 mg to 1 g on 3 consecutive days; if necessary, repeated the following week). If the response is insufficient after 1-2 weeks, or the dose/duration of steroid treatment induces significant side

effects, surgical orbital decompression (deep medial orbital wall decompression including posterior ethmoidal cells near the orbital apex) should be carried out promptly. Immediate surgical decompression as first-line therapy has not resulted in a better outcome than the use of IV steroids followed by decompression in patients with no response.

Depending on the severity of the proptosis, cases of corneal exposure keratopathy could be treated with aggressive topical lubrication, moisture chamber, botulinum toxin, levator recession surgery, tarsorrhaphy, or orbital decompression. Intravenous steroids should be administered prior to surgery if the disease is still active.

## Conclusion

TED is the most important extrathyroidal manifestation of autoimmune thyroid diseases. It is the most common cause of lid retraction and proptosis in adults. Morbidity arises from restrictive strabismus causing diplopia and a spectrum of orbital soft tissue changes. Vision loss in TED can be caused by optic nerve dysfunction and corneal breakdown. Different grading systems have been proposed to gauge disease activity and severity, guiding the subsequent approach to treatment. Early stabilisation of thyroid function and smoking cessation are the key measures in the management of TED. Although most TED patients can be managed conservatively, patients with active or severe disease warrant specialist evaluation and timely treatment with intravenous steroid, orbital radiotherapy, and/or surgical decompression. Staged rehabilitative surgeries can be offered to correct the functional deficits and aesthetic deformities when there is evidence of disease quiescence for more than 6 months.


## References

1. Bahn RS. Graves' ophthalmopathy. *N Engl J Med*. 2010;362:726-38.
2. Tanda ML, Piantanida E, Liparulo L, et al. Prevalence and natural history of Graves' orbitopathy in a large series of patients with newly diagnosed graves' hyperthyroidism seen at a single center. *J Clin Endocrinol Metab*. 2013;98:1443-9.
3. Stein JD, Childers D, Gupta S, et al. Risk factors for developing thyroid-associated ophthalmopathy among individuals with Graves disease. *JAMA Ophthalmol*. 2015;133:290-6.
4. Menconi F, Profilo MA, Leo M, et al. Spontaneous improvement of untreated mild Graves' ophthalmopathy: the Rundle curve revisited. *Thyroid* 2014; 24:60-66.
5. McKeag D, Lane C, Lazarus JH, et al. Clinical features of dysthyroid optic neuropathy: a European Group on Graves' Orbitopathy (EUGOGO) survey. *Br J Ophthalmol*. 2007;91:455-8.
6. Lim NC, Sundar G, Amrith S, Lee KO. Thyroid eye disease: a Southeast Asian experience. *Br J Ophthalmol*. 2015;99:512-8.
7. Barrio-Barrio J, Sabater AL, Bonet-Farriol E, et al. Graves' ophthalmopathy: VISA versus EUGOGO classification, assessment, and management. *J Ophthalmol* 2015; 2015:249125.
8. Bartalena L, Baldeschi L, Boboridis K, et al. The 2016 European Thyroid Association/European Group on Graves' Orbitopathy Guidelines for the Management of Graves' Orbitopathy. *Eur Thyroid J*. 2016;5:9-26.
9. Marcocci C, Kahaly GJ, Krassas GE, et al. Selenium and the course of mild Graves' orbitopathy. *N Engl J Med*. 2011;364:1920-31.
10. Stiebel-Kalish H, Robenshtok E, Hasanreisoglu M, Ezrachi D, Shimon I, Leibovici L. Treatment modalities for Graves' ophthalmopathy: systematic review and metaanalysis. *J Clin Endocrinol Metab*. 2009;94:2708-16.
11. Rao R, MacIntosh PW, Yoon MK, Lefebvre DR. Current trends in the management of thyroid eye disease. *Curr Opin Ophthalmol*. 2015 Nov;26(6):484-90.
12. Strianese D. Update on Graves disease: advances in treatment of mild, moderate and severe thyroid eye disease. *Curr Opin Ophthalmol*. 2017 Sep;28(5):505-513.
13. Zang S, Ponto KA, Kahaly GJ. Clinical review: Intravenous glucocorticoids for Graves' orbitopathy: efficacy and morbidity. *J Clin Endocrinol Metab*. 2011;96:320-32.
14. Wiersinga WM. Advances in treatment of active, moderate-severe Graves' ophthalmopathy. *Lancet Diabetes Endocrinol*. 2017;5:134-42.

15. Kim JW, Han SH, Son BJ, Rim TH, Keum KC, Yoon JS. Efficacy of combined orbital radiation and systemic steroids in the management of Graves' orbitopathy. *Graefes Arch Clin Exp Ophthalmol*. 2016;254:991-8.
16. S. Zang, K. A. Ponto, and G. J. Kahaly. Clinical review: intravenous glucocorticoids for graves' orbitopathy: efficacy and morbidity. *J Clin Endocrinol Metab*. 2011;96:320-332.
17. Goldberg RA. Advances in surgical rehabilitation in thyroid eye disease. *Thyroid*. 2008;18:989-95.
18. Laurberg P, Berman DC, Bulow Pedersen I, Andersen S, Carle A. Incidence and clinical presentation of moderate to severe graves' orbitopathy in a Danish population before and after iodine fortification of salt. *J Clin Endocrinol Metab*. 2012;97:2325-32.
19. Acharya SH, Avenell A, Phillip S, Burr J, Bevan JS, Abraham P. Radioiodine therapy (RAI) for Graves' disease (GD) and the effect on ophthalmopathy: a systematic review. *Clin Endocrinol (Oxf)*. 2008;69:943-50.
20. Shiber S, Stiebel-Kalish H, Shimon I, Grossman A, Robenshtok E. Glucocorticoid regimens for prevention of Graves' ophthalmopathy progression following radioiodine treatment: systematic review and meta-analysis. *Thyroid*. 2014;24:1515-23.
21. Graves' ophthalmopathy and acute liver damage: an epidemiological study. *Eur J Endocrinol* 2015; 172:269-276.
22. Peter J. Dolman, Suryasnata Rath. Orbital radiotherapy for thyroid eye disease. *Curr Opin Ophthalmol* 2012; 23:427-432. 18.
23. Menconi F, Leo M, Sabini E, et al. Natural history of Graves' orbitopathy after treatment. *Endocrine* 2016; Oct 5.
24. Sisti E, Menconi F, Leo M, et al. Long-term outcome of Graves', orbitopathy following high-dose intravenous glucocorticoids and orbital radiotherapy. *J Endocrinol Invest* 2015; 38:661-668. 20.
25. Shams PN, Ma R, Pickles T, Rootman J, Dolman PJ. Reduced risk of compressive optic neuropathy using orbital radiotherapy in patients with active thyroid eye disease. *Am J Ophthalmol*. 2014;157:1299-305.
26. Grassi P, Strianese D, Piscopo R, et al. Radiotherapy for the treatment of thyroid eye disease a prospective comparison: is orbital radiotherapy a suitable alternative to steroids? *Ir J Med Sci* 2017; Jan 3.
27. Khanna D, Chong KK, Afifiyan NF, et al. Rituximab treatment of patients with severe, corticosteroid-resistant thyroid-associated ophthalmopathy. *Ophthalmology*. 2010;117:133-9.
28. Braun TL, Bhadkamkar MA, Jubbal KT, et al. Orbital decompression for thyroid eye disease. *Semin Plast Surg* 2017; 31:40-45.
29. Reich SS, Null RC, Timoney PJ, Sokol JA. Trends in orbital decompression techniques of surveyed American Society of Ophthalmic Plastic and Reconstructive Surgery Members. *Ophthal Plast Reconstr Surg* 2016; 32:434-437.
30. WuW, Selva D, Bian Y, et al. Endoscopic medial orbital fat decompression for proptosis in type 1 Graves' orbitopathy. *Am J Ophthalmol* 2015; 159:277-284.
31. Barker L, Mackenzie K, Adams GG, Hancox J. Long-term surgical outcomes for vertical deviations in thyroid eye disease. *Strabismus* 2017; 1-6.



# Community Doctor Consultation Program for Gastroesophageal Reflux Disease (GERD)



GERD has become more prevalent in Hong Kong.<sup>1</sup> GERD symptoms not only impair patient's quality of life, its nocturnal symptoms also deteriorate sleep quality and productivity at work.<sup>2</sup> Despite its severity, study demonstrated that current routine clinical care helps most patients remain stable or improve over a 5-year period.<sup>3</sup>

In order to support proper diagnosis and disease management for suspected GERD patients, you are cordially invited to join the Community Doctor Consultation Program for GERD.

#### Recruitment Target:

Private practice doctors actively managing GERD patients and willing to offer free initial consultation to potential patients.

#### Program Detail:

1. Potential GERD patients can register through program hotline or website, and will be randomly assigned to one participating medical practitioner based on their selected district.
2. Participating medical practitioners will provide free initial consultation for enrolled potential GERD patients (for medication and diagnostic test if needed, the cost can be charged to patients according to the practitioner's decision.)
3. GERD education materials will be provided to participating medical practitioners.

Please note that your participation in the program does not constitute an inducement or award to you to, either directly or indirectly, influence, prescribe, recommend and/or promote a Takeda product. Takeda fully supports your independent and professional judgment on the selection of treatment and/or medicine that best suits your patient's condition.

**Join Now!**



2133 9898



TPHK-info@takeda.com

Reference: 1.Tan VP et al. J Clin Gastroenterol. 2016 ;50:e1-e7 2.Fass R, et al. Am J Gastroenterol 2011; 106:421-31 3.Malfertheiner P, et al. Aliment Pharmacol Ther 2012; 35: 154-164



**Takeda Pharmaceuticals (HK) Ltd.**  
23/F & 24/F, East Exchange Tower, 38 Leighton Road, Causeway Bay, Hong Kong  
Tel: 2133 9800 Fax: 2856 2728

# Minimally Invasive Glaucoma Surgery

## Dr Jonathan CHAN

BSc(Med)/MBBS(Hons)(UNSW), FCOphthHK,  
FHKAM(Ophthalmology), FRCSEd(Ophth)

Department of Ophthalmology, LKS Faculty of Medicine, University of Hong Kong  
Department of Ophthalmology, Queen Mary and Grantham Hospitals

## Dr Jasper WONG

MBChB, MSc, MRCSEd

Department of Ophthalmology, LKS Faculty of Medicine, University of Hong Kong  
Department of Ophthalmology, Queen Mary and Grantham Hospitals



Dr Jonathan CHAN



Dr Jasper WONG

## Introduction

Glaucoma is increasingly becoming a major cause of blindness around the world, mainly because there is currently no treatments which can reverse the optic nerve damage (glaucomatous optic neuropathy) which defines it. Despite numerous research on neuroprotective agents, intraocular pressure (IOP, measured in millimetres of mercury or mmHg) reduction remains the only proven method to prevent or decelerate progression (2017 Guideline from the National Institute for Health and Care Excellence, UK)<sup>1</sup>. Although topical glaucoma medications are normally the first line treatment in most patients, glaucoma surgery remains the most potent method for achieving a target IOP level. For many decades after the introduction of the guarded filtration surgery by Cairns<sup>2</sup>, trabeculectomy has remained largely unchanged as the most commonly performed glaucoma procedure for patients requiring surgical intervention for lowering their IOP, except for the use of intra-operative antifibrotic agents (like mitomycin C) since the 1980's to try to decrease postoperative scarring of the drainage site and improve the surgical success rate<sup>3,4</sup>. In most clinical settings, this is usually after multiple medical treatments have been tried and failed, either due to inadequate IOP lowering or because of intolerable side effects from medical treatment. Even though tube-shunts have become more popular, especially in the United States, since the Tube Versus Trabeculectomy (TVT) Study<sup>5</sup>, it should be noted that even there, trabeculectomy with mitomycin C is still the most frequently performed incisional surgery for glaucoma<sup>6</sup>. However, both trabeculectomy and tube-shunt surgery involve creation of large surgical sites that cover at least one quadrant of the scleral surface, which affects both the recovery time, as well as preclude possible further glaucoma surgery at the operated site. The 5-year result from the TVT Study showed that both procedures were associated with significant early (>20% for tube, >35% for trabeculectomy) and late (both >35%) complications of varying severities<sup>7</sup>. Though both procedures were able to achieve a mean IOP below 15 mmHg over 5 years, there are patients with milder degree of glaucoma, or of more advanced age, who do not need their IOP to be so aggressively lowered, especially if recovery can be hastened and complication rates lowered. Minimally invasive glaucoma surgery (MIGS), or micro-invasive glaucoma surgery as it was initially coined<sup>8</sup>, has become an increasingly popular method for lowering the IOP or reducing the medications requirement for these patients in the past 10 years<sup>9,10</sup>. As MIGS is not a single procedure but a group of widely varying procedures using different IOP

lowering approaches, we will take a brief look at the various types currently available in Hong Kong, or will soon be available.

## Definition

It is generally accepted that MIGS are associated with:

- 1) Minimal surgical trauma (no scleral dissection or extensive conjunctival manipulation)
- 2) Rapid postoperative recovery
- 3) Low rates of serious complications
- 4) Less IOP reduction compared to trabeculectomy or tube-shunts

However, even with these accepted generalities, there are areas of disagreements among glaucoma specialists. For example, when the EX-PRESS Glaucoma Filtration Device (Alcon) was introduced almost 20 years ago, it was initially used without the need to incise the sclera (sclerectomy) unlike standard trabeculectomy, and so could be considered as a form of MIGS. The current usage of this device however, involves sclerectomy to create a scleral flap to cover the back plate of the implant, thus transforming it more into a modified trabeculectomy rather than a MIGS procedure. Also, some would not even consider any procedure involving conjunctival incision or manipulation as MIGS. For this review, we will adopt a more inclusive approach although this is not meant to be an exhaustive list of every procedure currently available.

## Classification

The widely different types of MIGS available can be divided into which pathway is being utilised for aqueous outflow from the anterior chamber of the eye. Currently, these are mainly of 3 types; Schlemm's canal, suprachoroidal space, and subconjunctival space.

## Schlemm's canal

Most of the normal aqueous humour outflow passes through the trabecular meshwork (TM), which forms the inner wall of the Schlemm's canal, then into the episcleral veins via the collecting channels connected to this canal. In primary open angle glaucoma (POAG) or ocular hypertension (OHT), this trabecular outflow is impaired due to increased resistance at the TM, limiting the flow of aqueous into the Schlemm's canal. Some MIGS seek to bypass or remove the TM in order to



facilitate and re-establish this outflow to the Schlemm's canal (and hence to the episcleral veins).

### 1) Goniotomy / Ab interno trabeculotomy

Goniotomy and trabeculotomy involve incising the TM so that aqueous can directly access the Schlemm's canal. It has traditionally been used for congenital glaucoma in children with high success rates in most reports. Its success rate when performed in a similar fashion in adults is much lower<sup>11,12</sup>. The following procedures aim to ablate or remove an entire strip of TM rather than just incising it, thus allowing a more persistent access to the Schlemm's canal.

#### I. Trabectome (NeoMedix, CA, USA)

This instrument received FDA approval in 2004 for the treatment of adult and juvenile open angle glaucoma. A disposable, single-use, 19.5-gauge hand-piece with an insulated footplate containing high-frequency electrocauterisation, irrigation and aspiration functions (Fig. 1.) is inserted into the anterior chamber through a small (usually temporal) clear corneal incision. The end plate is inserted through the TM opposite to the corneal wound, and thermal ablation of the TM is performed for 60 to 120 degrees under gonioscopic viewing. Complications are few and mild, and include transient IOP spike in the first day after the procedure and mild hyphema. The main advantage is that the conjunctiva remains undisturbed, allowing for future trabeculectomy or tube-shunt surgery if required. In a recent meta-analysis in POAG, at 12 months after Trabectome procedure, the mean IOP reduction, mean IOP, mean reduction of medications and mean number of medications used were 25-34%, 14.8-16.8 mmHg, 0.40-0.57 and 2.1-2.4, respectively<sup>13</sup>. However, none of the studies included in the analysis are randomised controlled trials (RCT) as none yet exists despite the Trabectome being commercially available for over 10 years.



Fig. 1.

#### II. Kahook Dual Blade (New World Medical, CA, USA)

This simple single-use device (Fig. 2.) was developed much later than the Trabectome although it uses the same principle of introducing the instrument through a clear corneal incision opposite to the surgical site, and removing the TM there to allow direct access of aqueous into the Schlemm's canal and its collecting channels (Fig. 3.). After its initial in vitro evaluation in human cadaver eyes<sup>14</sup> which noted that the dual blade produces less collateral damage during goniotomy than

cauterisation using the Trabectome, it was introduced into the market. Due to its recent introduction, there is only one large case series reporting on its short term (6 months) results<sup>15</sup>. This prospective, interventional, non-randomised study examined the use of the dual blade goniotomy when combined with cataract extraction (phacoemulsification) in patients with various types of glaucoma, although the majority (70%) were POAG. No significant complications were encountered and the most common (39.4%) adverse event was the not-unexpected intraoperative blood reflux from the collector channels after removal of the TM, which resolved spontaneously in all cases. At 6 months, compared to baseline, there was significant reduction of both IOP and glaucoma medications use, with a mean reduction of IOP and medication use of 4.6 mmHg (26% drop) and 0.7, respectively. The mean IOP and mean number of glaucoma medications used at 6 months postoperatively were 12.8 mmHg and 0.9 respectively, compared to the baseline of 17.4 mmHg and 1.6 respectively. It would be interesting to have a direct comparison of this simple instrument with the more elaborate Trabectome in future in vivo studies to evaluate their respective effectiveness and safety profile.



Fig. 2.

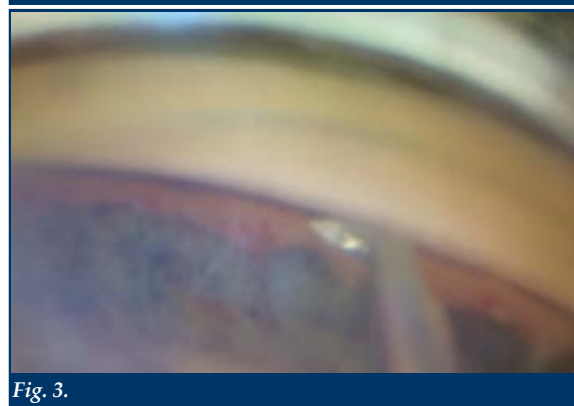

Fig. 3.

#### 2) iStent (Glaukos, CA, USA)

This micro-implant (G1 model, 1 x 0.3 mm in size and 60 micrograms in weight; Fig. 4.) received FDA approval in 2012, being the first MIGS device to do so. Unlike goniotomy (or ab interno trabeculotomy), no ablation or cutting of the TM is involved. Instead, a tiny nonferromagnetic titanium shunt (with a 120-micron lumen) is inserted thru the TM using its own specially designed preloaded injector, with one opening situated within the Schlemm's canal, and the other opening outside and communicating with the anterior chamber. Like goniotomy, the procedure is performed under gonioscopic viewing (Fig. 5.) with access provided by a clear corneal incision opposite to the surgical site,



THE **1<sup>ST</sup>**  $\beta_3$ -AGONIST FOR **OAB\* PATIENTS**  
 WITH PROMISING SAFETY PROFILE  
 PLACEBO-LIKE DRY MOUTH(1.7%) SIDE EFFECT<sup>1</sup>

YOUR **1<sup>ST</sup>** STEP FOR **MALE LUTS+ PATIENTS**  
 WITH PROMISING SAFETY PROFILE<sup>#</sup>  
 PLACEBO-LIKE DIZZINESS(1.4%) SIDE EFFECT<sup>2</sup>

# A FRESH STEP IN LUTS+ MANAGEMENT

Urgency  
 Slow Stream  
 Frequency



\*OAB: Overactive Bladder + LUTS: Lower Urinary Tract Symptoms  
 #  $\alpha_1$ -blockers are often considered the first line drug treatment of male LUTS<sup>3</sup>

Reference: 1. Chapple CR, et al. Neurourol Urodynam 2013 [doi:10.1002/nau.22505] 2. Chapple CR, et al. Eur Urol Supp. 2005; 4:33-44  
 3. Gravas S, et al. EAU Guidelines on the Treatment of Non-neurogenic Male LUTS. European Association of Urology. 2017.

**Abbreviated prescribing information of Harnal OCAS<sup>®</sup> 0.4 mg Tablets**

Version: 002 Pl version: Sep 2013. **Composition:** Tamsulosin HCl **Indication:** Lower urinary tract symptoms (LUTS) associated with benign prostatic hyperplasia (BPH). **Dosage:** 1 tab daily, can be taken independently of food. **Administration:** Swallow whole, do not chew/crush. **Contraindications:** Hypersensitivity to tamsulosin hydrochloride or to any of the excipients. **Special warnings and special precaution for use:** As with other  $\alpha_1$ -adrenoceptor antagonists, a reduction in blood pressure can occur in individual cases during treatment with Harnal OCAS<sup>®</sup> 0.4 mg Tablets, as a result of which, rarely, syncope can occur. At the first signs of orthostatic hypotension (dizziness, weakness), the patient should sit or lie down until the symptoms have disappeared. Before therapy with Harnal OCAS<sup>®</sup> 0.4 mg Tablets is initiated, the patient should be examined in order to exclude the presence of other conditions, which can cause the same symptoms as benign prostatic hyperplasia. Digital rectal examination and, when necessary, determination of prostate-specific antigen (PSA) should be performed before treatment and at regular intervals afterwards. Treatment of patients with a history of orthostatic hypotension should be approached with caution. The treatment of patients with severe renal impairment (creatinine clearance of <10 ml/min) should be approached with caution, as these patients have not been studied. **Undesirable effects:** The treatment of patients with severe hepatic dysfunction should be approached with caution. The 'Intraoperative Floppy Iris Syndrome' (IFIS, a variant of small pupil syndrome) has been observed during cataract and glaucoma surgery in some patients on or previously treated with tamsulosin hydrochloride. IFIS may increase the risk of eye complications during and after the operation. Discontinuing tamsulosin hydrochloride 1-2 weeks prior to cataract or glaucoma surgery is anecdotal<sup>4</sup> considered helpful, but the benefit of treatment discontinuation has not been established. IFIS has also been reported in patients who had discontinued tamsulosin for a longer period prior to the surgery. The initiation of therapy with tamsulosin hydrochloride in patients for whom cataract or glaucoma surgery is scheduled is not recommended. During pre-operative assessment, surgeons and ophthalmic teams should consider whether patients scheduled for cataract or glaucoma surgery are being or have been treated with tamsulosin in order to ensure that appropriate measures will be in place to manage the IFIS during surgery. Tamsulosin hydrochloride should not be given in combination with strong inhibitors of CYP3A4 in patients with poor metaboliser CYP2D6 phenotype. Tamsulosin hydrochloride should be used with caution in combination with strong and moderate inhibitors of CYP3A4. Cases of allergic reaction to tamsulosin in patients with a past history of sulfonamide allergy have been reported. If a patient reports a previously experienced sulfa allergy, caution is warranted when administering tamsulosin hydrochloride. **Contraindications:** Common (>1%, <10%), Uncommon (>0.1%, <1%), Rare (>0.01%, <0.1%), Very rare (<0.01%). **Cardiac disorder:** Uncommon: Palpitations. **Gastrointestinal disorders:** Uncommon: Constipation, diarrhoea, nausea, vomiting. **General disorders and administration site conditions:** Uncommon: Asthenia. **Nervous system disorders:** Common: Dizziness (1.3%), Uncommon: Headache, Rare: Syncope. **Reproductive system and breast disorders:** Common: Ejaculation disorders. **Very rare:** Priapism. **Respiratory, thoracic and mediastinal disorders:** Uncommon: Rhinitis. **Skin and subcutaneous tissue disorders:** Uncommon: Rash, pruritus, urticaria. **Rare:** Angioedema. **Vascular disorders:** Uncommon: Orthostatic hypotension. **Post-marketing experience:** The following events have also been reported during the post-marketing period. These events are reported voluntarily from a population of uncertain size, therefore it is not possible to reliably estimate their frequency; visual disorders (e.g. blurred vision, visual impairment), dermatitis exfoliative, erythema multiforme and epistaxis. During cataract and glaucoma surgery a small pupil situation, known as Intraoperative Floppy Iris Syndrome (IFIS), has been reported. **Full prescribing information is available upon request.**

**Abbreviated prescribing information of Betmiga<sup>®</sup> prolonged-release tablets**

Version: 003 Pl version: Apr 2016. **Composition:** Mirabegron **Indication:** Symptomatic treatment of urgency, increased micturition frequency and/or urgency incontinence as may occur in adult patients with overactive bladder (OAB) syndrome. **Dosage:** Adult including elderly 50 mg once daily with or without food. **Administration:** Swallow whole with liquids. Do not chew/divide/crush. **Contraindications:** Mirabegron is contraindicated in patients with - Hypersensitivity to the active substance or to any of the excipients. - Severe uncontrolled hypertension defined as systolic blood pressure  $\geq$  180 mm Hg and/or diastolic blood pressure  $\geq$  110 mm Hg. **Special warnings and precautions for use:** Renal impairment: Betmiga has not been studied in patients with end stage renal disease (GFR = 15 mL/min/1.73 m<sup>2</sup> or patients requiring haemodialysis) and, therefore, it is not recommended for use in this patient population. Data are limited in patients with severe renal impairment (GFR 15 to 29 mL/min/1.73 m<sup>2</sup>); based on a pharmacokinetic study a dose reduction to 25 mg is recommended in this population. Betmiga is not recommended for use in patients with severe renal impairment (GFR 15 to 29 mL/min/1.73 m<sup>2</sup>) concomitantly receiving CYP3A inhibitors. Hepatic impairment: Betmiga has not been studied in patients with severe hepatic impairment (Child-Pugh Class C) and, therefore, it is not recommended for use in this patient population. Betmiga is not recommended for use in patients with moderate hepatic impairment (Child-Pugh B) concomitantly receiving strong CYP3A inhibitors. Hypertension: Mirabegron can increase blood pressure. Blood pressure should be measured at baseline and periodically during treatment with Betmiga, especially in hypertensive patients. Data are limited in patients with stage 2 hypertension (systolic blood pressure  $\geq$  160 mm Hg or diastolic blood pressure  $\geq$  100 mm Hg). Patients with congenital or acquired QT prolongation: Betmiga, at therapeutic doses, has not demonstrated clinically relevant QT prolongation in clinical studies. However, since patients with a known history of QT prolongation or patients who are taking medicinal products known to prolong the QT interval were not included in these studies, the effects of mirabegron in these patients is unknown. Caution should be exercised when administering mirabegron in these patients. Patients with bladder outlet obstruction and patients taking antimuscarinic medications for OAB: Urinary retention in patients with bladder outlet obstruction (BOO) and in patients taking antimuscarinic medications for the treatment of OAB has been reported in post-marketing experience in patients taking mirabegron. A controlled clinical safety study in patients with BOO did not demonstrate increased urinary retention in patients treated with Betmiga; however, Betmiga should be administered with caution to patients with clinically significant BOO. Betmiga should also be administered with caution to patients taking antimuscarinic medications for the treatment of OAB. **Undesirable effects:** Summary of the safety profile: The safety of Betmiga was evaluated in 8,433 patients with OAB, of which 5,648 received at least one dose of mirabegron in the phase 2/3 clinical program, and 622 patients received Betmiga for at least 1 year (365 days). In the three 12-week phase 3 double blind, placebo controlled studies, 88% of the patients completed treatment with Betmiga, and 4% of the patients discontinued due to adverse events. Most adverse reactions were mild to moderate in severity. The most common adverse reactions reported for patients treated with Betmiga 50 mg during the three 12-week phase 3 double blind, placebo controlled studies are tachycardia and urinary tract infections. The frequency of tachycardia was 1.2% in patients receiving Betmiga 50 mg. Tachycardia led to discontinuation in 0.1% patients receiving Betmiga 50 mg. The frequency of urinary tract infections was 2.9% in patients receiving Betmiga 50 mg. Urinary tract infections led to discontinuation in none of the patients receiving Betmiga 50 mg. Serious adverse reactions included atrial fibrillation (0.2%). Adverse reactions observed during the 1-year (long term) active controlled (muscarinic antagonist) study were similar in type and severity to those observed in the three 12-week phase 3 double blind, placebo controlled studies. List of adverse reactions: The table below reflects the adverse reactions observed with mirabegron in the three 12-week phase 3 double blind, placebo controlled studies. The frequency of adverse reactions is defined as follows: very common ( $\geq$ 1/10); common ( $\geq$ 1/100 to <1/10); uncommon ( $\geq$ 1/1,000 to <1/100); rare ( $\geq$ 1/10,000 to <1/1,000); very rare (<1/10,000). Within each frequency grouping, adverse reactions are presented in order of decreasing seriousness. Infections and infestations: Common: Urinary tract infection. Uncommon: Vaginal infection, Cystitis. Psychiatric disorders: Not known (cannot be estimated from the available data); Insomnia\*. Eye disorders: Rare: Eyelid oedema. Cardiac disorders: Common: Tachycardia. Uncommon: Palpitation, Atrial fibrillation. Vascular disorders: Very rare: Hypertensive crisis\*. Gastrointestinal disorders: Common: Nausea\*, Constipation\*, Diarrhoea\*. Uncommon: Dyspepsia, Gastritis. Rare: Lip oedema. Skin and subcutaneous tissue disorders: Uncommon: Urticaria, Rash, Rash macular, Rash papular, Pruritus. Rare: Leukocytoclastic vasculitis, Purpura, Angioedema\*. Musculoskeletal and connective tissue disorders: Uncommon: Joint swelling. Reproductive system and breast disorders: Uncommon: Vulvovaginal pruritus. Investigations: Uncommon: Blood pressure increased, GGT increased, AST increased, ALT increased. Renal and urinary disorders: Rare: Urinary retention\*. Nervous system disorders: Common: Headache\*, Dizziness\*, \*observed during post-marketing experience. **Full prescribing information is available upon request.**



usually the main wound for phacoemulsification when performed together with cataract surgery, which is often the case. The second generation iStent (G2 or iStent inject) is even smaller (0.36 x 0.23 mm), making it the smallest approved medical implant for use in humans. In a multi-centre randomised control trial comparing phacoemulsification alone (control group) versus phacoemulsification with iStent in 240 eyes, the 12-month success rate, defined primarily as an unmedicated IOP of 21 mmHg or lower, or secondarily as an unmedicated IOP reduction of 20% or more, was significantly higher for subjects who received the iStent implant than those who did not, being 72% versus 50% for primary success and 66% versus 48% for secondary success<sup>16</sup>. At 24 months, primary and secondary success in the iStent group were 61% and 53%, compared to 50% and 44% for the control group<sup>17</sup>. In this study, there was no significant differences in adverse events between the two groups of subjects. More than one iStent can also be used in the same procedure to achieve a greater IOP reduction. A multi-centre prospective case series examining the use of 2 iStents (G2 model, Fig. 6.) as a solo procedure (not combined with cataract surgery) for 99 subjects with open angle glaucoma, reported 66% of subjects achieving an unmedicated IOP of 18 mmHg or less and 72% having an unmedicated IOP reduction of 20% or more, at 12 months after surgery. The mean IOP at 12 months postoperatively dropped from a mean baseline of 26.3 mmHg to 15.7 mmHg, with 71.7% of subjects being able to reduce their treatment requirement by 2 or more medications. In another prospective, randomised study comparing one, two or three iStents as a solo procedure in 119 subjects with POAG<sup>18</sup>, at 18 months after surgery, the mean unmedicated IOP was 15.9 mmHg among the one-stent subjects, 14.1 mmHg in the two-stent subjects, and 12.2 mmHg for the three-stent subjects, while glaucoma medications were required in 7 one-stent subjects, 4 two-stent subjects, and 3 three-stent subjects. Due to the higher effectiveness of inserting more than one implant, Glaukos (CA, USA) now supplies the second generation iStent (G2, or *iStent inject*) preloaded with 2 devices.



Fig. 4.

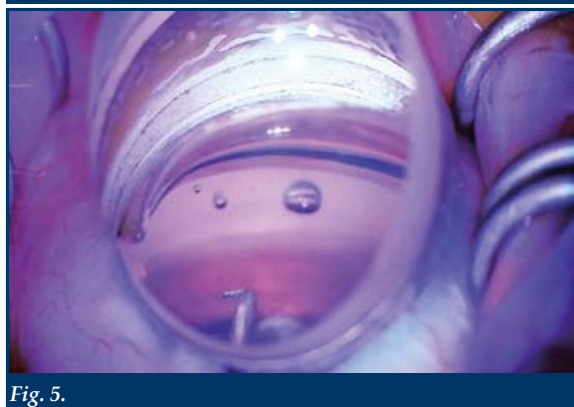

Fig. 5.



Fig. 6.

### 3) Hydrus (Ivantis, CA, USA)

Compared to the first and second generation iStents, the Hydrus Microstent is noticeably larger, being 8 mm in length (covering 3 clock hours of the TM), and designed to act as an intracanalicular scaffold that dilates the Schlemm's canal nine times its cross-sectional area. Made of flexible nitinol, an elastic nickel-titanium alloy, the curved device is designed to conform to the arc of the Schlemm's canal (Fig. 7.), with the non-intracanalicular end bypassing the TM and communicating with the anterior chamber directly. Similar to the iStent, it requires a clear corneal incision of 1-1.5 mm width (if not performed as combined procedure with phacoemulsification) opposite to the quadrant of insertion (usually nasal or inferior). As with any procedure involving an ab interno approach to the TM, good gonioscopic visualisation is a prerequisite (Fig. 8.) to successful placement (Fig. 9.). Unlike the iStent, it is still currently undergoing phase IV clinical trial in the USA. In the HYDRUS II Study, a randomised control study comparing combined Hydrus and phacoemulsification with phacoemulsification alone for 100 eyes with open angle glaucoma and cataract, at 24 months after surgery, in the eyes which received the Hydrus, 80% were able to achieve at least 20% IOP reduction and the mean unmedicated IOP was 16.9 mmHg; while for those who did not receive the Hydrus, only 46% were able to achieve at least 20% IOP reduction and the mean unmedicated IOP was 19.2 mmHg<sup>19</sup>. Almost 73% in the Hydrus group did not require glaucoma medication at 24 months, compared to around 38% in the non-combined surgery group.



Fig. 7.

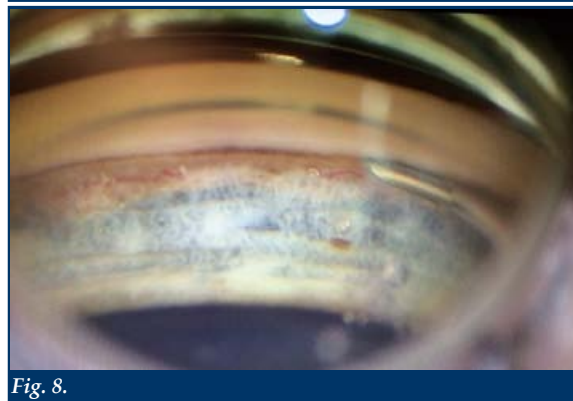



Fig. 8.


**Fig. 9.**

## Suprachoroidal space

Some aqueous leaves the anterior chamber into the suprachoroidal space normally, termed as uveoscleral outflow. Glaucoma medications which are prostaglandin analogues lower IOP by increasing this outflow, and some MIGS use a miniature shunt to direct even greater flow into the suprachoroidal space to try to reduce the IOP further.

### 1) CyPass Micro-Stent (Alcon, TX, USA)

The CyPass implant is a small stent inserted into the suprachoroidal space via an ab interno approach (Fig. 10.). The stent is made of polyamide material with a length of 6.35mm. There are openings along its whole length to allow aqueous to drain into the suprachoroidal space (Fig. 11.). A 1.5mm clear cornea insertion is made and the stent is implanted with a manual inserter and a guidewire to the suprachoroidal space. In a multi-centre randomised trial<sup>20</sup>, 505 patients with open angle glaucoma and cataract were randomised to phacoemulsification only or phacoemulsification with Cypass implantation. With a pre-operative IOP of 24.5mmHg & 24.4mmHg, the IOP was reduced by 5.4 mmHg in the phacoemulsification group and 7.4 mmHg in the Cypass group, respectively. In the Cypass group, 85% did not require medications at the end of second year and the mean number of medications was reduced by 67%. In another study<sup>21</sup> involving 55 phakic or pseudophakic eyes, stand-alone Cypass implantation procedures were performed. After 12 months, the mean IOP decreased from 24.5mmHg to 16.4mmHg while the number of medications reduced from 2.2 on average to 1.4. Adverse events such as implant obstruction, transient hyphema or IOP spike was uncommon in both studies.

**Fig. 10.****Fig. 11.**

## Subconjunctival space

Similar to trabeculectomy and tube-shunt in concept, this method seeks to create a new pathway for aqueous outflow from the anterior chamber of the eye into the subconjunctival space, but without the associated tissue trauma.

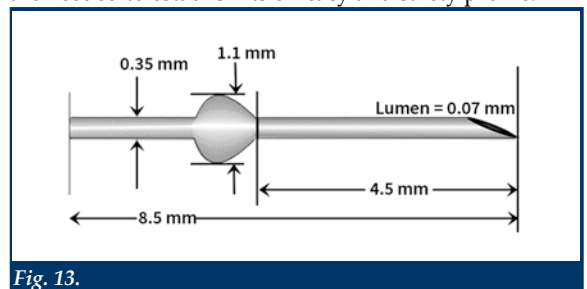
### 1) XEN (Allergan, CA, USA)

XEN gel stents aim to create a subconjunctival filtration bleb via an ab interno approach in eyes without pre-existing conjunctival scar. It is 6 mm in length and composed of porcine gelatin crosslinked with glutaraldehyde. It could be done with a cataract surgery or as a stand-alone procedure. The stent is implanted into the subconjunctival space via a small corneal incision, creating a fistula connecting the anterior chamber (Fig. 12.). An anti-metabolite such as mitomycin C (MMC) is usually injected subconjunctivally 20 minutes before the procedure to prevent bleb failure due to conjunctival scarring. A recently published prospective study involving 30 eyes with open angle glaucoma and cataract showed that the mean IOP reduction was 6.2 mmHg at 12 months, from preoperatively 21.2 mmHg to 15.0 mmHg, a 29.3% reduction. So far there are only limited clinical data and trials are still ongoing. Long-term studies are necessary to prove the efficacy as well as safety of XEN gel stents.

**Fig. 12.**

### 2) InnFocus Microshunt (Santen, Osaka, Japan)

In contrast to the XEN gel stents, the InnFocus Microshunt creates a subconjunctival filtration bleb via ab externo approach. The 8.5-mm long shunt (Fig. 13.) is made of a non-reactive, non-erodible polystyrene called SIBS. It is inserted ab externo into the anterior chamber via a 3-mm needle track after limited peritomy and subconjunctival mitomycin C application (Fig. 14.). The fin in the middle of the shunt would be sealing the scleral tract and anchoring the shunt within the sclera. According to a recent case series<sup>23</sup> of 79 eyes implanted with the device, 80% achieved IOP of 14 mmHg or less from a mean baseline of 24.8 mmHg at 4 years. Mean number of glaucoma medications needed also reduced from 2.3 at baseline, to 0.9, with 62% of patients taking no glaucoma medications. Very little clinical data are currently available for the device. Further clinical trials are needed to establish its efficacy and safety profile.

**Fig. 13.**



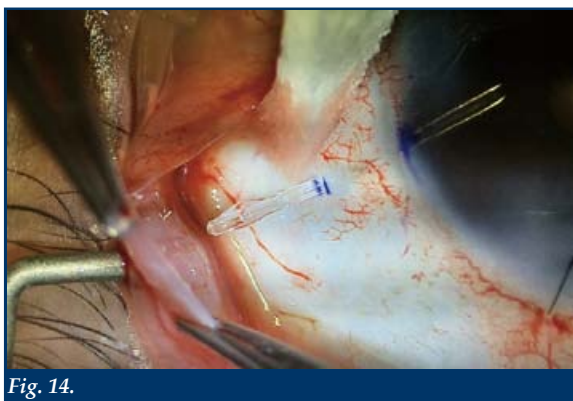


Fig. 14.

## Conclusion

The current popularity and variety of MIGS probably stem from a previously unmet need for surgical interventions which have a much better safety profile than the current standard of trabeculectomy and tube-shunts, as well as offering faster recovery and, in most cases, minimal or no conjunctival manipulation (thus maximising potential future sites for more aggressive procedures as needed). One trade off of MIGS has generally been the lower IOP reduction and increased cost compared to trabeculectomy and tube-shunts, which necessitate careful selection of suitable patients. Not all patients require aggressive IOP reduction (for example, less than 12 mmHg) or to be completely off all medications, especially if it will entail the possibility of serious complications. Many will tolerate using 1-2 glaucoma eye drops (or one fixed combination eye drop) postoperatively, if required, to achieve their target IOP. If cost is not an issue, then MIGS can allow for greater flexibility when planning for surgical intervention, especially in those with borderline suboptimal IOP control or treatment compliance issue, where the risks of standard surgical procedures like trabeculectomy may outweigh the possible benefits.

## Acknowledgement

The colour intra-operative photos were taken during the author's (JC) 4-week clinical attachment in June 2017 with Ike Ahmed in Toronto, Canada. Dr Ahmed is one of the pioneers and leading experts of MIGS.

## References

1. Glaucoma: diagnosis and management. London 2017.
2. Cairns JE. Trabeculectomy. Preliminary report of a new method. *Am J Ophthalmol.* 1968;66(4):673-679.
3. Wilkins M, Indar A, Wormald R. Intra-operative mitomycin C for glaucoma surgery. *Cochrane Database Syst Rev.* 2005(4):CD002897.
4. Spaeth GL, Mutlukan E. The use of antimetabolites with trabeculectomy: a critical appraisal. *Journal of glaucoma.* 2001;10(3):145-151.
5. Gedde SJ, Schiffman JC, Feuer WJ, et al. Treatment outcomes in the Tube Versus Trabeculectomy (TVT) study after five years of follow-up. *Am J Ophthalmol.* 2012;153(5):789-803 e782.
6. Vinod K, Gedde SJ, Feuer WJ, et al. Practice Preferences for Glaucoma Surgery: A Survey of the American Glaucoma Society. *Journal of glaucoma.* 2017;26(8):687-693.
7. Gedde SJ, Herndon LW, Brandt JD, et al. Postoperative complications in the Tube Versus Trabeculectomy (TVT) study during five years of follow-up. *Am J Ophthalmol.* 2012;153(5):804-814 e801.
8. Saheb H, Ahmed, II. Micro-invasive glaucoma surgery: current perspectives and future directions. *Curr Opin Ophthalmol.* 2012;23(2):96-104.
9. Richter GM, Coleman AL. Minimally invasive glaucoma surgery: current status and future prospects. *Clinical ophthalmology (Auckland, NZ).* 2016;10:189-206.
10. Lavia C, Dallorto L, Maule M, Ceccarelli M, Fea AM. Minimally-invasive glaucoma surgeries (MIGS) for open angle glaucoma: A systematic review and meta-analysis. *PLoS One.* 2017;12(8):e0183142.
11. Luntz MH, Livingston DG. Trabeculectomy ab externo and trabeculectomy in congenital and adult-onset glaucoma. *Am J Ophthalmol.* 1977;83(2):174-179.
12. Jea SY, Francis BA, Vakili G, Filippopoulos T, Rhee DJ. Ab interno trabeculectomy versus trabeculectomy for open-angle glaucoma. *Ophthalmology.* 2012;119(1):36-42.
13. Chow JTY, Hutnik CML, Solo K, Malvankar-Mehta MS. When Is Evidence Enough Evidence? A Systematic Review and Meta-Analysis of the Trabectome as a Solo Procedure in Patients with Primary Open-Angle Glaucoma. *J Ophthalmol.* 2017;2017:2965725.
14. Seibold LK, Soohoo JR, Ammar DA, Kahook MY. Preclinical investigation of ab interno trabeculectomy using a novel dual-blade device. *Am J Ophthalmol.* 2013;155(3):524-529 e522.
15. Greenwood MD, Seibold LK, Radcliffe NM, et al. Goniotomy with a single-use dual blade: Short-term results. *Journal of cataract and refractive surgery.* 2017;43(9):1197-1201.
16. Samuelson TW, Katz LJ, Wells JM, Duh YJ, Giamporcaro JE, Group USiS. Randomized evaluation of the trabecular micro-bypass stent with phacoemulsification in patients with glaucoma and cataract. *Ophthalmology.* 2011;118(3):459-467.
17. Craven ER, Katz LJ, Wells JM, Giamporcaro JE, iStent Study G. Cataract surgery with trabecular micro-bypass stent implantation in patients with mild-to-moderate open-angle glaucoma and cataract: two-year follow-up. *Journal of cataract and refractive surgery.* 2012;38(8):1339-1345.
18. Katz LJ, Erb C, Carceller GA, et al. Prospective, randomized study of one, two, or three trabecular bypass stents in open-angle glaucoma subjects on topical hypotensive medication. *Clinical ophthalmology (Auckland, NZ).* 2015;9:2313-2320.
19. Pfeiffer N, Garcia-Feijoo J, Martinez-de-la-Casa JM, et al. A Randomized Trial of a Schlemm's Canal Microstent with Phacoemulsification for Reducing Intraocular Pressure in Open-Angle Glaucoma. *Ophthalmology.* 2015;122(7):1283-1293.
20. Vold S, Ahmed II, Craven ER, et al. Two-year COMPASS trial results: Supraciliary microstenting with phacoemulsification in patients with open-angle glaucoma and cataracts. *Ophthalmology.* 2016;123(10):2103-2112.
21. Garcia-Feijoo J, Rau M, Grisanti S, et al. Supraciliary micro-stent implantation for open-angle glaucoma failing topical therapy: 1-year results of a multicenter study. *Am J Ophthalmol.* 2015;159(6):1075-1081.
22. Pérez-Torregrosa VT, Olate-Pérez A, Cerdá-Ibáñez M, et al. Combined phacoemulsification and XEN45 surgery from a temporal approach and 2 incisions. *Arch Soc Esp Oftalmol.* 2016;91(9):415-421.
23. Palmberg PF. Two-center results of a SIBS-based micro shunt at 1 to 4 years. Presented at: American Glaucoma Society annual meeting; March 2-5, 2017; Coronado, Calif.

TECNIS®  
*Symphony*  
Extended Range of Vision IOL

**LEAVE A LEGACY OF EXCELLENT OUTCOMES  
FOR PATIENTS WITH PRESBYOPIA.**

- Provides a **continuous, full range of high-quality vision** with decreased incidence of halos and glares.<sup>1</sup>
- Helps correct presbyopia and provides extended range of vision.<sup>1</sup>

TECNIS®  
FAMILY OF IOLS

TECNIS®  
*Symphony*  
Extended Range of Vision IOL

TEC  
ASPHERI

Talk to your Ophthalmologist today to find out the best IOL option for you.

Reference: 1. Data on File: 166\_Extended Range of Vision IOL 3-Month Study Results (NZ)

TECNIS® Symphony Extended Range of Vision Lenses are indicated for the visual correction of aphakia in adult patients, with and without presbyopia, in whom a cataractous lens has been removed by extracapsular independence. These devices are intended to be placed in the capsular bag. For a complete listing of precautions, warnings, and adverse events, refer to the package insert.

TECNIS and TECNIS Symphony are a trademarks owned by or licensed to Abbott Laboratories, its subsidiaries or affiliates.  
©2018 Abbott Medical Optics Inc.



*Start with* **ME.**

- Offers high independence from glasses at far, intermediate and near distances.<sup>1</sup>

**ARE CATARACTS  
CLOUDING VISION?  
TECNIS® Family of IOLs**

**NIS®**   
C I O L

**TECNIS®**  
TORIC ASPHERIC IOL

**TECNIS®**   
MULTIFOCAL IOL  
DIFFRACTIVE ASPHERIC




## Demyelinating and inflammatory optic neuropathies: an overview

**Dr Jonathan Chun-ho HO**

MBBS(HK), MSc(CUHK), MRCP(UK), FRCP(Edin),  
FRCS(Edin), DPD(Cardiff), FCOphthHK, FHKAM(Ophthalmology)  
Department of Ophthalmology, Tung Wah Eastern Hospital, Hong Kong

**Dr Andy Chi-on CHENG**

MBBS(Hons)(HK), MMedSc(HK), DPD(Cardiff), FRCSEd(Ophth),  
FCOphthHK, FHKAM(Ophthalmology)  
Department of Ophthalmology, Hong Kong Sanatorium & Hospital, Hong Kong



Dr Jonathan Chun-ho HO Dr Andy Chi-on CHENG

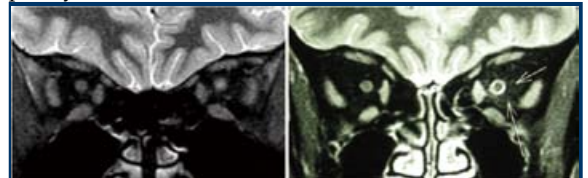
### Introduction

Optic neuritis (ON) is one of the leading causes of visual loss in the young to middle age populations worldwide, with the triad of visual loss, periorcular pain and dyschromatopsia<sup>1</sup>. Chinese patients, following an episode of ON, are found to have a lower conversion rate to multiple sclerosis (MS), compared to Caucasian populations. However, ON might well be the initial manifestation of neuromyelitis optica spectrum disorder (NMOSD), carrying a worse visual prognosis. Optic perineuritis (OPN) is a form of idiopathic orbital inflammatory disease (IOID) targeting the optic nerve sheath and its surrounding tissue, representing a key differential diagnosis of ON<sup>2</sup>. In this article, we will review our current understanding of these three disease entities, delineate features crucial for their differentiation in terms of presentation, investigation findings, treatment and prognosis.

### Idiopathic demyelinating optic neuritis (IDON) / Multiple sclerosis-associated optic neuritis (MS-ON)

The common age of presentation is 20 – 45 years, and its incidence to be three times higher in women. The classic pattern is subacute loss of vision progressing over a span of hours to 10 days, with a spectrum of severities ranging from mild acuity loss to no light perception and normally reaching its nadir within 2 weeks. Any form of visual field defect is possible in IDON / MS-ON, although the 15-year follow-up report from the Optic Neuritis Treatment Trial (ONTT) reported diffuse and central field losses to be more commonly detected at the initial visit, and partial arcuate, paracentral and arcuate losses in subsequent follow-ups<sup>3</sup>. Complete or near-complete recovery of visual acuity and field loss is usually seen - any progressive worsening of vision lasting over 2 weeks, or a lack of recovery beyond 8<sup>th</sup> week since symptom onset should prompt investigations for an alternative diagnosis. Dyschromatopsia occurs early on in the course of IDON / MS-ON and is often out of proportion to the degree of visual acuity deficit. Periorcular pain and retro-orbital pain occur in more than 90% of cases in a predominantly Caucasian population.<sup>4</sup> On the other hand, pain is less commonly a presenting feature in optic neuritis in the Chinese population, as low as to be about 28% in our local study<sup>24</sup>. It can precede or coincide with the onset of visual impairment, aggravated by eye movement but usually non-severe, and often resolves within days. A swollen optic nerve head is seen in 1/3 of cases.

In IDON, magnetic resonance imaging (MRI) with gadolinium typically demonstrates contrast enhancement of the affected optic nerve<sup>5</sup>. (Fig. 1) MRI brain with gadolinium may reveal the characteristic spatial and temporal dissemination of lesions as set forth by the 2010 McDonald MRI criteria<sup>6</sup>. The presence of demyelinating white matter lesions in brain MRI scans,  $\geq 3$  mm in diameter, ovoid in shape, located in periventricular white matter radiating toward the ventricular spaces has been identified as the single most predictive factor for conversion to clinically definite MS. In the ONTT, 25% of patients with no MRI lesions at presentation still went on to develop MS, 50% of those with 1 or more MRI lesions developed MS within 5 years<sup>7</sup> and 72% within 15 years. Optical coherence tomography (OCT) may be employed to visualise the retinal nerve fibre layer (RNFL), the thickness of which increases in the initial period of optic nerve swelling but subsequently decreases secondary to axonal loss. Such thinning is often less severe than in NMOSD-ON eyes<sup>8</sup>. Lumbar puncture might demonstrate raised cerebrospinal fluid oligoclonal bands alongside mild pleocytosis.



**Fig. 1.** MRI (coronal short TI inversion recovery images) of the orbit in patients with left optic neuritis showing hyperintensity of the optic nerve (left), left optic perineuritis showing perineural hyperintensity around the left optic nerve (donut sign) with dirty fat sign depicted with arrows (right)<sup>24</sup>

The clinical course of IDON is often favourable: spontaneous improvement in visual function is observed in more than 80% patients within 1 month<sup>9</sup> even in the absence of treatment, followed by stabilisation or sustained improvement up to 1 year. Acute management usually employs high-dose intravenous corticosteroids followed by an oral taper, which is shown to accelerate initial visual recovery. ONTT protocol is also recommended for typical ON patients in the presence of 3 or more MRI signal abnormalities, or patients requiring prompt resolution of visual deficits, including monocular patients, bilateral disease involvement, employment demands and patient preference<sup>10</sup>. Regarding long-term management, a number of disease-modifying agents, available in injections or oral medications, are available nowadays



to delay subsequent relapses and conversion to MS including  $\beta$ -interferons, glatiramer acetate, fingolimod, teriflunomide, dimethyl fumarate, natalizumab and alemtuzumab<sup>11</sup>.

## Inflammatory optic neuropathy

### Neuromyelitis optica spectrum disorder

NMOSD is an autoimmune inflammatory disorder of the central nervous system characterised by recurrent attacks of optic neuritis and transverse myelitis, features also found in MS. NMO has been considered a variant of MS, until in 2005 the discovery of serum antibodies against the water channel protein aquaporin-4 (AQP4) in NMO patients<sup>12</sup>.

While MS displays a prominent geographical distribution and prevails in the white population, NMO appears to have a more worldwide occurrence, with 20-50% of NMO patients quoted to be of non-white ethnicity in UK and US studies. The age of onset of symptoms is on average 10 years older than MS patients at initial presentation. Also, UK studies have reported over one-fifth of Caucasian NMO patients to have an age of onset over 60 years<sup>13</sup>. A very late age of onset may thus be in favour of a diagnosis of NMO. 50% of NMO patients initially present with isolated ON, among which 20% have bilateral involvement<sup>14</sup>. Isolated simultaneous bilateral optic neuritis, in particular, is a classical feature of NMO-ON. Importantly, NMO-ON causes more rapid, profound and persistent visual loss. During an acute attack 80% of NMO-ON sufferers experience a visual acuity of less than 20/200, compared to 36% in MS-ON. If inadequately treated, approximately 60% of NMO-ON patients experience unilateral or bilateral blindness at a median of 7.7 years following disease onset, in contrast to only 4% in MS-ON patients at 15-year follow up<sup>15-16</sup>. The optic nerve head can be of normal appearance. Altitudinal field deficits, if present, corroborate a diagnosis of NMO-ON<sup>17</sup>, although this can also occur in non-arteritic anterior ischaemic optic neuropathy. Relapses are much more common and severe than in IDON.

IgG-antibody to AQP4 is a sensitive and highly specific serum marker of NMO, and cell-based assays being the most reliable<sup>18</sup>. However, not all NMOSD patients have positive testing at presentation, thus we currently rely on the International Panel for NMO Diagnosis guidelines in 2015 to establish a clinical diagnosis<sup>19</sup>. It is stratified according to the AQP4-IgG status, and certain clinical and radiological criteria have to be fulfilled. Another IgG-antibody implicated in NMOSD is against myelin oligodendrocyte glycoprotein (MOG). Once thought to be a mild and usually monophasic variant, a retrospective review of 50 MOG antibody-positive cases revealed a multiphasic course in 80%, with severe visual impairment or functional blindness in 36% in long-term follow-up. 70% of eyes developed functional blindness in one or both eyes during at least one ON attack. Coexisting autoimmune disorders are more often seen in AQP4-IgG positive NMOSD (1/3), compared to MOG-IgG positive NMOSD (9%)<sup>20</sup>.

MRI typically shows optic nerve enhancement, which is more extensive, affecting posterior portions and/or

optic chiasm. MRI of the spinal cord might demonstrate longitudinally extensive transverse myelitis affecting  $\geq 3$  contiguous vertebral segments, with central/gray matter involvement and the presence of T1 hypointense acute lesion<sup>21</sup>. OCT of RNFL exhibits more marked peripapillary RNFL loss than in MS-ON, and a more widespread atrophy involving the superior and inferior quadrants<sup>8,22</sup>. In terms of CSF findings, NMOSD patients often have pleocytosis and may contain neutrophils and eosinophils, in contrast to the presence of lymphocytes and macrophages in MS patients. Oligoclonal bands, present in up to 95% of patients with MS, are only detected in 10-25% of patients with NMO.

Acute attacks should be treated with high-dose intravenous methylprednisolone for 3-5 consecutive days. For patients in whom symptoms are severe or refractory to steroid, plasmapheresis is a recommended adjunct. Once the diagnosis of NMO-ON is established, attack prevention should be taken in the form of long-term systemic immunosuppression via agents such as azathioprine, mycophenolate mofetil, rituximab, and oral glucocorticoids. There is no consensus on the optimal duration of immunosuppressive treatment, but the prevailing practice is for AQP4 seropositive patients to receive immunosuppression for a minimum of 5 years<sup>23</sup>. In general terms, delayed initiation and premature withdrawal of treatment is associated with poor outcome and recurrence.

### Optic perineuritis

OPN is a form of idiopathic orbital inflammatory disorder affecting the optic nerve dural sheath and is distinct from demyelinating optic neuritis<sup>24</sup>. While most cases are isolated and idiopathic, OPN occasionally occurs as a manifestation of a specific infectious or inflammatory disorder, such as Wegener's granulomatosis, giant cell arteritis, Crohn's disease, acute phase of secondary syphilis and neurosyphilis.

OPN tends to occur in older patient (age > 50) and progressive loss of acuity and/ or visual field loss (peripheral or arcuate) might last for weeks. Associated orbital sign such as diplopia, subtle ptosis and chemosis, might be present. There can be pain with eye movement and examination might reveal a swollen (50-70%)<sup>24,25</sup> or a normal-appearing optic disc.

MRI findings of OPN can be grouped anatomically into perineural, intraneural and orbital<sup>25</sup>. There is a characteristic pattern of enhancement in the optic nerve sheath, namely tram track and donut signs on axial and coronal cuts respectively. Streaky enhancement of extra-ocular muscles, sclera or orbital fat (dirty fat sign), and intraneural enhancement due to inflammation of pial septa, may be present. (Fig. 1 and 2)

Intravenous methylprednisolone can be considered as initial treatment to cover for both ON and OPN, especially if neuroimaging is not readily available. However, if the diagnosis of OPN is certain, a high dose of oral systemic steroid has proven to be effective also. Early initiation of high-dose oral prednisolone and prolonged treatment for OPN often lead to an excellent prognosis. It is essential to prevent irreversible visual

loss and recurrent attacks; delay in initiating therapy or premature withdrawal of corticosteroids can lead to poor visual outcomes.

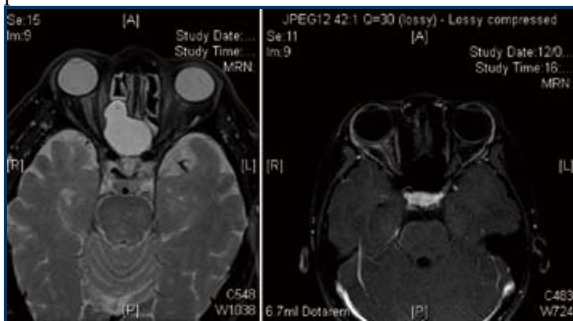


Fig. 2. MRI (coronal short TI inversion recovery images) of the orbit in a patient with right optic perineuritis demonstrating the tram track sign (right).

## Conclusion

MS-ON, NMO-ON and OPN have disparate pathogeneses and treatment responses. An accurate diagnosis among the three is paramount, as misdiagnosis and maltreatment may end up with poor ophthalmological and neurological outcome.

## References

1. Kaur P, Bennett JL. Optic Neuritis And The Neuro-Ophthalmology Of Multiple Sclerosis. *International Review of Neurobiology The Neurobiology of Multiple sclerosis*. 2007;633-63.
2. Sadiq SB, Corbett JJ, Abubakr A. Idiopathic optic perineuritis: Disguised as recurrent optic neuritis. *Clinical Neurology and Neurosurgery*. 2015;132:12-5.
3. Keltner JL. Visual Field Profile of Optic Neuritis. *Archives of Ophthalmology Arch Ophthalmol*. 2010Jan;128(3):330.
4. Shams PN, Plant GT. Optic neuritis: a review. *Int MS J*. 2009;16(3):82-89.
5. Kupersmith MJ, Alban T, Zeiffer B, Lefton D. Contrast-enhanced MRI in acute optic neuritis: relationship to visual performance. *Brain*. 2002Jan;125(4):812-22.
6. Polman CH, Reingold SC, Banwell B, et al. Diagnostic criteria for multiple sclerosis: 2010 revisions to the McDonald criteria. *Ann Neurol*. 2011;69:292-302.
7. The 5-year risk of MS after optic neuritis: Experience of the Optic Neuritis Treatment Trial. *Neurology*. 1997Jan;49(5):1404-13.
8. Ratchford JN, Quigg ME, Conger A, Frohman T, Frohman E, Balcer LJ, et al. Optical coherence tomography helps differentiate neuromyelitis optica and MS optic neuropathies. *Neurology*. 2009;73(4):302-8.
9. Beck RW. Optic Neuritis Treatment Trial. *Archives of Ophthalmology Arch Ophthalmol*. 1993Jan;111(6):773.
10. Balcer LJ. Optic neuritis. *N Engl J Med*. 2006;354:1273-80.
11. Scolding N, Barnes D, Cader S, et al. Association of British Neurologists: revised (2015) guidelines for prescribing disease-modifying treatments in multiple sclerosis. *Pract Neurol* 2015;15:273-279.
12. Lennox VA, Kryzer TJ, Pittock SJ, Verkman A, Hinson SR. IgG marker of optic-spinal multiple sclerosis binds to the aquaporin-4 water channel. *The Journal of Experimental Medicine J Exp Med*. 2005Aug;202(4):473-7.
13. Kitley J, Leite MI, Nakashima I, Waters P, Mcneillis B, Brown R, et al. Prognostic factors and disease course in aquaporin-4 antibody-positive patients with neuromyelitis optica spectrum disorder from the United Kingdom and Japan. *Brain*. 2012 Sep;135(6):1834-49.
14. Papais-Alvarenga RM. Clinical Course of Optic Neuritis in Patients With Relapsing Neuromyelitis Optica. *Archives of Ophthalmology Arch Ophthalmol*. 2008Jan;126(1):12.
15. Wingerchuk DM, Hogancamp WF, O'Brien PC, Weinshenker BG. The clinical course of neuromyelitis optica (Devic's syndrome). *Neurology*. 1999Jan;53(5):1107-14.
16. Sergott R. Visual Function 15 Years after Optic Neuritis: A Final Follow-up Report from the Optic Neuritis Treatment Trial. 2008;115:1079-82.e5.
17. Nakajima H, Hosokawa T, Sugino M, Kimura F, Sugasawa J, Hanafusa T, et al. Visual field defects of optic neuritis in neuromyelitis optica compared with multiple sclerosis. *BMC Neurology BMC Neurol*. 2010;10(1).
18. Jarius S, Wildemann B. Aquaporin-4 Antibodies (NMO-IgG) as a Serological Marker of Neuromyelitis Optica: A Critical Review of the Literature. *Brain Pathology*. 2013;23(6):661-83.
19. Wingerchuk DM, Banwell B, Bennett JL, et al. International consensus diagnostic criteria for neuromyelitis optica spectrum disorders. *Neurology*. 2015;85:177-89.
20. Jarius S, Ruprecht K, Kleiter I et al. MOG-IgG in NMO and related disorders: a multicenter study of 50 patients. Part 2: Epidemiology, clinical presentation, radiological and laboratory features, treatment responses, and long-term outcome. *J Neuroinflammation*. 2016 Sep 27;13(1):280.
21. Khanna S, Sharma A, Huecker J, Gordon M, Naismith RT, Stavern GPV. Magnetic Resonance Imaging of Optic Neuritis in Patients With Neuromyelitis Optica Versus Multiple Sclerosis. *Journal of Neuro-Ophthalmology*. 2012;32(3):216-20.
22. Naismith RT, Tutlam NT, Xu J, Klawiter EC, Shepherd J, Trinkaus K, et al. Optical coherence tomography differs in neuromyelitis optica compared with multiple sclerosis. *Neurology*. 2009;72(12):1077-82.
23. Carroll WM, Fujihara K. Neuromyelitis optica. *Curr Treat Options Neurol*. 2010; 12(3):244.
24. Cheng AC, Chan NC, Chan CK. Acute and subacute inflammation of the optic nerve and its sheath: clinical features in Chinese patients. *Hong Kong Med J*. 2012 Apr; 18(2): 115-22
25. Purvin V, Kawasaki A, Jacobson DM. Optic perineuritis: clinical and radiographic features. *Arch Ophthalmol*. 2001;119:1299-306.





Department of Orthopaedics and Traumatology  
Faculty of Medicine  
The Chinese University of Hong Kong  
香港中文大學 醫學院 矯形外科及創傷學系

# Master of Science in Musculoskeletal Medicine Rehabilitation and Geriatric Orthopaedics

## 骨關節醫學、康復及老年醫學理學碩士

### ■ Contents: Lectures, Practicum and Project

內容：講座、實習及論文

### ■ Course Structure: Full time 1 year / Part time 2 years study.

課程結構：全日制一年 / 兼讀制兩年

### ■ Who should apply ?

**Medical Doctors** – General Practitioners, Family Physicians, Orthopaedic Surgeons, Physicians interested in musculoskeletal disorders, Chinese Medicine Practitioners, Rehabilitation Doctors...

**Health Care Professionals** – Physiotherapists, Occupational Therapists, Prosthetists and Orthotists, Nurses, Dietitians, Podiatrists...

### ■ 報讀資格：

本培訓課程為醫療專業人員而設計，包括：家庭醫生及各專科醫生、中醫師、護士、物理治療師、職業治療師、矯形師、營養師、足治療師等等……

#### MSc in Musculoskeletal Medicine, Rehabilitation and Geriatric Orthopaedics (MRGO)

Core Modules (15 units)

Streaming Modules (8 units)  
(either stream)

Other Elective Modules (2 units)

Musculoskeletal Rehabilitation Stream

Geriatric Orthopaedics Stream

#### CME/CNE/CPD Accredited programme

香港持續醫學進修CME /  
持續護理進修CNE /  
持續專業發展計劃CPD學分課程

## September 2018 Intake 2018年9月入學招生

Online Application 在線報名：  
Graduate School Office Website 研究院網頁：



Application Deadline 截止申請日期：

30 April 2018 (Full time)

2018年4月30日 (全日制)

30 May 2018 (Part time)

2018年5月30日 (兼讀制)



Programme details and Information sessions  
Please refer to programme Website  
有關課程詳情及資訊講座，請查看課程網頁

查詢  
Enquiry

Department of Orthopaedics and Traumatology, Faculty of Medicine,  
The Chinese University of Hong Kong  
香港中文大學 醫學院 矯形外科及創傷學系  
Orthopaedic Learning Centre, 1st Floor, Li Ka Shing Specialist Clinics North Wing,  
Prince of Wales Hospital, Shatin, HKSAR  
香港 新界 沙田 威爾斯親王醫院 李嘉誠專科診所北翼 一樓 矯形外科及創傷學進修培訓中心  
Tel: (852) 2637 8472 Fax: (852) 2647 7432 Email: mrgo@ort.cuhk.edu.hk

# Latest Measures in Controlling Myopia Progression in Children

**Dr Patrick Kai-wah WU**

MBBS(HK), FRCS(Edin), FCS(HK), FCOphth(HK), FHKAM(Ophthalmology)

Private Practising Ophthalmologist



Dr Patrick Kai-wah WU

## Introduction and Definitions

Myopia (near- or short-sightedness) is the most common eye disorder in humans<sup>1</sup>. It is a refractive state where light rays from distant objects focus in front of, rather than on the retina. It can be secondary to excessive elongation of the eyeball, or less commonly, abnormally high refractive power of the cornea or lens. Most babies are hyperopic (long-sighted) at birth. This hyperopia gradually decreases in the first two years of life by changes in the cornea, lens and axial length. After that, the cornea and lens stabilise but myopia can continue to progress as the eyeball elongates over the next two decades<sup>2,3</sup>. In numeral terms, the severity of myopia is measured in dioptres (D). Simple myopia normally refers to those with myopia from 0.00 to 6.00 D, and myopia >6.00 D is often regarded as high myopia<sup>1</sup>. In Hong Kong, 1 D (or 1.00 D) is habitually spoken as '100 degrees' (and so on) by the general public.

## Epidemiology & Possible morbidities

Besides inconvenience and socio-economic costs to the individuals, myopia can be associated with many blinding eye conditions, including retinal detachment, macula degenerations (Fig. 1), premature cataract and glaucoma<sup>4-9</sup>. The prevalence of myopia is much higher in Asian countries compared to the West<sup>10</sup>. In Hong Kong, the myopia prevalence is 17.0% in children <7 years, which increases to 37.5% in 8-year-olds and 53.1% in children above 11 years<sup>5</sup>. Even more worrying, increasingly earlier onset is also observed. The prevalence of myopia in preschool children has escalated significantly from 2.3% to 6.3% over a ten-year period<sup>11</sup>. Myopia control has become a major health issue in many developed countries<sup>12</sup>.

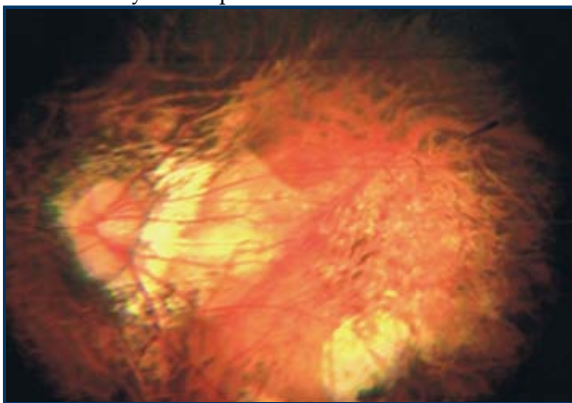


Fig. 1. Macula degeneration associated with high myopia

## Risk factors

Genetics plays a major role in a child's refractive error status, as shown in studies relating to myopic status of parents<sup>13-15</sup>, siblings or twin studies<sup>16,17</sup>. However, no single chromosomal locus has been associated with myopia development<sup>18</sup>. Environmental factors are also important, as shown in myopia association with education levels, years of schooling and school results<sup>19</sup>. Although near work has long been suspected a risk factor, few studies have found a strong correlation with either the onset or progression of myopia<sup>13-15</sup>. Increasing evidence suggests that the intensity of near work, i.e. sustained reading at closer distance (<30 cm) with few breaks, may be more important than the total hours<sup>19,20</sup>.

On the other hand, increasing outdoors time can decrease the likelihood of becoming myopic<sup>14,21,22</sup>. Studies suggested that 2-3 hours a day outdoors, outside of school hours, would provide considerable protection<sup>23,24</sup>. The postulated mechanisms include relations to light intensity, dopamine release and vitamin D<sup>25</sup>. Paradoxically, outdoors time, though beneficial to delaying the onset, does not slow down progression in established myopia<sup>23</sup>.

## Interventions to retard myopia progression

Many interventions aiming at retarding myopia progression have been proposed. In the latest meta-analysis involving 30 randomised controlled studies (RCTs)<sup>26</sup>, proven methods are not many. They are grouped under: (1) Pharmacological, or (2) Optical.

## Pharmacological Agents

### Atropine eye drops

Atropine is a non-selective muscarinic antagonist. Its efficacy for retarding myopia development was supported by human<sup>27-29</sup> and animal studies involving tree shrew, monkeys and chicks<sup>30-32</sup>. Blockage of accommodation by paralysing the ciliary muscles has long been thought to be the mechanism of atropine. Yet unlike the mammalian eye, the avian (chick) eye contains striated intra-ocular muscles only and has no muscarinic receptors; it indicates that the anti-myopic effect is via nicotinic pathway rather than accommodative mechanism<sup>32-34</sup>. Probably, atropine





functions via neurochemical cascade at M1 or M4 receptors in the retina; or atropine has a direct effect on scleral fibroblasts by inhibiting glycosaminoglycans synthesis via a non-muscarinic mechanism<sup>35</sup>.

As early as the 1960s, use of atropine to retard myopia progression has been shown to be effective in humans<sup>35</sup>. Yet the conventional use of 1% atropine (Fig. 2) unavoidably results in photophobia and blurred near vision, making its widespread usage not popular.

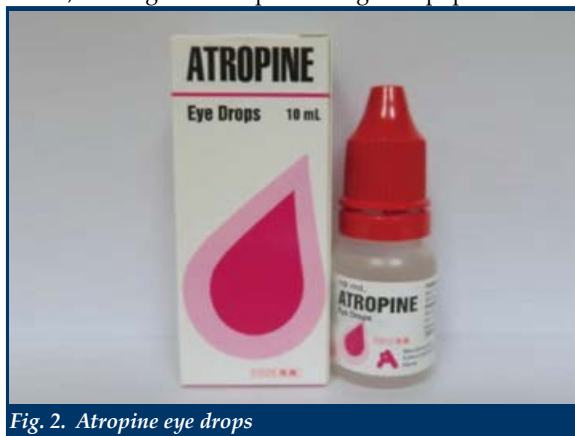

Fig. 2. Atropine eye drops

The 'Atropine for the Treatment of Myopia' studies (ATOM 1 & 2) by the Singapore group were randomised, double-masked, placebo-controlled trials involving 400 children<sup>36</sup>. ATOM 1 showed that 1% atropine eye drops instilled nightly in one eye over a 2-year period reduces myopia progression significantly by 77% (0.28 D with atropine versus 1.2 D in the control) and reduces the axial length elongation (0.39 mm in controls versus no growth in atropine group). The topical atropine was well tolerated without systemic side effects. Multifocal electroretinogram testing showed no significant effect on retinal function<sup>37</sup>. The pupil reactivity and accommodation paralysis were quickly reversible upon cessation of treatment<sup>38,39</sup>. Thus, the clinical safety and efficacy of atropine 1% is established.

At the ATOM 2 study, a slightly dose-dependent response to atropine was observed. The myopia progression of -0.49, -0.38 and -0.30 D in the atropine 0.01, 0.1 and 0.5% groups respectively at 24 months were shown<sup>40</sup>, but these differences were not significant. However, when atropine was stopped for 12 months after 24 months of treatment (phase 2 of ATOM2), a rebound increase in myopia progression was observed in children originally treated with higher concentrations of atropine, whereas those receiving the 0.01% concentration showed minimal change<sup>41</sup>. This resulted in significantly lower myopia progression in the 0.01% group (-0.72D) at 36 months, compared with that in the 0.1% (-1.04D) and 0.5% (-1.15D) groups. The 0.01% group also caused less pupil dilatation (thus minimal photophobia) and no significant loss of accommodation or near visual acuity (thus no need for progressive lenses).

In the final phase (phase 3), spanning the fourth and fifth years of ATOM2 study, children who continued to progress (>0.5D/year) during the washout phase were treated with atropine 0.01%<sup>42</sup>. Over 5 years, atropine 0.01% eye drops were effective in slowing myopia

progression by 50% compared with controls. It was concluded that atropine 0.01% has the best therapeutic index, with clinically insignificant visual side effects but remains as effective as higher doses<sup>35</sup>.

Separately, Taiwanese cohort studies using atropine 0.025-0.05% also proved its efficacy in slowing myopia<sup>43</sup>. And an USA study similarly found that atropine 0.01% significantly reduced myopic progression with minimal side effects in a mostly white population<sup>44</sup>.

Furthermore, atropine has been studied as a tool to prevent myopia onset. A retrospective cohort study conducted in Taiwan<sup>45</sup> over a period of 12 months on pre-myopic (<+1.0 D hyperopia) showed that 0.025% atropine can prevent myopia onset (myopic shift was -0.14D/yr c.f. -0.58 D/yr) ( $P < 0.0001$ ), and the percentage of children with onset of myopia was reduced from 54% to 21% ( $P = 0.016$ ).

## Pirenzepine Ophthalmic Gel

In contrast to atropine (a non-selective anti-muscarinic agent), pirenzepine blocks M1 receptors only, which are less concentrated in the iris and ciliary body. It does not dilate the pupil or reduce accommodation as much as atropine. Topical pirenzepine 2% eye gel used twice daily in two RCTs showed approximately 40% reduction in myopia progression with a corresponding reduction in axial elongation after 12 months<sup>46,47</sup>. However, further trials and registration of this drug were not continued, and pirenzepine gel is no longer available.

## Optical methods

### Bifocals & Progressive Spectacles

These glasses allow children to clearly see far objects through the top portion of the lens while the bottom portion contains the reading power.

Animal and human studies suggest that increased retinal defocus and high accommodative lag are associated with myopia progression<sup>48</sup>. Bifocals or progressives were postulated to provide clear vision over a range of viewing distances to reduce retinal defocus, and slow myopia progression. However, RCTs showed no significant slowing of myopia with bifocals<sup>49,50</sup>, or only have a small but significant benefit in retarding myopia progression in children with near point esophoria only.

On the other hand, RCTs on the use of progressive additive lenses suggested either no effect on myopia retardation or a minor but significant effect in the first year only<sup>51,52</sup>. It is concluded that bifocals or progressive lenses to correct myopic children have little effect (-0.50D at most) on myopia retardation, and this effect is probably too modest to warrant a change from the use of single vision lenses to bifocals or progressive lenses<sup>51</sup>.

### Contact Lenses

RCTs showed that ordinary soft contact lenses and rigid gas permeable (RGP) lenses were not effective in



retarding myopia progression<sup>53,54</sup>. In the CLAMP study, the difference in myopia progression was probably attributable to less corneal curvature steepening only<sup>55</sup>.

Orthokeratology (also known as OK, ortho-K and corneal reshaping) is a type of RGP contact lens to be worn at bedtime and removed upon waking. It temporarily reshapes (flattens) the central cornea and provides a clear vision during the day without any glasses or contact lenses. It gives convenience to children especially for activities like sports. OK lenses correct central refractive error while leaving peripheral myopic blur, which may act a putative cue to slow myopia progression<sup>56</sup>.

Orthokeratology has shown to slow axial length growth compared to single vision RGP lenses, single vision soft contact lenses, and single vision spectacles<sup>56-58</sup>. The first RCT on orthokeratology myopia control demonstrated significantly slower mean axial elongation in children wearing OK lenses (0.36+/-0.24 mm) than wearing single vision spectacles (0.63+/-0.26mm) over a 2-year period<sup>58</sup>. As shown in a recent meta-analysis of seven eligible studies, myopic progression was reduced by approximately 45% after 2 years<sup>56</sup>. However, no well-controlled, long-term study demonstrating sustained myopia control effect is available, and numerous potentially blinding complications including microbial keratitis (Fig. 3) related to orthokeratology have been reported<sup>59,60,61</sup>. The risks associated with OK lenses must be carefully weighed against possible benefits, and parents should be adequately counselled before decision for use in their children<sup>62</sup>.

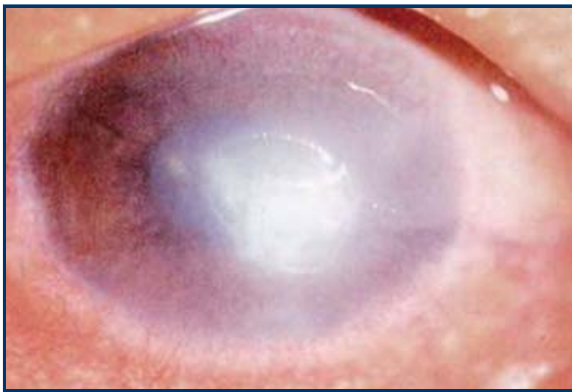

Fig. 3. Microbial keratitis secondary to ortho-K wear

## Peripheral retinal defocus spectacles or contact lenses

Like OK lenses creating peripheral myopic blur, spectacle lenses that decreased relative peripheral hyperopia were found to reduce myopia progression in children significantly in a study<sup>63</sup>, while little consistent influence was shown in others<sup>64-66</sup>. The rate of myopia progression was reduced by approximately 30% in eyes wearing contact lenses designed to reduce hyperopic defocus compared with single-vision spectacles<sup>67</sup>. It was also shown that daily wearing of a "defocus incorporated soft contact" lens (a bifocal soft contact lens with concentric rings design) retards myopia progression by 25% compared with single vision lenses<sup>68</sup>. However, longer term results are still awaited for these newer designs.

## Under-correction/part-time wear of spectacles

The objectives of undercorrection were to achieve myopic defocus, and to reduce the accommodative stress in near-point environments. However, prospective clinical trials suggest that undercorrection of myopia in humans either increases or has no effects on myopia progression<sup>69,70</sup>.

Concerning the pattern of wear, preliminary data on 43 patients suggest that there is no effect on the progression of myopia with either of: full-time wear, myopes who switched from distance to full-time wear, distance wearers or non-wearers<sup>71</sup>. Larger randomised controlled studies are warranted.

## Conclusion

Myopia is highly prevalent in Hong Kong, and the incidence is on the rise. Both genetic and environmental factors are involved. Atropine 0.01% produces clinically significant 50% reduction in myopia progression while having no significant visual side effects, thus appears to have a good risk-benefit ratio. Higher concentrations atropine may have a role in some children (e.g. fast progressors). The potential additive beneficial effect of combining atropine with other therapies (e.g. orthokeratology, peripheral defocus lenses) will need further evaluation.

Orthokeratology also appears to slow axial elongation by approximately 40%, but potential cornea-related complications need serious consideration. Peripheral defocusing lenses (contact lenses or spectacles) may have a role in slowing myopia progression.

The epidemic of myopia is related to its increasingly early onset, together with rapid rates of progression. Ideally, myopic control involves delaying its onset and retarding its progression. Increased outdoor time can reduce the onset of myopia. Low dose atropine eye drops may also have a role in its prevention.

## References

1. Wu PC, Huang HM, Yu HJ, et al. Epidemiology of myopia. *Asia Pac J Ophthalmol* 2016; 5:386-393
2. Gordan RA, Donzis PB. Refractive development of the human eye. *Arch Ophthalmol* 1985;103(6):785-9
3. Fan DS, Lam DS, Lam RF, et al. Prevalence, incidence, and progression of myopia of schoolchildren in Hong Kong. *Invest Ophthalmol Vis Sci*. 2004 Apr; 45(4):1071-5
4. Arevalo JF, Ramirez E, et al. Rheumatogenous retinal detachment after laser-assisted in situ keratomileusis (LASIK) for the correction of myopia. *Retina* 2000;20:338-41
5. Arevalo JF, Azar-Arevalo O. Retinal detachment in myopic eyes after I laser-assisted in situ keratomileusis. *Am J Ophthalmol* 2000; 129:825-6
6. Avila MP, Weiter JJ, Jalkh AE, et al. Natural history of choroidal neovascularization in degenerative myopia. *Ophthalmology* 1984; 91:1573-81
7. Steidl SM, Pruett RC. Macular complications associated with posterior staphyloma. *Am J Ophthalmol* 1997; 123:181-7
8. Vongphanit J, Mitchell P, Wang JJ. Prevalence and progression of myopic retinopathy in an older population. *Ophthalmology* 2002; 109:704-11
9. Mitchell P, Hourihan F, Sandbach J, et al. The relationship between glaucoma and myopia: the Blue Mountains Eye Study. *Ophthalmology* 1999; 106:2010-5
10. Pan CW, Ramamurthy D, Saw SM. Worldwide prevalence and risk factors for myopia. *Ophthalmic Physiol Opt* 2012; 32(1):3-16
11. Fan DS, Lai C, Lau HH, et al. Change in vision disorders among Hong Kong preschoolers in 10 years. *Clin Experiment Ophthalmol* 2011; 39(5):398-403



12. Morgan IG, He M, Rose KA. Epidemic of pathologic myopia: what can laboratory studies and epidemiology tell us? *Retina*. 2017 May; 37(5):989-997
13. Saw SM, Shankar A, Tan SB, et al. A cohort study of incident myopia in Singaporean children. *Invest Ophthalmol Vis Sci*. 2006; 47(5):1839-44
14. Jones LA, Ainnott LT, Mutti DO, et al. Parental history of myopia, sports and outdoor activities, and future myopia. *Invest Ophthalmol Vis Sci*. 2007;48(8):3524-32
15. Mutti DO, Mitchell GL, Moeschberger ML, et al. Parental myopia, near work, school achievement, and children's refractive error. *Invest Ophthalmol Vis Sci*. 2002;43(12):3633-40
16. Hammond CJ, Snieder H, Gilbert CE, Spector TD. Genes and environment in refractive error: the twin eye study. *Invest Ophthalmol Vis Sci*. 2001;42(6):1232-6
17. Lyhne N, Sjolie AK, Kyvik KO, et al. The importance of genes and environment for ocular refraction and its determiners: a population based study among 20-45 year old twins. *Br J Ophthalmol*. 2001;85(12):1470-6
18. Molly JS, Jeffrey JW. Controlling myopia progression in children and adolescents. *Adolesc Health Med Ther*. 2015;6:133-40
19. You OS, Wu LI, Duan JL, et al. Factors associated with myopia in children in China: the Beijing childhood Eye Study. *PLOS One* 2012;0052668
20. Lee YY, Lo CT, Sheu SJ, et al. What factors are associated with myopia in young adults? A survey study in Taiwan military conscripts. *Invest Ophthalmol Vis Sci* 2013;54:1026-33
21. Dirani M, Tong L, Gazzard G, et al. Outdoor activity and myopia in Singaporean children. *Br J Ophthalmol*. 2009;93(8):997-1000
22. Guggenheim JA, Northstone K, McMahon G, et al. Time outdoors and physical activity as predictors of incident myopia in childhood: a prospective cohort study. *Invest Ophthalmol Vis Sci*. 2012;53(6):2856-65
23. Jones-Jordan LA, Sinnott LT, Cotter SA, et al. Time outdoors, visual activity and myopia progression in juvenile onset myopes. *Invest Ophthalmol Vis Sci* 2012; 53:7169-75
24. French AN, Morgan IG, Mitchell P, et al. Risk factors for incident myopia in Australian school children: the Sydney adolescent vascular and eye study. *Ophthalmology* 2013; 120:2100-8
25. Rose KA, Morgan IG, Ip J, et al. Outdoor activity reduces the prevalence of myopia in children. *Ophthalmology* 2008;115(8):1279-85
26. Huang J, Wen D, Wang O, et al. Efficacy comparison of 16 interventions for myopia control in children: a network meta-analysis. *Ophthalmology* 2016; 123:697-708
27. Bedrossian RH. The effect of atropine on myopia. *Ann Ophthalmol* 1971; 3:891-7
28. Gimbel HV. The control of myopia with atropine. *Can J Ophthalmol* 1973; 8:527-32
29. Dyer JA. Role of cycloplegics in progressive myopia. *Ophthalmology* 1979; 86:692-4
30. McKanna JA, Casagrande VA. Atropine affects lid-suture myopia development: Experimental studies of chronic atropinization in tree shrews. *Doc Ophthalmol Proc Series* 1981; 28:187-92
31. Raviola E, Wiesel TN. An animal model of myopia. *N Engl J Med* 1985; 312:1609-15
32. Tigges M, Juvone PM, Fernandes A, et al. Effects of muscarinic cholinergic receptor antagonists on postnatal growth of rhesus monkeys. *Optom Vis Sci* 1999; 76:398-407
33. Stone RA, Lin T, Latties AM. Muscarinic antagonist effects on experimental chick myopia. *Exp Eye Res* 1991; 52:755-8
34. Glasser A, Howland HC. A History of studies of visual accommodation in birds. *Q Rev Biol* 1996; 71:475-509
35. McBrien NA, Moghaddam HO, Reeder AP. Atropine reduces experimental myopia and eye enlargement via a nonaccommodative mechanism. *Invest Ophthalmol Vis Sci* 1993; 34:205-15
36. Chua WH, Balakrishnan V, Vhan YH, et al. Atropine for the treatment of childhood myopia. *Ophthalmology* 2006; 113:2285-91
37. Luu CD, Lau AM, Koh AH, Tan D. Multifocal electroretinogram in children on atropine treatment for myopia. *Br J Ophthalmol* 2005; 89:151-3
38. Scheiman MM, Hertle RW, Beck RW, et al. Pediatric Eye Disease Investigator Group. Randomized trial of treatment of amblyopia in children aged 7 to 17 years. *Arch Ophthalmol* 2005; 123:437-447
39. Tong L, Huang XL, Koh AL, et al. Atropine for the treatment of childhood myopia; effect on myopia progression after cessation of atropine. *Ophthalmology* 2009; 116:572-9
40. Chia A, Chua WH, Cheung YB, et al. Atropine for the treatment of childhood myopia: safety and efficacy of 0.5%, 0.1%, and 0.01% doses (ATOM2). *Ophthalmology* 2012; 119:347-354
41. Chia A, Chua WH, Li W, et al. Atropine for the treatment of childhood myopia: changes after stopping atropine 0.01%, 0.1% and 0.5% (ATOM2). *Am J Ophthalmol* 2014; 157:451-7
42. Chia A, Lu QS, Tan D. Five-year clinical trial on atropine for the treatment of myopia 2: myopia control with atropine 0.01% eye drops. *Ophthalmology* 2016; 123:391-9
43. Wu PC, Yang YH, Fang PC. The long-term results of using low-concentration atropine eye drops for controlling myopia progression in school children. *J Ocul Pharmacol Ther* 2011; 27:461-6
44. Clark TY, Clark RA. Atropine 0.01% eyedrops significantly reduce the progression of childhood myopia. *J Ocul Pharmacol Ther* 2015; 31:541-5
45. Fang PC, Chung MY, Yu HJ, et al. Prevention of myopia onset with 0.025% atropine in premyopic children. *J Ocul Pharmacol Ther* 2010; 26:341-5
46. Tan D, Lam DS, Chua WH, et al. One-year multicenter, double-masked, placebo-controlled, parallel safety and efficacy study of 2% pirenzepine ophthalmic gel in children with myopia. *Ophthalmology* 2005; 112:84-91
47. Siatkowski RM, Cottoer SA, Crockett RS, et al. Two-year multicenter, randomized double-masked, placebo-controlled, parallel safety and efficacy study of 2% pirenzepine ophthalmic gel in children with myopia. *JAAPOS* 2008; 12:332-9
48. Gwiazda J, Thom F, Bauer J, Held R. Myopic children show insufficient accommodative response to blur. *Invest Ophthalmol Vis Sci* 1993; 34:690-4
49. Jensen H. Myopia progression in young school children: a prospective study of myopia progression and the effect of a trial with bifocal lenses and beta blocker eye drops. *Acta Ophthalmol Suppl* 1991; 200:1-79
50. Fulk GW, Cyert LA, Parker DE. A randomized trial of the effect of single-vision vs. bifocal lenses on myopia progression in children with esophoria. *Optom Vis Sci* 2000; 77:395-401
51. Edwards MH, Li RW, Lam CS, et al. The Hong Kong progressive lens myopia control study: study design and main findings. *Invest Ophthalmol Vis Sci* 2002; 43(9):2852-8
52. Gwiazda J, Hyman L, Hussein M, et al. A randomized clinical trial of progressive addition lenses versus single vision lenses on the progression of myopia in children. *Invest Ophthalmol Vis Sci* 2003; 44(4):1492-1500
53. Fulk GW, Cyert LA, Parker DE, et al. The effect of changing from glasses to soft contact lenses on myopia progression in adolescents. *Ophthalmic Physiol Opt* 2003; 23:71-77
54. Katz J, Schein OD, Levy B, et al. A randomized trial of rigid gas permeable contact lenses to reduce progression of children's myopia. *Am J Ophthalmol* 2003; 136:82-90
55. Walline JJ, Jones LA, Mutti DO, et al. A randomized trial of the effects of rigid contact lenses on myopia progression. *Arch Ophthalmol* 2004; 122:1760-6
56. Kakita T, Hiraoka T, Oshika T. Influence of overnight orthokeratology on axial elongation in childhood myopia. *Invest Ophthalmol Vis Sci* 2011; 52:2170-4
57. Cho P, Cheung SW, Edwards M. The longitudinal orthokeratology research in children (LORIC) in Hong Kong: a pilot study on refractive changes and myopic control. *Curr Eye Res* 2005; 30:71-80
58. Cho P, Cheung SW. Retardation of myopia in Orthokeratology (ROMIO) study: a 2-year randomized clinical trial. *Invest Ophthalmol Vis Sci* 2012; 53:7077-85
59. Van Meter WS, Musch DC, Jacobs DS, et al. Safety of overnight orthokeratology for myopia: a report by the American Academy of Ophthalmology. *Ophthalmology* 2008; 115:2301-13
60. Young AL, Leung AT, Cheng LL, et al. Orthokeratology lens related corneal ulcers in children: a case series. *Ophthalmology* 2004 Mar; 111(3):590-5
61. Wong VW, Lai TY, Chi SC, et al. Pediatric ocular surface infections: a 5-year review of demographics, clinical features, risk factors, microbiological results, and treatment. *Cornea* 2011 Sep;30(9):995-1002
62. Kwok MK, Yam JC, Lee SM, et al. An update on the interventions and strategies in preventing myopia progression. *HK Pract* 2013;35:91-96
63. Sankaridurg P, Donoval L, Vamas S, et al. Spectacle lenses designed to reduce progression of myopia: 12 month results. *Optom Vis Sci* 2010; 87:631-41
64. Smith MJ, Walline JJ. Controlling myopia progression in children and adolescents. *Adolesc Health Med Therapeut* 2015; 6:133-40
65. Mutti D, Sinnott L, Mitchell G, et al. Relative peripheral refractive error and the risk of onset and progression of myopia in children. *Invest Ophthalmol Vis Sci* 2011; 52:199-205
66. Sing CC, Lin XY, Gazzard G, et al. Change in peripheral refraction over time in Singapore Chinese children. *Invest Ophthalmol Vis Sci* 2011; 52:7880-7
67. Sankaridurg P, Holden B, Smith 3rd E, et al. Decrease in rate of myopia progression with a contact lens designed to reduce relative peripheral hyperopia: one year results. *Invest Ophthalmol Vis Sci* 2011; 52:9362-7
68. Lam CS, Tang WC, Tse DY, et al. Defocus incorporated soft contact (DISC) lens slows myopia progression in Hong Kong Chinese schoolchildren: a 2-year randomized clinical trial. *Br J Ophthalmol*. 2014 Jan; 98(1):40-5
69. Adler D, Millodot M. The possible effect of undercorrection on myopic progression in children. *Clin Exp Optom*. 2006;89(5):315-21
70. Chung K, Mohidin N, O'Leary DJ. Undercorrection of myopia enhances rather than inhibits myopia progression. *Vision Res*. 2002;42(22):2555-9
71. Ong E, Grice K, Held R, et al. Effects of spectacle intervention on the progression of myopia in children. *Optom Vis Sci* 1999; 76:363-9



## Certificate Course on

# Best Practices in Quality of Life Evaluation & Assessments

**Jointly organised by**

The Federation of Medical  
Societies of Hong Kong



World Association for  
Chinese Quality of Life

**Objectives:**

This course equips participants the know-how of evaluating and assessing quality of life (QoL) in both healthy and ill individuals. Since the development of an index for assessing quality of life in the 60's, the measurement of health-related quality of life has made a phenomenal impact on the evaluation of health care and medical interventions. Nowadays, numerous measures have been developed across a wide range of clinical areas, including but not limited to neurology, oncology, cardiology, and palliative care. The best use of these tools is hinged on a good understanding of their developmental framework, extent of evaluation, and use in practice. In response to this need, this course provides the necessities for healthcare professionals to choose, evaluate and conduct QoL assessment in practice.

(The World Association for Chinese Quality of Life (WACQOL) is a non-profit organization dedicated to the education and research of quality of life in the Chinese population. Please do learn more of us at <http://wacqol.org>)

Date	Topics	Speakers
3 May	Principles and Concepts of Quality of Life (QoL)	<b>Dr. Wendy WONG</b> Assistant Professor, Hong Kong Institute of Integrative Medicine, School of Chinese Medicine The Chinese University of Hong Kong
10 May	Basic Statistics for Evaluation of QoL Measures	<b>Dr. Daniel FONG</b> Associate Professor, School of Nursing The University of Hong Kong
17 May	Linguistic and Psychometric Evaluation of QoL Measures	<b>Dr. Daniel FONG</b> Associate Professor, School of Nursing The University of Hong Kong
24 May	Interpreting QoL in Practice	<b>Dr. Daniel FONG</b> Associate Professor, School of Nursing The University of Hong Kong
31 May	Using QoL in Health Evaluation	<b>Dr. Carlos WONG</b> Assistant Professor (Research), Department of Family Medicine and Primary Care The University of Hong Kong
7 Jun	Assessing QoL in Cancer Patients	<b>Dr. Winnie SO</b> Associate Professor, The Nettersole School of Nursing The Chinese University of Hong Kong

**Dates :** 3, 10, 17, 24, 31 May 2018 & 7 June, 2018 (Every Thursday)

**Time :** 7:00 pm – 8:30 pm

**Venue :** Lecture Hall, 4/F., Duke of Windsor Social Service Building, 15 Hennessy Road, Wanchai, Hong Kong

**Language Media :** Cantonese (Supplemented with English)

**Course Fee :** HK\$750 (6 sessions)

**Certificate :** Awarded to participants with a minimum attendance of 70%

**Enquiry :** The Secretariat of The Federation of Medical Societies of Hong Kong

Tel: 2527 8898

Fax: 2865 0345

Email: [info@fmshk.org](mailto:info@fmshk.org)

**CME (including Chinese Medicine Practitioners) / CNE / CPD Accreditation in application**

Application form can be downloaded from website: <http://www.fmshk.org>





## Walking With the Poor Communities

### Dr Nim-chung CHAN

MBBS(HK), FRCS (Glasgow), FCS(HK), FRCOphth, FHKAM(Ophthalmology), FCOphthHK  
*Private Practising Ophthalmologist*



Dr Nim-chung CHAN

“Good morning! You are still alive?” That was how we sometimes jokingly greeted each other with the local friends in Afghanistan after heavy aerial bombing or rocketing through the nights. I was living and working in Kabul, capital of Afghanistan, with my wife from 1993 to 1999. I was the Medical Director of the NOOR Eye Institute, and my wife was working in the Physiotherapy School of Kabul. She is an occupational therapist specialised in children with disabilities. Both of these specialties of ophthalmology and rehabilitation, which are usually slow to develop in poor countries, were started by the organisation that we worked with, the International Assistance Mission, in the 60s and 80s respectively.

Those years were life-changing for us. In the first 3 years 4 factions of the Mujahideen (freedom fighters) were fighting each other in Kabul. Then the extremist Taliban entered the city in 1996. In fact the war has never stopped till now. The book and the term “The Great Game” well describes and explains the history, social-economic and political turmoil of Afghanistan. The Soviets, British, Americans, and neighbouring countries were all interested. The central high mountain range forms a natural barrier between the former Soviet Union and the former British India. Central Asia is rich in oil. Afghanistan has some natural gas and semi-precious stones. Only recently lithium worths US\$1 to 3 trillion has been found in the country! In addition, the majority Pashtun tribe was divided by the Afghan-Pakistani border set by the British. They demanded a Pashtunistan country of their own, which never happened. And the Taliban, formed mainly by the Pashtuns, gradually rose after the Soviets left. All these contributed to the longstanding unrest of Afghanistan. To date, the largest population of refugees comes from Syria, and the second is still Afghanistan.

We learned the language Dari, lived amidst the heavy fightings, struggled together with the Afghans. Almost all of our local colleagues, citizens and even officials of the Islamic government are friendly and helpful to us. Surprisingly our medical training and facilities continued to develop during the worst time. I managed to start their professional diploma examination for ophthalmologists. They are still continuing with that now.

Looking back, there are many things I could not have learned if I were to live in Hong Kong only. I notice that there is a broad spectrum of the attitudes and behaviours of aid workers and also donors in relief and development work. But to me it was a humbling

experience. Too easily we point our fingers at the wrong-doers and government leaders. But in fact we are all part of the world exploiting and discriminating others. Not that the victims are more holy, but often through the striving of the poor people, they demonstrate the bright side of humanity. They are more humble, thankful, resilient, generous, flexible, often joyful with a good sense of humour, stronger in faith, dignity, people relationship and hospitality. I do have a lot to learn from them.

For the past 11 years (2005-2016) I was the Chief Executive of the CEDAR Fund, and now I am a board member, while I am still practising ophthalmology on a part-time basis. CEDAR Fund is a Christian NGO established in HK in 1991. The focus is overseas projects in more than 10 countries in Asia, Africa, and China. There are more than 60 projects. We partner with local organisations and churches which live among the communities. This is more efficient in terms of our resources, and more appropriate in their culture and context. There are 3 levels of engagement in poverty alleviation: relief, development, and justice. However each one needs a deeper reflection of its meaning and implementation.

1. Relief. When a disaster happens and news reports are everywhere, people are moved and ready to donate a lot of material resources. There are good and bad effects. But more commonly, people and organisations will forget these victim communities rather quickly. And also there is uneven distribution of assistance to them. Communities slightly away from the disaster centre do not get the help they need. Life is more difficult for them. CEDAR Fund is familiar with these situations and we often locate such needs through our local partners. And we continue to support them for many years if needed. Another 2 important components in our projects are disaster risk reduction and resilience. These involve a lot of education, creative measures, advocacy, and community development. Many government institutions are not able to reach deeply into communities and families for such purposes.
2. Development. We prefer to use the term transformational development. If development only means economic growth and better living conditions, it does not necessarily promise a better society. We need to be very careful not to impose the value system of wealthy societies. There are many corrupted or unhealthy practices that the world does

not agree. It is possible to lift the communities out of poverty, but it's very easy to damage human relationship by setting the goals and values wrong. We pay a lot of respect to the locals, and it's always a participatory approach. And we have to be intentionally inclusive, especially for the voices and roles of women, children, the disabled, and the marginalised.

3. Justice. "Don't give them fish. Teach them how to fish," is not a simple solution to poverty alleviation. Skilled and non-skilled labour are both suffering from social injustice, power game, and unfair distribution of resources resulting in poverty. Advocacy on justice issues may be for the poor communities, with them, or by them. After years of efforts systems and social values could be improved. But it seems like a never ending struggle. The root cause is not only an unjust system. It is from the human hearts. For thousands of years human beings are asking the same philosophical questions. Each generation seems to be making similar mistakes, then again reflecting on radical and spiritual reasons. Before any significant improvement lasts long, people return to the terrible exploitation and fighting against each other. Worse still, people are using different definitions of justice, and insist on their own. In my humble opinion, a higher level of justice is the one of a Christ-like humility, forgiveness and love. It seems opposite to our familiar ways of power wrestling in achieving our goals. But again and again I have seen life transforming stories not coming from the powerful people, but from the insignificant grassroots who dedicated their lives. I like the term "the power of the powerless" from Václav Havel. It is also very biblical, and subversive.

One of our amazing stories happens in Myanmar. The country is now in the spotlight since Aung San Suu Kyi came to power. Before that the military was in control and there was a long history of internal conflicts with many ethnic army groups. CEDAR Fund has a long presence in the country. One of our close partners is the Fullmoon Children Home. The founder Mr. U Ba Hla gave up his opportunities as a professor or politician. He was a well-known lawyer, but decided that he would take care of the orphans resulted from the mountain wars. He promised God that he would not reject any child who came for help in front of his door. And so the number of children increased from about 20 to more than 300 at this stage. He is old now, but still strong enough to visit the communities in the mountains. His daughter Ni Sat is now leading the ministry. This family dedicated their lives to serve the children.

Aung San Suu Kyi is very impressed by the children. She has been longing for peace and unity in her country, but it's so difficult with the baggage of bitter history. However she can see the love and care among the children from all different ethnic groups. They are united by their Christian faith, even though a lot of healing and forgiveness is not yet completed in their hearts. This is possible because the founder of this children home has gone through his own tough stories. He was blamed and put in prison. He was despised. His

elder daughter and son-in-law were murdered by an army group. Yet he stands firm in love and forgiveness.

Now the first few batches of children have grown up and finished their studies. In 2012 I was among the first few outsiders who went up to a mountain village in Mon State. It used to be a battlefield and even now the government officials and army dare not go up there. We were protected by gunmen. In that visit we were planning for a resettlement project for war refugees who were living in the forests. CEDAR Fund raised some money from HK, and we built some simple houses, farms, a water system, a primary school, a small clinic, and later solar energy and bridges. Although this was mainly a Christian initiative, the Buddhist monks in the village also got the same benefits. Here we respected each other as friends. They even sent their congratulations on our Christmas day! Apart from the hardware setups, more importantly there were a lot of stories telling and healing of their past years of difficulties and pain, and reconciliation.

The Peace Leader of this village area was the first official I met at the mountain. He protected us on the way. In fact he was an army leader but then he decided he should put down his weapons. Later some of the graduates from our children home decided to go up to serve in this village as nurses and teachers. And to my surprise, some of their parents were actually killed by this same army group under the now Peace Leader! They are able to forgive their enemy, and come back to serve the people! One night the Peace Leader asked U Ba Hla, "I don't know where I'll go when I die. I have killed so many people." U Ba Hla comforted and blessed him, "Do what is right for now. God will judge in His kindness."

This resettlement project is still going on and expanding. Other areas are very interested in what we are doing, the truth and reconciliation, which the government is not able to replicate. We have started similar projects in other states in Myanmar.

Restorative justice is different from retributive justice. The aim is to restore relationship among the 3 parties: the offender, the victim, and the community. Similarly the approach of conflict transformation is better than conflict resolution in that it seeks to transform the causal factors of conflict into positive motivation towards real peace, reaching into deeper levels of humanity.

The present world is experiencing a unique era of tension. But creative tension could become a driving force for reflections and innovations. A new order and paradigm shift has begun. And I am excited to explore new areas of integration of spirituality and social issues.

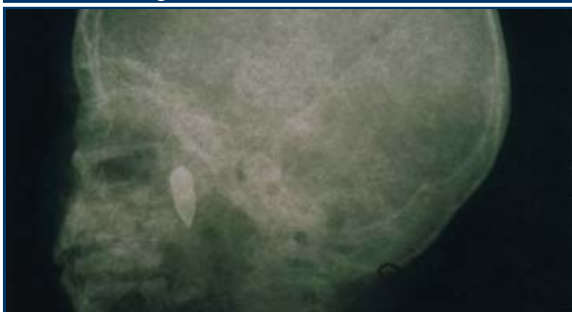

300+ children





All our children go to schools



Bullet in orbit



Fullmoon Children Home, a big compound



I walked with our children to school



Mine explosion injury to eyes and face



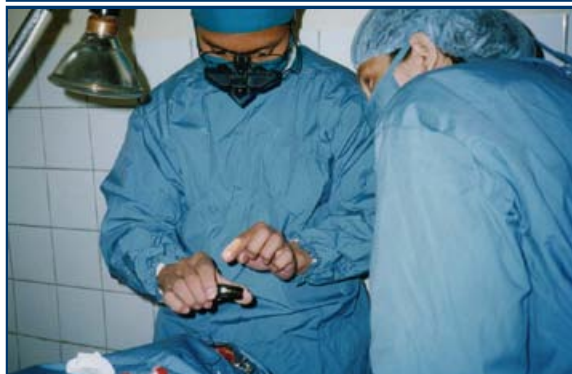New housing in resettlement village, with solar panels



NOOR Eye Institute with sandbags cover



Primary school in resettlement village



Teaching Afghan lady ophthalmologist on retinal detachment repair operation



11 To 13, Aug.2015

CPM Yangon

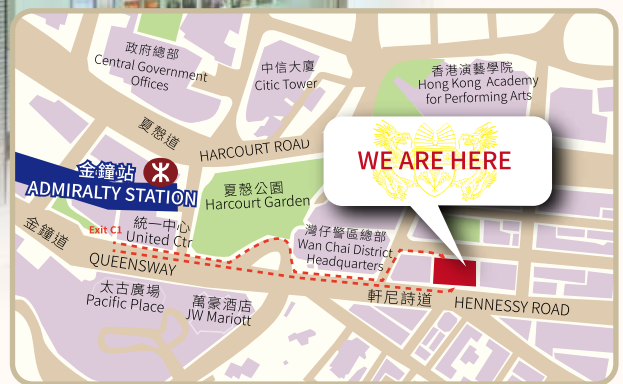Truth & Reconciliation Conference 2015, Myanmar





THE FEDERATION OF MEDICAL SOCIETIES OF HONG KONG

香港醫學組織聯合會



Location: 4/F., Duke of Windsor Social Service Building, 15 Hennessy Road, Wan Chai, Hong Kong

## ROOM RENTAL PROMOTION Book now & get FREE 2 hours

FMSHK Member Societies are offered 2 hours FREE rental exclusively.

(Applicable to societies who haven't used the rental service before)

Suitable for Meeting / Seminar / Press Conference / Personal Gathering

### Well Equipped for Rental:

Sound system : microphones /  
Notebook with LCD projector /  
42" TV / Broadband Internet & wifi /  
Refreshment Ordering, Drinks Ordering /  
Printing & Photocopy Services

Multi Function Room I



Lecture Hall



Council Chamber



For enquiry and booking, please contact the Secretariat at 2527 8898.  
<http://www.fmshk.org/rental>





# AcrySof® IQ PanOptix™ Presbyopia-Correcting IOL



## Designed for more natural adaptability

Featuring ENLIGHTEN™ (ENhanced LIGHT ENergy) Optical Technology to mimic the performance of a healthy crystalline lens, the AcrySof® IQ PanOptix™ IOL is the natural choice for advanced presbyopia correction:

- **Exceptionally high light utilization in a presbyopia-correcting IOL.**  
Transmits 88% of light to help provide crisp quality of vision at all distances.<sup>1</sup>
- **More comfortable near to intermediate range of vision.**  
Provides a more natural intermediate focal point of 60 cm, which is preferred for real-life tasks, such as computer work, over the 80 cm distance offered by other trifocals.<sup>2-4</sup>
- **Less dependence on pupil size.**  
4.5 mm diffractive zone designed for excellent performance in all lighting conditions.<sup>2</sup>

**To learn more about the AcrySof® IQ PanOptix™ Presbyopia-Correcting IOL, talk to your Alcon sales representative.**

1. AcrySof® IQ PanOptix™ IOL Directions for Use. 2. PanOptix™ Diffractive Optical Design. Alcon internal technical report: TDOC-0018723. Effective date 19 Dec 2014. 3. Charness N, Dijkstra K, Jastrzebski T, et al. Monitor viewing distance for younger and older workers. Proceedings of the Human Factors and Ergonomics Society 52nd Annual Meeting, 2008. [http://www.academia.edu/477435/Monitor\\_Viewing\\_Distance\\_for\\_Younger\\_and\\_Older\\_Workers](http://www.academia.edu/477435/Monitor_Viewing_Distance_for_Younger_and_Older_Workers). Accessed April 9, 2015. 4. Average of American OSHA, Canadian OSHA and American Optometric Association Recommendations for Computer Monitor Distances.



Sunday	Monday	Tuesday	Wednesday	Thursday	Friday	Saturday	
				<ul style="list-style-type: none"> <li>★ HKMA Hong Kong East Community Network and Centre for Health Protection of the Department of Health - Antibiotic Stewardship Programme in Primary Care</li> <li>★ HKMA-Kowloon East Community Network - Management of Degenerative Joint Diseases - Local Perspectives for Primary Physicians</li> </ul>	<ul style="list-style-type: none"> <li>★ HKMA-HKS&amp;H CME Programme 2017-2018 - "Update in Medical Practice" Topic: Management of Ischaemic Heart Disease</li> <li>★ HKMA-New Territories West Community Network - How to Optimize Diabetic Treatment in Elderly Patients</li> </ul>	<ul style="list-style-type: none"> <li>★ HKMA Kowloon City Community Network and Primary Care Office of the Department of Health - Assessment and Management of Older Adults' Cognitive Impairment in Primary Care Setting</li> </ul>	<ul style="list-style-type: none"> <li>★ Refresher Course for Health Care Providers 2017/2018</li> </ul>
4	5	6	7	8	9	10	
		<ul style="list-style-type: none"> <li>★ HKMA Yau Tsim Mong Community Network and Centre for Health Protection of the Department of Health - Antibiotic Stewardship Programme in Primary Care</li> <li>★ HKMA Tai Po Community Network - Avonafil - A New Generation of PDE5 Inhibitors</li> <li>★ FMSHK Officers' Meeting</li> <li>★ HKMA Council Meeting</li> </ul>	<ul style="list-style-type: none"> <li>★ HKMA Central, Western &amp; Southern Community Network - An Update on AF Management and Screening</li> </ul>	<ul style="list-style-type: none"> <li>★ HKMA Hong Kong East Community Network - Prescription of Insulin Therapy in a Primary Clinic</li> <li>★ HKMA Kowloon East Community Network - Update on Long-Term Management of Postmenopausal Osteoporosis</li> </ul>	<ul style="list-style-type: none"> <li>★ HKMA Shatin Doctors Network - Diagnosis and Management of Attention Deficit/Hyperactivity Disorder (ADHD) in Children</li> <li>★ HKMA Yau Tsim Mong Community Network - Benefits of SGLT2 Inhibitors in Asians</li> </ul>	<ul style="list-style-type: none"> <li>★ MPS Workshop - Achieving Safer and Reliable Practice</li> </ul>	
11	12	13	14	15	16	17	
		<ul style="list-style-type: none"> <li>★ HKMA-Kowloon West Community Network - Diagnosis and Management of Attention Deficit Hyperactivity Disorder (ADHD) in Children</li> </ul>	<ul style="list-style-type: none"> <li>★ HKMA-Central, Western &amp; Southern Community Network - Update in the Management of Idiopathic Pulmonary Fibrosis</li> <li>★ MPS Workshop - Mastering Professional Interactions</li> <li>★ Hong Kong Neurosurgical Society Monthly Academic Meeting - To be confirmed</li> </ul>	<ul style="list-style-type: none"> <li>★ MPS Workshop - Achieving Safer and Reliable Practice</li> <li>★ FMSHK Executive Committee Meeting</li> </ul>	<ul style="list-style-type: none"> <li>★ MPS Workshop - Achieving Safer and Reliable Practice</li> </ul>	<ul style="list-style-type: none"> <li>★ MPS Workshop - Achieving Safer and Reliable Practice</li> </ul>	
18	19	20	21	22	23	24	
		<ul style="list-style-type: none"> <li>★ HKMA-Tai Po Community Network - Updates in Mild Cognitive Impairment and Dementia Assessment for Busy Clinicians</li> </ul>	<ul style="list-style-type: none"> <li>★ MPS Workshop - Mastering Your Risk</li> </ul>				
25	26	27	28	29	30	31	
<ul style="list-style-type: none"> <li>★ HKMA Football Day</li> </ul>		<ul style="list-style-type: none"> <li>★ HKMA-Kowloon West Community Network - Hypertension 2018</li> </ul>					





Date / Time	Function	Enquiry / Remarks
<b>1 THU</b>	1:00 PM <b>HKMA Hong Kong East Community Network and Centre for Health Protection of the Department of Health - Antibiotic Stewardship Programme in Primary Care</b> Organiser: HKMA Hong Kong East Community Network; DH-Centre for Health Protection; Chairman: Dr. LEUNG Kwan Kui, Terence; Speaker: Dr. LAM Tin Keung, Edman; Venue: HKMA Wanchai Premises, 5/F, Duke of Windsor Social Service Building, 15 Hennessy Road, HK	Ms. Candice TONG Tel: 2527 8285 1 CME Point
	1:00 PM <b>HKMA-Kowloon East Community Network - Management of Degenerative Joint Diseases - Local Perspectives for Primary Physicians</b> Organiser: HKMA Kowloon East Community Network; Chairman: Dr. AU Ka Kui, Gary; Speaker: Dr. Ho Hon Shuen; Venue: Lei Garden Restaurant, Shop No. L5-8, apm, Kwun Tong, No. 418 Kwun Tong Road, Kowloon	Mr. Ian YAU Tel: 2527 8285 1 CME Point
<b>6 TUE</b>	1:00 PM <b>HKMA Yau Tsim Mong Community Network and Centre for Health Protection of the Department of Health - Antibiotic Stewardship Programme in Primary Care</b> Organiser: HKMAYau Tsim Mong Community Network; DH-Centre for Health Protection; Chairman: Dr. HO Fung; Speaker: Dr. LAM Tin Keung, Edman; Venue: Crystal Ballroom, 2/F, The Cityview Hong Kong, 23 Waterloo Road, Kowloon	Ms. Candice TONG Tel: 2527 8285 1 CME Point
	1:45 PM <b>HKMA Tai Po Community Network - Avanaflin - A New Generation of PDE5 Inhibitors</b> Organiser: HKMA Tai Po Community Network; Chairman: Dr. CHOW Chun Kwan, John; Speaker: Dr. CHAN Lung Wai; Venue: Chiuchow Garden Restaurant, Shop 001-003, 1/F, Uptown Plaza, No. 9 Nam Wan Road, Tai Po	Ms. Candice TONG Tel: 2527 8285 1 CME Point
	8:00 PM <b>FMSHK Officers' Meeting</b> Organiser: The Federation of Medical Societies of Hong Kong; Venue: Gallop, 2/F, Hong Kong Jockey Club Club House, Shan Kwong Road, Happy Valley, Hong Kong	Ms. Nancy CHAN Tel: 2527 8898
	9:00 PM <b>HKMA Council Meeting</b> Organiser: The Hong Kong Medical Association; Chairman: Dr. CHOI Kin; Venue: HKMA Wanchai Premises, 5/F, Duke of Windsor Social Service Building, 15 Hennessy Road, HK	Ms. Christine WONG Tel: 2527 8285
<b>7 WED</b>	1:00 PM <b>HKMA Central, Western &amp; Southern Community Network - An Update on AF Management and Screening</b> Organiser: HKMA Central, Western & Southern Community Network; HK College of Cardiology; Chairman: Dr. YIK Ping Yin; Speaker: Dr. CHAN Pak Hei, Michael; Venue: Dr. Li Shu Pui Professional Education Centre, 2/F, Chinese Club Building, 21-22 Connaught Road Central	Mr. Ian YAU Tel: 2527 8285 1 CME Point
<b>8 THU</b>	1:00 PM <b>HKMA-HKS&amp;H CME Programme 2017-2018 –“Update in Medical Practice” Topic: Management of Ischaemic Heart Disease</b> Organiser: The Hong Kong Medical Association & Hong Kong Sanatorium & Hospital; Speaker: Dr. Raymond H.W.CHAN; Venue: Dr. Li Shu Pui Professional Education Centre, 2/F, Chinese Club Building, 21-22 Connaught Road Central	HKMA CME Dept. Tel: 2527 8285 1 CME Point
	1:00 PM <b>HKMA-New Territories West Community Network - How to Optimize Diabetic Treatment in Elderly Patients</b> Organiser: HKMA-New Territories West Community Network; Chairman: Dr. CHEUNG Kwok Wai, Alvin; Speaker: Dr. Tong Chun Yip, Peter; Venue: Pak Loh Chiu Chow Restaurant, Shop A316, 3/F, Yoho Mall II, 8 Long Yat Road, Yuen Long	Mr. Ian YAU Tel: 2527 8285 1 CME Point
<b>10 SAT</b>	2:15 PM <b>Refresher Course for Health Care Providers 2017/2018</b> Organiser: Hong Kong Medical Association; HK College of Family Physicians; HA-Our Lady of Maryknoll Hospital; Speaker: Dr. IP Fong Cheng, Francis; Venue: Training Room II, 1/F, OPD Block, Our Lady of Maryknoll Hospital, 118 Shatin Pass Road, Wong Tai Sin	Ms. Clara TSANG Tel: 2354 2440 2 CME Point
<b>13 TUE</b>	1:00 PM <b>HKMA-Kowloon West Community Network - Diagnosis and Management of Attention Deficit Hyperactivity Disorder (ADHD) in Children</b> Organiser: HKMA-Kowloon West Community Network; Chairman: Dr. TONG Kai Sing; Speaker: Dr. Wong Juen Sing, Mark; Venue: Fulum Palace, Shop C, G/F, 85 Broadway Street, Mei Foo Shun Chuen, Mei Foo	Mr. Ian YAU Tel: 2527 8285 1 CME Point
<b>14 WED</b>	1:00 PM <b>HKMA-Central, Western &amp; Southern Community Network - Update in the Management of Idiopathic Pulmonary Fibrosis</b> Organiser: HKMA-Central, Western & Southern Community Network; Chairman: Dr. YIK Ping Yin; Speaker: Dr. Wan Chi Kin, Raymond; Venue: HKMA Central Premises, Dr. Li Shu Pui Professional Education Centre, 2/F, Chinese Club Building, 21-22 Connaught Road Central	HKMA CME Dept. Tel: 2527 8285 2.5 CME Point
	6:30 PM <b>MPS Workshop – Mastering Professional Interactions</b> Organiser: The Hong Kong Medical Association & Medical Protection Society; Chairman: Dr. CHOI Kin; Speaker: Dr. Lee Wai Hung, Danny; Venue: Dr. Li Shu Pui Professional Education Centre, 2/F, Chinese Club Building, 21-22 Connaught Road Central	Mr. Ian YAU Tel: 2527 8285 1 CME Point
	7:30 PM <b>Hong Kong Neurosurgical Society Monthly Academic Meeting –To be confirmed</b> Organiser: Hong Kong Neurosurgical Society; Chairman: Dr CHIU Hok Ming; Speaker: Dr NG Chat Fong; Venue: Seminar room, G/F, Block A, Queen Elizabeth Hospital	1.5 points College of Surgeons of Hong Kong Dr. LEE Wing Yan, Michael Tel: 2595 6456 Fax. No.: 2965 4061
<b>15 THU</b>	1:00 PM <b>HKMA Hong Kong East Community Network - Prescription of Insulin Therapy in a Primary Clinic</b> Organiser: HKMA Hong Kong East Community Network; Chairman: Dr. WONG Chun Por; Speaker: Dr. TSO Wai Kwan, Annette; Venue: HKMA Wanchai Premises, 5/F, Duke of Windsor Social Service Building, 15 Hennessy Road, HK	Ms. Candice TONG Tel: 2527 8285 1 CME Point
	1:00 PM <b>HKMA Kowloon East Community Network - Update on Long-Term Management of Postmenopausal Osteoporosis</b> Organiser: HKMA Kowloon East Community Network; Chairman: Dr. AU Ka Kui, Gary; Speaker: Dr. Tsang Wai Yin, Kevin; Venue: V Cuisine, 6/F, Holiday Inn Express Hong Kong Kowloon East, 3 Tong Tak Street, Tseung Kwan O	Mr. Ian YAU Tel: 2527 8285 1 CME Point
<b>16 FRI</b>	1:00 PM <b>HKMA Kowloon City Community Network and Primary Care Office of the Department of Health - Assessment and Management of Older Adults' Cognitive Impairment in Primary Care Setting</b> Organiser: HKMA Kowloon City Community Network; DH-Primary Care Office; Chairman: Dr. CHIN Chu Wah; Speaker: Dr. LUK Kam Hung; Venue: President's Room, Spotlight Recreation Club, 4/F, Screen World, Whampoa Garden, Hung Hom	Ms. Candice TONG Tel: 2527 8285 1 CME Point



Date / Time	Function	Enquiry / Remarks
<b>20 TUE</b> 1:00 PM	<b>HKMA-Tai Po Community Network - Updates in Mild Cognitive Impairment and Dementia Assessment for Busy Clinicians</b> Organiser: HKMA-Tai Po Community Network; Chairman: Dr. CHOW Chun Kwan, John; Speaker: Prof. Adrian WONG; Venue: Chiu Chow Garden Restaurant, Shop 001-003, 1/F, Uptown Plaza, No. 9 Nam Wan Road, Tai Po	Ms. Candice TONG Tel: 2527 8285 1 CME Point
<b>21 WED</b> 6:30 PM	<b>MPS Workshop – Mastering Your Risk</b> Organiser: The Hong Kong Medical Association & Medical Protection Society; Chairman: Dr. CHOI Kin; Speaker: Dr. Lee Wai Hung, Danny; Venue: Dr. Li Shu Pui Professional Education Centre, 2/F, Chinese Club Building, 21-22 Connaught Road Central	HKMA CME Dept. Tel: 2527 8285 2.5 CME Point
<b>22 THU</b> 6:30 PM 8:00 PM	<b>MPS Workshop – Achieving Safer and Reliable Practice</b> Organiser: The Hong Kong Medical Association & Medical Protection Society; Chairman: Dr. CHOI Kin; Speaker: Dr. Cheng Ngai Shing, Justin; Venue: Crystal Ballroom, 2/F, The Cityview Hong Kong, 23 Waterloo Road, Kowloon <b>FMSHK Executive Committee Meeting</b> Organiser: The Federation of Medical Societies of Hong Kong; Venue: Council Chamber, 4/F, Duke of Windsor Social Service Building, 15 Hennessy Road, Wanchai, Hong Kong	HKMA CME Dept. Tel: 2527 8285 2.5 CME Point  Ms. Nancy CHAN Tel: 2527 8898
<b>23 FRI</b> 1:00 PM 1:00 PM	<b>HKMA Shatin Doctors Network - Diagnosis and Management of Attention Deficit Hyperactivity Disorder (ADHD) in Children</b> Organiser: HKMA Shatin Doctors Network; Chairman: Dr. MAK Wing Kin; Speaker: Dr. LEE Ming Chung, Marshall; Venue: Royal Park Chinese Restaurant, Level 1, Royal Park Hotel, 8 Pak Hok Ting Street, Shatin <b>HKMA Yau Tsim Mong Community Network - Benefits of SGLT2 Inhibitors in Asians</b> Organiser: HKMA Yau Tsim Mong Community Network; Chairman: Dr. CHENG Kai Chi, Thomas; Speaker: Dr. TONG Chun Yip, Peter; Venue: Crystal Ballroom, 2/F, The Cityview Hong Kong, 23 Waterloo Road, Kowloon	Ms. Candice TONG Tel: 2527 8285 1 CME Point  Ms. Candice TONG Tel: 2527 8285 1 CME Point
<b>24 SAT</b> 2:30 PM	<b>MPS Workshop – Achieving Safer and Reliable Practice</b> Organiser: The Hong Kong Medical Association & Medical Protection Society; Chairman: Dr. CHOI Kin; Speaker: Dr. Cheng Ngai Shing, Justin; Venue: Harbour Plaza Resort City, Tin Shui Wai	HKMA CME Dept. Tel: 2527 8285 2.5 CME Point
<b>25 SUN</b> 12:00 PM	<b>HKMA Football Day</b> Organiser: The Hong Kong Medical Association; Chairman: Dr. CHAN Chi Wing, Timmy; Dr. CHAN Hau Ngai, Kingsley; Venue: Stanley Ho Sports Centre	Miss Kayin LEE/ Miss Sinn TANG Tel: 2527 8285
<b>27 TUE</b> 1:00 PM	<b>HKMA-Kowloon West Community Network - Hypertension 2018</b> Organiser: HKMA-Kowloon West Community Network; Chairman: Dr. TONG Kai Sing; Speaker: Dr. Wong Wing Kwong, Raymond; Venue: Fulum Palace, Shop C, G/F, 85 Broadway Street, Mei Foo Sun Chuen, Mei Foo	Mr. Ian YAU Tel: 2527 8285 1 CME Point



## Dermatological Quiz

## Dermatological Quiz

## Dr Chi-keung KWAN

MBBS(HK), MRCP(UK), Dip Derm(Glasgow), PDipID (HK),  
MFM (Monash) FHKCP, FHKAM(Medicine)

Specialist in Dermatology & Venereology



Dr Chi-keung KWAN




Fig. 1: bilateral lower limbs of the patient

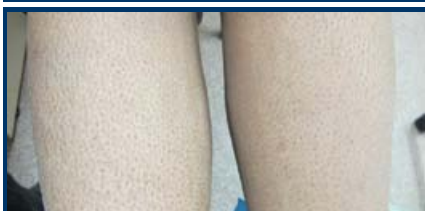

Fig. 2: close-up of patient's right shin

This 24-year-old man complained of general skin itchiness since childhood which was precipitated in winter and low humidity. His father and elderly brother have a similar problem. Physical examination revealed nothing abnormal except dryness of the skin especially on the limbs (Fig. 1). A closer look of the lower limbs revealed some "brown" and "scales" appearance on the extensor aspect of the shins (Fig. 2). He also had some eczema over the waist and keratosis pilaris over the upper arms.

## Questions

1. What is the diagnosis of the skin lesion?
2. What is the underlying pathology?
3. How do you manage this gentleman?

(See P.41 for answers)



## Answers to Dermatological Quiz

### Answer:

- 1. Ichthyosis Vulgaris**  
 The diagnosis is ichthyosis vulgaris and can often be reached from its characteristic clinical features. Ichthyosis is from the Greek word meaning fish and vulgaris means common. Ichthyosis vulgaris often called as "fish scale disease" or "fish skin disease". Dry (xerotic) and scaly skin on the extensor surface of the limbs and central face is the characteristic sign. It is associated with keratosis pilaris and atopic dermatitis.
- 2. Ichthyosis vulgaris results from mutation in the gene encoding the functional protein filaggrin and causes a decrease in the production of filaggrin. Filaggrin is an effective skin barrier to retaining skin moisture in the stratum corneum. Thereby, ichthyosis vulgaris cannot maintain the skin moisture and increases the trans-epidermal water loss. It is autosomal dominant. However, if mutation happens in one gene of the paired chromosome, it results in a milder form whereas if mutation occurs in both genes, it results in moderate to severe xerosis.**
- 3. There is no definite treatment for ichthyosis vulgaris. The management is mainly conservative. The aim is to reduce the dryness, scaling and thickening of the skin. Frequently applying skin emollient to maintain skin moisture is the key measure. Sometimes occlusive methods after applying the moisturiser can enhance skin hydration. The cream or lotion containing salicylic acid, glycolic acid, lactic acid and urea may be used to exfoliate the scaling or thick skin. Oral retinoid can be tried in severe cases.**

### Dr Chi-keung KWAN

MBBS(HK), MRCP(UK), Dip Derm(Glasgow), PDipID (HK), MFM (Monash) FHKCP, FHKAM(Medicine)  
*Specialist in Dermatology and Venereology*

**The Federation of Medical Societies of Hong Kong**  
 4/F Duke of Windsor Social Service Building, 15 Hennessy Road, Wanchai, HK  
 Tel: 2527 8898 Fax: 2865 0345

<b>President</b>	Dr Mario Wai-kwong CHAK	翟偉光醫生
<b>1st Vice-President</b>	Prof Bernard Man-yung CHEUNG	張文勇教授
<b>2nd Vice-President</b>	Dr Chun-kong NG	吳振江醫生
<b>Hon. Treasurer</b>	Mr Benjamin Cheung-mei LEE	李祥美先生
<b>Hon. Secretary</b>	Dr Ludwig Chun-hing TSOI	蔡振興醫生
<b>Immediate Past President</b>	Dr Raymond See-kit LO	勞思傑醫生
<b>Executive Committee Members</b>	Dr Jane Chun-kwong CHAN Dr Kingsley Hau-ngai CHAN Dr Kai-ming CHAN Dr Alson Wai-ming CHAN Dr Samuel Ka-shun FUNG Ms Ellen Wai-yin KU Dr Chun-on MOK Dr Desmond Gia-hung NGUYEN Dr Kwai-ming SIU Dr Thomas Man-kit SO Dr Tony Ngan-fat TO Ms Tina WT YAP Dr Victor Hip-wo YEUNG Dr Edwin Chau-leung YU	陳真光醫生 陳厚毅醫生 陳啟明醫生 陳偉明醫生 馮加信醫生 顧慧賢小姐 莫鎮安醫生 阮家興醫生 邵貴明醫生 蘇文傑醫生 杜銀發醫生 葉婉婷女士 楊協和醫生 余秋良醫生

#### Founder Members

**British Medical Association (Hong Kong Branch)**  
 英國醫學會 (香港分會)

<b>President</b>	Dr Raymond See-kit LO	勞思傑醫生
<b>Vice-President</b>	Dr Adrian WU	鄺揚源醫生
<b>Hon. Secretary</b>	Dr Terry Che-wai HUNG	洪致偉醫生
<b>Hon. Treasurer</b>	Dr Jason BROCKWELL	
<b>Council Representatives</b>	Dr Raymond See-kit LO Dr Tse-ming CHEUNG Tel: 2527 8898 Fax: 2865 0345	勞思傑醫生 張子明醫生

#### The Hong Kong Medical Association 香港醫學會

<b>President</b>	Dr. Kin CHOI	蔡堅醫生
<b>Vice- Presidents</b>	Dr Alvin Yee-shing CHAN Dr Chung-ping HO, MH, JP	陳以誠醫生 何仲平醫生, MH, JP
<b>Hon. Secretary</b>	Dr David Tzit-yuen LAM	林哲玄醫生
<b>Hon. Treasurer</b>	Dr Chi-chiu LEUNG	梁子超醫生
<b>Council Representatives</b>	Dr Alvin Yee-shing CHAN	陳以誠醫生
<b>Chief Executive</b>	Ms Jovi LAM Tel: 2527 8285 (General Office) 2527 8324 / 2536 9388 (Club House in Wanchai / Central) Fax: 2865 0943 (Wanchai), 2536 9398 (Central) Email: hkma@hkma.org Website: http://www.hkma.org	林偉珊女士

#### The HKFMS Foundation Limited 香港醫學組織聯會基金

<b>Board of Directors</b>		
<b>President</b>	Dr Mario Wai-kwong CHAK	翟偉光醫生
<b>1st Vice-President</b>	Prof Bernard Man-yung CHEUNG	張文勇教授
<b>2nd Vice-President</b>	Dr Chun-kong NG	吳振江醫生
<b>Hon. Treasurer</b>	Mr Benjamin Cheung-mei LEE	李祥美先生
<b>Hon. Secretary</b>	Dr Ludwig Chun-hing TSOI	蔡振興醫生
<b>Directors</b>	Mr Samuel Yan-chi CHAN Dr Samuel Ka-shun FUNG Ms Ellen Wai-yin KU Dr Raymond See-kit LO Dr Aaron Chak-man YU	陳恩賜先生 馮加信醫生 顧慧賢女士 勞思傑醫生 余則文醫生

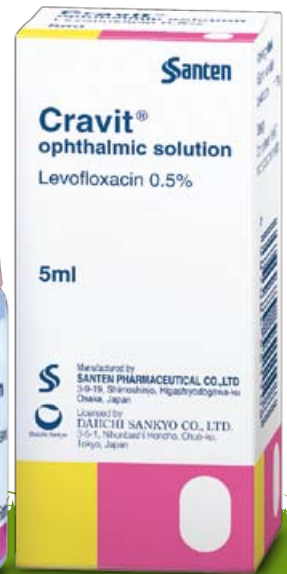



# Broad spectrum potent antibacterials Cravit® ophthalmic solution

Levofloxacin 0.5%

- Efficacy & Safety<sup>1,2</sup>
- High Ocular Penetration<sup>3</sup>
- Preservative Free



#### [Composition]

Cravit ophthalmic solution is a pale to light yellow, clear sterile aqueous solution. Each mL contains 5 mg of levofloxacin. Its pH is 6.2-6.8 and its osmotic pressure ratio is 1.0-1.1.

#### [Indications]

<Indicated bacteria>

Susceptible strains of Staphylococcus sp., Streptococcus sp., Streptococcus pneumoniae, Enterococcus sp., Micrococcus sp., Moraxella sp., Corynebacterium sp., Klebsiella sp., Enterobacter sp., Serratia sp., Proteus sp., Morganella morganii, Haemophilus influenzae, Haemophilus aegyptius [Koch-Weeks bacillus], Pseudomonas sp., Pseudomonas aeruginosa, Stenotrophomonas (Xanthomonas) maltophilia, Acinetobacter sp., and Propionibacterium acnes.

<Indications>

Blepharitis, dacryocystitis, hordeolum, conjunctivitis, tarsadenitis, keratitis (including corneal ulcer), and aseptic treatment during a perioperative period for ocular surgery.

#### [Dosage and Administration]

Usually, instill 1 drop a time 3 times daily. The dosage may be adjusted according to the patient's symptoms.

#### [Contraindications]

(Cravit ophthalmic solution is contraindicated in the following patients.)

Patients with a history of hypersensitivity to the ingredient of this product, ofloxacin or any quinolone antibiotics.

#### [Precautions]

1. In order to avoid the emergence of resistant bacteria, bacterial susceptibility should be confirmed and treatment with this drug should be limited to the minimum period required for the eradication of the infection.
2. The efficacy of this product to methicillin-resistant Staphylococcus aureus (MRSA) has not been proved. Therefore, other drug having a potent anti-MRSA activity should be administered immediately to patients positively infected with MRSA and not showing any improvement of symptoms with this product.

(Full prescribing information shall be available upon request)

#### Reference:

1. Masahiko Usui. Clinical Evaluation of Levofloxacin Ophthalmic Solution – A Multicenter Phase III Double-masked Clinical Trial. J. Eye. 1997, 14(4): 641-648.
2. Masahiko Usui. Clinical Evaluation of Levofloxacin Ophthalmic Solution – A Multicenter Phase III Open Label Trial. J. Eye. 1997, 14(7): 1113-1118
3. Fukuda M, et al. General purpose antimicrobial ophthalmic solutions evaluated using new pharmacokinetic parameter of maximum drug concentration in aqueous. Jpn J Ophthalmol. 2002 Jul-Aug;46(4):384-90.

For Healthcare Professionals Only

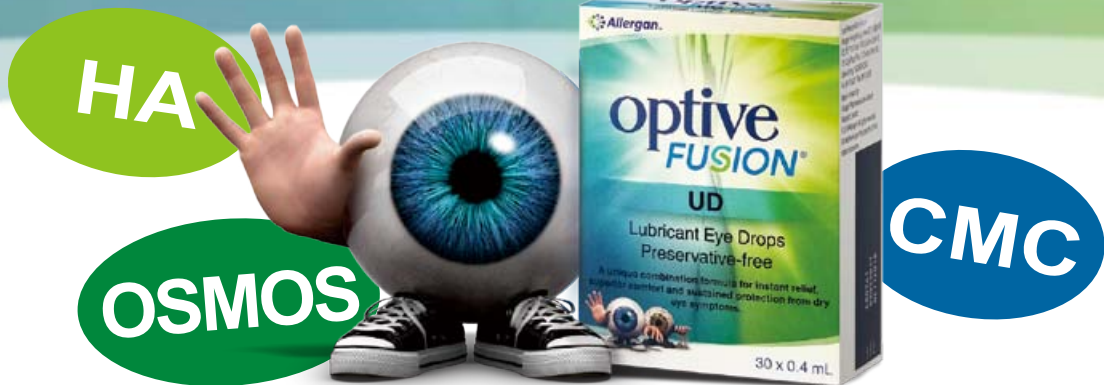


Santen Pharmaceutical (Hong Kong) Limited

Unit 1607, 16/F, Concordia Plaza 1 Science Museum Road, TST East, Kowloon, Hong Kong  
Phone +852 2565 6660 Fax +852 2565 6068

# OPTIVE FUSION™ – Are you ready to recommend the Power of 3?

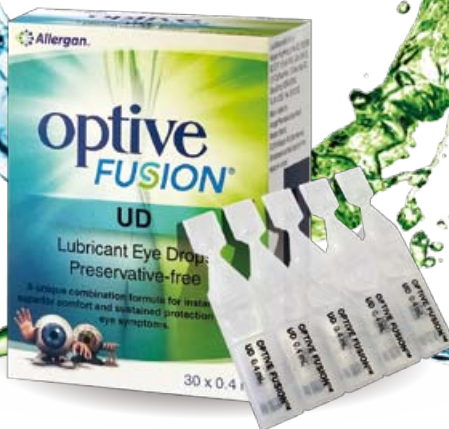OPTIVE FUSION is the only dry eye formulation that contains HA + CMC + osmoprotectants, which work together to maintain a comfortable, healthy tear film, and enable your patients to break free from the vicious cycle of DED<sup>4-6</sup>



Carboxymethylcellulose  
(CMC)

+

Hyaluronic acid  
(HA)



- Optive Fusion™ is different
- It uses an advanced formulation<sup>1</sup> for effective relief<sup>2,3</sup>
- For a comfortable blink without the blur for most people...<sup>2</sup>
- And relief of blurred vision, pain and that sandy, gritty feeling<sup>2</sup>

References: 1. Simmons P et al. TFOS Conference 2013. 2. Simmons P et al. Clin Ophthalmol 2015; 9: 665-675. 3. Chen W et al. International Society for Eye Research 2014. 4. Allergan OPTIVE FUSION™ MD Labelling 2016. 5. Baudouin C et al. Ocul Surf. 2013; 11: 246-248. 6. IMS Health (53 countries). Last accessed: July 2016.